



PATIENT

Sidney Khan

SPECIES

Canine

BREED

Beagle

SEX

Female

AGE

6 years 3 months

WEIGHT

28.8 lbs

INTERPRETED BY

Beth Johnson, DVM
DACVIM

IMAGING PERFORMED BY

Vincent Ravancho,
CVT

HOSPITAL NAME

Animal Clinic and
Hospital of Jersey City

REFERRING VET

Dr. Robe

INVOICE

11988

DATE

5/21/2026

PRESENTING CLINICAL SIGNS

Hyporexia, Emesis, hematochezia r/o pancreatitis vs gastroenteritis vs hepatobiliary dz vs IBD vs FB vs other.

Abnormal PE/Chem/CBC/UA Results: Creatinine 1.6 all else WNL.

ULTRASONOGRAPHIC EXAMINATION OF THE ABDOMEN

Urinary System

The urinary bladder is adequately distended with anechoic contents. No masses, inflammatory changes, echogenic sediment or cystoliths are observed. The urinary bladder, trigone and visible pelvic urethra are normal in thickness with a smooth mucosal surface.

The right kidney is normal is size (4.83 cm), shape and echogenicity. It has smooth peripheral margination. There is a normal 1:3 cortex to medulla ratio with appropriate corticomedullary distinction. A hyperechoic band parallel to the corticomedullary border is present. There is no evidence of pyelectasia, mineral or infarcts observed.

The left kidney is normal is size (4.45 cm), shape and echogenicity. It has smooth peripheral margination. There is a normal 1:3 cortex to medulla ratio with appropriate corticomedullary distinction. A hyperechoic band parallel to the corticomedullary border is present. There is no evidence of pyelectasia, mineral or infarcts observed.

Adrenal Glands

Adrenal glands are small (flattened contour). Corticomedullary structure is unremarkable. Visible surrounding vasculature appears normal. Left adrenal gland measures 0.39 cm at cranial pole and 0.38 cm at caudal pole. Right adrenal gland measures 0.68 cm at cranial pole and 0.48 cm at caudal pole.

Spleen

The spleen is subjectively normal in size with a normal smooth capsular contour. Parenchyma is appropriately finely textured and homogenous with normal echogenicity relative to surrounding tissue (hyperechoic to liver). No focal nodules or masses are observed. Splenic vasculature appears normal.

Liver

The liver is subjectively normal in size with normal smooth curvilinear peripheral contour. Parenchyma is appropriately hypoechoic to the spleen in echogenicity and appropriately mildly coarse and homogenous in echotexture. No focal lesions are observed. Visible vasculature and biliary tree appear normal without distension or congestion.

The gallbladder is non-distended in size. The wall is smooth without visible thickening. Luminal contents are primarily anechoic. There is no evidence of cystic or common bile duct dilation.

Gastrointestinal

The visible stomach wall is normal in thickness and layering. The lumen of the stomach is empty with no evidence of obstruction, foreign material or infiltrative disease. Pyloric outflow tract appears patent.



PATIENT

Sidney Khan

The visible small intestines are normal in wall thickness and layering. Small intestinal motility appears adequate (1-3 contractions per min). The lumen of the small intestine is empty with no evidence of obstruction, foreign material or infiltrative disease.

SPECIES

Canine

The visible colon is normal in wall thickness (< 0.2 cm) and layering. Contents are consistent with normal formed feces and gas.

Pancreas

BREED

Beagle

The pancreas that is observed appears appropriately isoechoic to surrounding omental fat. Visible capsule is smooth and normal in contour. Visible pancreatic parenchyma is homogenous and unremarkable. There is no visible pancreatic duct dilation. There is no evidence of active peripancreatic inflammation.

SEX

Female

Free Abdomen

AGE

6 years 3 months

There is no visible free peritoneal effusion noted in these images.

There is no apparent pathologic lymphadenopathy noted in these images.

ULTRASONOGRAPHIC FINDINGS

WEIGHT

28.8 lbs

- Flat adrenal glands – This can be a normal patient variant and/or a sign of exogenous cortisol administration. If exogenous steroids are not being administered, hypoadrenocorticism (either relative or absolute) should be considered.
- Bilateral medullary rim sign - This finding is of unknown clinical significance and can be a normal variant, often idiopathic. Medullary rim sign can be present with renal disease including lymphoma, hypercalcemic nephropathy, Leptospirosis, tubular disease, other and should be interpreted in combination with other more specific indications of kidney disease such as isosthenuria, proteinuria, azotemia, etc. This is a common incidental finding in patients with diabetes mellitus.

INTERPRETED BY

Beth Johnson, DVM
DACVIM

INTERPRETATION OF THE FINDINGS & FURTHER RECOMMENDATIONS

Urinalysis and, if indicated based on urinalysis results, urine culture is recommended. If protein is present in an otherwise quiet sediment, protein quantification with a urine protein to creatinine ration is recommended.

IMAGING PERFORMED BY

Vincent Ravancho,
CVT

A baseline cortisol is recommended. If baseline cortisol is less than 2, a full ACTH stimulation test is recommended to rule out hypoadrenocorticism.

HOSPITAL NAME

Animal Clinic and
Hospital of Jersey City

Pending results of above, a routine fecal/giardia exam is recommended if not recently evaluated.

REFERRING VET

Dr. Robe

A gastrointestinal malabsorption panel (including cobalamin, folate, TLI and PLI) to Texas A&M GI Laboratory is recommended for further evaluation of GI and pancreatic function.

INVOICE

11988

A fecal enteropathogen PCR panel to Texas A&M GI Laboratory could be considered for further evaluation of possible infectious disease. Contact lab for recommendations on how long to discontinue antibiotics (if indicated) prior to obtaining a stool sample for submission.

DATE

5/21/2026

In the meantime:



PATIENT

Sidney Khan

SPECIES

Canine

BREED

Beagle

SEX

Female

AGE

6 years 3 months

WEIGHT

28.8 lbs

INTERPRETED BY

Beth Johnson, DVM
 DACVIM

IMAGING PERFORMED BY

Vincent Ravancho, CVT

HOSPITAL NAME

Animal Clinic and
 Hospital of Jersey City

REFERRING VET

Dr. Robe

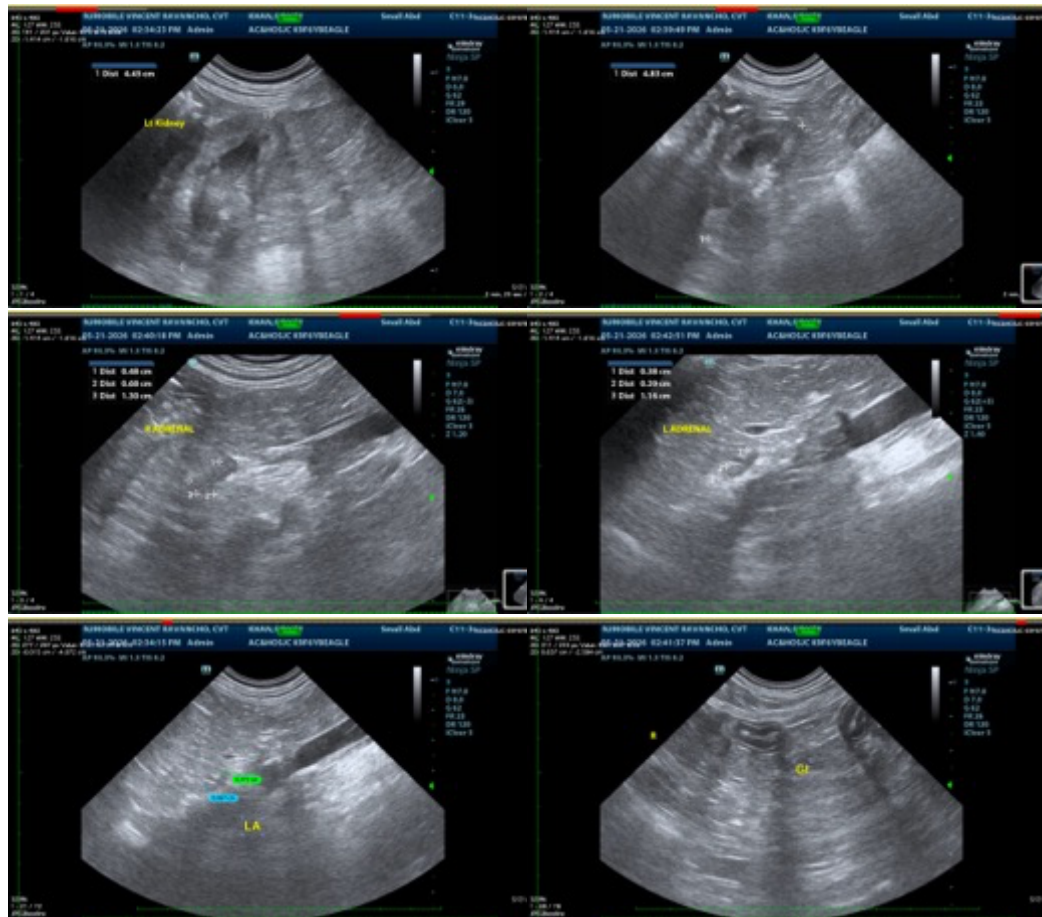
INVOICE

11988

DATE

5/21/2026

- Supportive/symptomatic medical management of clinical signs is recommended, including anti-emetics, gastroprotectants (+/- sucralfate, especially with any history of hematemesis), an appetite stimulant and fluid therapy if indicated, etc.
- Additionally, empirical deworming with a 5-day course of Panacur is recommended.
- A full course of empirical Helicobacter triple therapy could be considered.
- A probiotic, such as visbiome or proviable, may be helpful.
- Finally, if tolerated, a transition in diet could be considered, based on trial-and-error response with some options to consider including a gastrointestinal biome diet vs a hydrolyzed protein diet (sometimes several trials with different brands are necessary) vs an easy to digest, bland or low-fat diet vs other.



The information and recommendations provided are based on the images presented by the referring veterinarian/sonographer. No evaluation can be communicated regarding pathology that was not visible in the image/video clips provided.

Thank you for this referral. If the clinical or image interpretation does not parallel your findings or if I can be of any further assistance please contact me.



PATIENT

Beth Johnson, DVM, DACVIM
info@sonopath.com

Sidney Khan

SPECIES

Canine

BREED

Beagle

SEX

Female

AGE

6 years 3 months

WEIGHT

28.8 lbs

INTERPRETED BY

Beth Johnson, DVM
DACVIM

**IMAGING
PERFORMED BY**

Vincent Ravancho,
CVT

HOSPITAL NAME

Animal Clinic and
Hospital of Jersey City

REFERRING VET

Dr. Robe

INVOICE

11988

DATE

5/21/2026