



PATIENT

Jocko Murray

SPECIES

Feline

BREED

Domestic Shorthair

SEX

Neutered Male

AGE

1 Year

WEIGHT

10.3

INTERPRETED BY

Beth Johnson, DVM
DACVIM

IMAGING PERFORMED BY

Peter Langer, DVM

HOSPITAL NAME

North Hampton Animal
Hospital

REFERRING VET

Craig Kelleher, DVM

INVOICE

75288

DATE

5/20/26

PRESENTING CLINICAL SIGNS

Persistent vomiting and diarrhea since 5/16/26. No significant improvement with pro-pectalin paste, Pepcid, or Cerenia. No known dietary indiscretion/FB ingestion but O cannot entirely rule out that possibility.

Abnormal PE/Chem/CBC/UA Results: Labs and PE unremarkable.

ULTRASONOGRAPHIC EXAMINATION OF THE ABDOMEN

Urinary System

The urinary bladder is adequately distended with anechoic contents. No masses, inflammatory changes, echogenic sediment or cystoliths are observed. The urinary bladder, trigone and visible pelvic urethra are normal in thickness with a smooth mucosal surface.

The right kidney is normal is size (3.96 cm), shape and echogenicity. It has smooth peripheral margination. There is a normal 1:3 cortex to medulla ratio with appropriate corticomedullary distinction. There is no evidence of pyelectasia, mineral or infarcts observed.

The left kidney is normal is size (3.96 cm), shape and echogenicity. It has smooth peripheral margination. There is a normal 1:3 cortex to medulla ratio with appropriate corticomedullary distinction. There is no evidence of pyelectasia, mineral or infarcts observed.

Adrenal Glands

The right adrenal gland is normal in size (0.60 cm at cranial pole and 0.40 cm at caudal pole), shape and overall architecture, echogenicity and echotexture. Visible surrounding vasculature appears normal.

The left adrenal gland is normal in size (0.50 cm at cranial pole and 0.30 cm at caudal pole), shape and overall architecture, echogenicity and echotexture. Visible surrounding vasculature appears normal.

Spleen

The spleen measures right at the upper end of normal limits for size (1.0 cm thick at the hilus) with a mildly swollen but smooth capsule. Parenchyma is normal and homogenous in echogenicity and echotexture. No focal nodules or masses are observed. Splenic vasculature appears normal.

Liver

The liver is subjectively normal in size with normal smooth curvilinear peripheral contour. Parenchyma is appropriately hypoechoic to the spleen in echogenicity and appropriately mildly coarse and homogenous in echotexture. No focal lesions are observed. Visible vasculature and biliary tree appear normal without distension or congestion.

The gallbladder is non-distended in size. The wall is smooth without visible thickening. Luminal contents are primarily anechoic. There is no evidence of cystic or common bile duct dilation.

Gastrointestinal

The visible stomach wall is normal in thickness and layering. The lumen is mildly distended with primarily fluid as well as some echogenic non-shadowing luminal contents and gas consistent with normal chyme. There is no evidence of obstruction, foreign material, or infiltrative disease. Pyloric outflow tract appears patent.



PATIENT

Jocko Murray

SPECIES

Feline

BREED

Domestic Shorthair

SEX

Neutered Male

AGE

1 Year

WEIGHT

10.3

INTERPRETED BY

Beth Johnson, DVM
DACVIM

IMAGING PERFORMED BY

Peter Langer, DVM

HOSPITAL NAME

North Hampton Animal
Hospital

REFERRING VET

Craig Kelleher, DVM

INVOICE

75288

DATE

5/20/26

The visible small intestine demonstrates areas of markedly/significantly thick muscularis layer relative to mucosa (disruption of the normal 1:3 muscularis:mucosa ratio). Small intestinal submucosa is slightly irregular, thick and hyperechoic, without evident loss of layering appreciated. The lumen of the small intestine is empty with no evidence of obstruction or foreign material.

The visible colon is normal in wall thickness (< 0.2 cm) and layering. Contents are consistent with normal formed feces and gas.

Pancreas

The pancreas that is observed appears appropriately isoechoic to surrounding omental fat. Visible capsule is smooth and normal in contour. Visible pancreatic parenchyma is homogenous and unremarkable. There is no visible pancreatic duct dilation. There is no evidence of active peripancreatic inflammation.

Free Abdomen

There is no visible free peritoneal effusion noted in these images.

Mesenteric lymph nodes are prominent in size with swollen capsular contour. Normal elongated shape (length to width ratio) is maintained. There is no loss of parenchymal detail.

ULTRASONOGRAPHIC FINDINGS

- Marked/significant inflammatory bowel disease (IBD) pattern – Thick muscularis has been reported with infiltrative bowel disease including both benign inflammatory disease as well as infiltrative neoplasia such as lymphoma. No loss of layering or distinct characteristics of malignancy are present. Therefore, differentials cannot be further ranked without tissue sampling.
- Mild/subtle splenomegaly– can be associated with congestion caused by sedation (if sedated) but can also be associated with diffuse infiltrative disease. Both benign conditions such as extramedullary hematopoiesis, lymphoid hyperplasia, amyloidosis as well as infiltrative neoplastic diseases such as round cell neoplasia should be considered.
- Moderately reactive mesenteric lymph nodes – infiltrative neoplastic disease cannot be ruled out but is considered less likely.

INTERPRETATION OF THE FINDINGS & FURTHER RECOMMENDATIONS

- A gastrointestinal malabsorption panel (including cobalamin, folate, TLI and PLI) to Texas A&M GI Laboratory is recommended for further evaluation of GI and pancreatic function.
- A routine fecal/giardia exam is recommended if not recently evaluated.
- A fecal enteropathogen PCR panel to Texas A&M GI Laboratory could be considered for further evaluation of possible infectious disease. Contact lab for recommendations on how long to discontinue antibiotics (if indicated) prior to obtaining a stool sample for submission.
- Ideally, biopsies of the GI tract, being sure to include ileum if possible, are recommended to definitively diagnose and therefore manage the infiltrative bowel disease.



PATIENT

Jocko Murray

SPECIES

Feline

BREED

Domestic Shorthair

SEX

Neutered Male

AGE

1 Year

WEIGHT

10.3

INTERPRETED BY

Beth Johnson, DVM
DACVIM

IMAGING PERFORMED BY

Peter Langer, DVM

HOSPITAL NAME

North Hampton Animal Hospital

REFERRING VET

Craig Kelleher, DVM

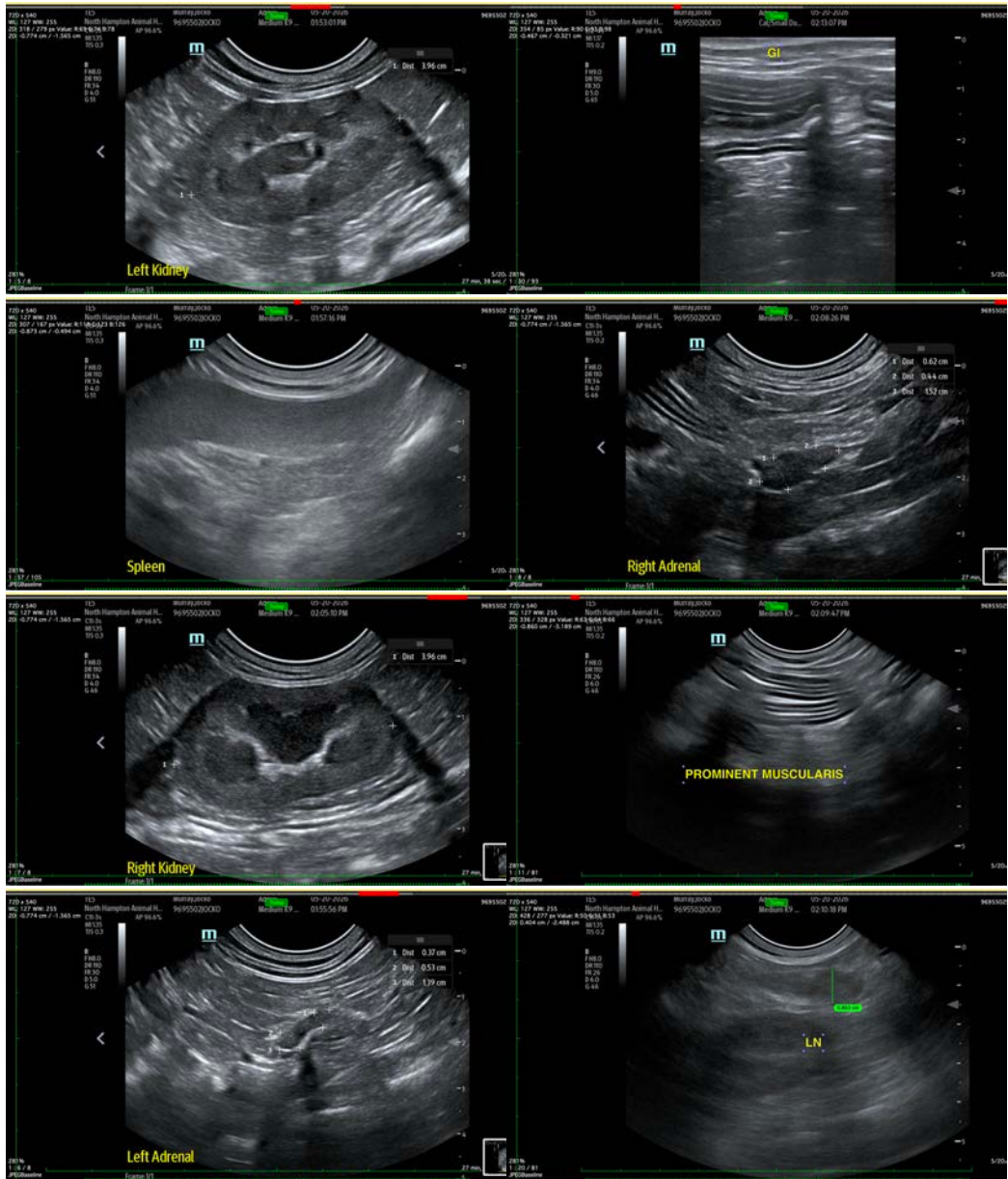
INVOICE

75288

DATE

5/20/26

- If biopsies cannot be obtained, empirical therapies could include a probiotic (if diarrhea is present, such as visbiome or proviable), empirical deworming with a 5-day course of Panacur and, if tolerated, a transition in diet, based on trial-and-error response, beginning with a hydrolyzed protein diet. Some patients respond to one brand/version of a hydrolyzed protein diet better than another brand, so several trials may be required.
- Additional considerations could include cobalamin supplementation (unless cobalamin level is evaluated and supplementation is not warranted) and prednisolone (if not contraindicated based on patient contraindications, co-morbidities, etc.).





PATIENT

Jocko Murray

SPECIES

Feline

BREED

Domestic Shorthair

SEX

Neutered Male

AGE

1 Year

WEIGHT

10.3

INTERPRETED BY

Beth Johnson, DVM
DACVIM

IMAGING PERFORMED BY

Peter Langer, DVM

HOSPITAL NAME

North Hampton Animal
Hospital

REFERRING VET

Craig Kelleher, DVM

INVOICE

75288

DATE

5/20/26

The information and recommendations provided are based on the images presented by the referring veterinarian/sonographer. No evaluation can be communicated regarding pathology that was not visible in the image/video clips provided.

Thank you for this referral. If the clinical or image interpretation does not parallel your findings or if I can be of any further assistance please contact me.

Beth Johnson, DVM, DACVIM
info@sonopath.com