

**DATE PRESENTING CLINICAL SIGNS**

5/20/22 5/5/22: P presented for 0.7lb of weight loss in past year. One of the cats in the household was vomiting last week. PE: Dark brown discharge AU, heart and lungs auscult wnl. Abdomen palpates soft and non-painful; no overt masses or organomegaly.

PATIENT

Rosie Brown

Current Medications: None.

SPECIES

Feline

Lab Results: 5/5/22: CBC: Mild lymphocytosis 6.133K/uL Ddx: stress, neoplasia. Chemistry: Mild hypocholesterolemia 88mg/dL Ddx: malabsorption/maldigestion, liver disease, lymphangiectasia UA (not received). T4: 1.1ug/dL

Date of Previous IntraPet Ultrasound: No previous.

Sedation: Not required to complete full diagnostic ultrasound.

Stat Report: Not requested.

BREED

DSH

ULTRASONOGRAPHIC EXAMINATION OF THE ABDOMEN**SEX**

Spayed Female

Urinary System

Urinary bladder is moderately distended. It has a normal uniform wall thickness (<0.2 cm). Contents include primarily anechoic fluid combined with suspended echogenic non-shadowing debris within the fluid. No masses or cystoliths are observed. The trigone and visible pelvic urethra are normal in thickness with a smooth mucosal surface.

AGE

2011

The right kidney is normal in size (3.37 cm), shape and echogenicity. It has smooth peripheral margination. There is a normal 1:3 cortex to medulla ratio with appropriate corticomedullary distinction. There is no evidence of pyelectasia, mineral or infarcts observed.

WEIGHT

7.3 Pounds

The left kidney is normal in size (3.42 cm), shape and echogenicity. It has smooth peripheral margination. There is a normal 1:3 cortex to medulla ratio with appropriate corticomedullary distinction. There is no evidence of pyelectasia, mineral or infarcts observed.

INTERPRETED BYBeth Johnson, DVM
DACVIM**Adrenal Glands**

The right adrenal gland is normal in size (0.35 cm thick), shape and contour. Corticomedullary structure is unremarkable. Visible surrounding vasculature appears normal.

IMAGING PERFORMED BY

Andi Parkinson RDMS

The area of the left adrenal gland is examined without evident pathology.

HOSPITAL NAME

Timonium AH

Spleen

The spleen is subjectively normal in size with a normal smooth capsular contour. Parenchyma is appropriately finely textured and homogenous with normal echogenicity relative to surrounding tissue (hyperechoic to liver). No focal nodules or masses are observed. Splenic vasculature appears normal.

REFERRING VET

Dr. Falkowski

Liver

The liver is subjectively normal in size with normal smooth curvilinear peripheral contour. Parenchyma is appropriately hypoechoic to the spleen in echogenicity and appropriately mildly coarse and homogenous in echotexture. No focal lesions are observed. Visible vasculature and biliary tree appear normal without distension or congestion.

INVOICE

37843

The gallbladder is non-distended in size. The wall is smooth without visible thickening. Luminal contents are primarily anechoic. A tortuous but non-distended common bile duct is noted, which is an incidental, age related change.

Gastrointestinal

The stomach wall is normal in thickness (canine < 0.5 cm and feline < 0.4 cm) and layering. The lumen of the stomach is empty with no evidence of obstruction, foreign material or infiltrative disease. Pyloric outflow tract appears patent.

The visible small intestines are normal in wall thickness. Normal layering is maintained except for a diffusely disproportionately thick muscularis layer relative to mucosa. Small intestinal motility appears adequate (1-3 contractions per min). The lumen of the small intestine is empty with no evidence of obstruction, foreign material or infiltrative disease.

The visible colon is normal in wall thickness (< 0.2 cm) and layering. Contents are consistent with normal formed feces and gas.

Pancreas

The pancreas is diffusely prominent in size and mildly irregular in shape, with a diffusely coarse echotexture and hypoechoic echogenicity. No duct dilation is appreciated. Enhanced hyperechoic peripancreatic fat and mesentery is appreciated. No free fluid is present.

Free Abdomen

There is no evidence of peritoneal effusion. There is no apparent lymphadenopathy.

PRIMARY FINDINGS

- Mild acute or smoldering acute on chronic pancreatitis.
- Thick muscularis – This finding has been reported in cats with infiltrative bowel disease including both benign inflammatory disease as well as infiltrative neoplasia such as lymphoma.

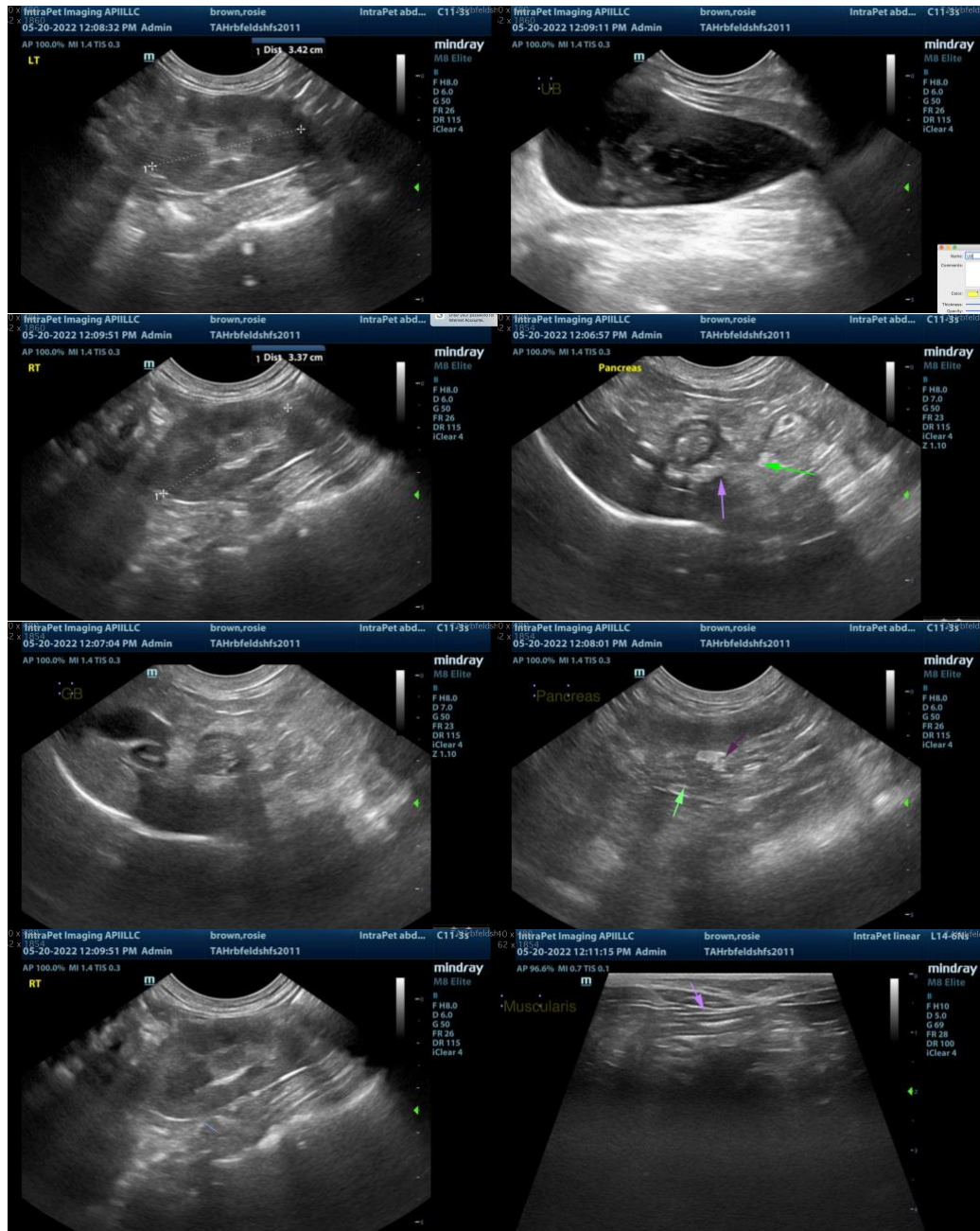
SECONDARY FINDINGS

- Urinary bladder sediment – Urine changes are most consistent with incidental suspended lipid in a cat, however, cellular debris or crystalluria cannot be ruled out and should be interpreted in combination with urinalysis results.
- Age related tortuous common bile duct.

INTERPRETATION OF THE FINDINGS & FURTHER RECOMMENDATIONS

- Given the bowel and pancreatic changes, a gastrointestinal malabsorption panel including TLI, PLI, folate and cobalamin to Texas A&M GI laboratory is recommended
- Urinalysis and urine culture, if indicated based on urinalysis results.
- While pending the above recommended diagnostic results, medical management for pancreatitis with antiemetics, gastroprotectants, pain management +/- antibiotics as well as a transition to a low-fat diet is recommended.
- Ultimately, if medical management of pancreatitis does not result in improvement of clinical signs, biopsies of the gastrointestinal tract, being sure to include the ileum if possible, may be necessary to definitively diagnosis and therefore manage this patient's underlying bowel disease.

- Bile acids could be considered, given the low cholesterol. However, more weight is given to likely gastrointestinal disease, given the ultrasonographic changes. If bile acids are abnormal, recommendations change to further workup of liver disease, beginning with an abdominal CT scan versus the above recommended gastrointestinal disease evaluation and treatment.



The information and recommendations provided are based on the images presented by the referring veterinarian/sonographer. No evaluation can be communicated regarding pathology that was not visible in the image/video clips provided.

Thank you for this referral. If the clinical or image interpretation does not parallel your findings or if I can be of any further assistance please contact me.

Beth Johnson, DVM, DACVIM
Beth.Johnson@sonopath.com