



**DATE PRESENTING CLINICAL SIGNS**

5/19/2026

**Patient History:** Hx: Vomiting: 3 episodes of yellow bile in past 24 hrs (late night, ~8 pm, before arrival). Anorexia: No food intake (wet or dry) in past 24 hrs - continued into 5/19 so owner elected for hospitalization of the patient. Diet: Hill's Science Diet Z/D (strict due to allergies), wet food offered when dry food intake low  
No new treats, no dietary changes, no observed ingestion of foreign objects. Last blood work: 1 year ago, full panel, results normal. No prior illness, no previous vomiting episodes.

**PATIENT**

Tiramisu Rodriguez

**SPECIES**

Feline

**Current Medications:** Ondansetron 0.5 mg/kg IV q8h, Maropitant 1 mg/kg IV q24h, Mirtazapine transdermal once, IVF 60 ml/kg/day, KCl 30 mEq/L, Gabapentin 50 mg PO q8h.

**BREED**

DSH

**Labwork Results:** Labwork not submitted. Reported as 5/18 Pcv/ts: 45/8.1. Cbc: NSF. Chem 17 + lytes: Crea 0.7, Bun 11, K 3.3. Rads--Normal geriatric thorax. A degree of underlying chronic lower airway disease can't be totally ruled out. The radiographic abdominal changes in light of the reported clinical signs are currently most suggestive of non-specific gastroenteritis. No current evidence of complete small intestinal mechanical obstruction. No evidence of small intestinal mineral foreign material. Considering the patient's signalment an underlying infiltrative process (lymphoma vs IBD) can't be ruled out. 5/19 Pcv/ts: 40/8 Lytes: K 3.

**SEX**

FS

**AGE**

9/18/2014

**Date of Previous IntraPet Ultrasound:** No previous.

**Sedation:** Torb required to complete full diagnostic ultrasound.

**WEIGHT**

5.67 kg

**Stat Report:** Requested.

**Imaging Performed by:** Andi Parkinson RDMS

**INTERPRETED BY**

Beth Johnson, DVM  
DACVIM

**ULTRASONOGRAPHIC EXAMINATION OF THE ABDOMEN**

**Urinary System**

**HOSPITAL NAME**

VEG ER for Pets  
Pikeville

The urinary bladder is adequately distended with anechoic contents. No masses, inflammatory changes, echogenic sediment or cystoliths are observed. The urinary bladder, trigone and visible pelvic urethra are normal in thickness with a smooth mucosal surface.

**REFERRING VET**

Dr. Nacke

Kidneys are overall normal in size and shape with smooth peripheral margination. A normal 1:3 cortex to medulla ratio is maintained. The medulla and cortices are uniform in texture with some mild increased cortical echogenicity and mild loss of corticomedullary distinction, expected in this age patient. There is no evidence of pyelectasia, mineral or infarcts observed. Left kidney measures 3.8 cm, and the right kidney measures 3.9 cm.

**INVOICE**

11965

**Adrenal Glands**

The right adrenal gland is normal in size (0.34 cm), shape and overall architecture, echogenicity and echotexture. Visible surrounding vasculature appears normal.

The left adrenal gland is normal in size (0.31 cm), shape and overall architecture, echogenicity and echotexture. Visible surrounding vasculature appears normal.

### ***Spleen***

Spleen is subjectively large in size (just over 1.0 cm thick at the hilus) with a mildly swollen but smooth capsule. Parenchyma is normal and homogenous in echogenicity and echotexture. No focal nodules or masses are observed. Splenic vasculature appears normal.

### ***Liver***

Liver is subjectively enlarged (swollen contour) with a diffusely mildly coarse architecture and subtly increased portal markings. Mildly mixed echogenic changes are noted diffusely. No focal lesions are observed. Visible vasculature and biliary tree appear normal without distension or congestion.

The gallbladder is non-distended in size. The wall is subjectively mildly prominent and hyperechoic, potentially mildly thick. The gallbladder also appears to be bilobed. Luminal contents are primarily anechoic. There is no evidence of cystic or common bile duct dilation.

### ***Gastrointestinal***

The visible stomach wall is normal in thickness and layering. The lumen of the stomach is mildly distended with echogenic non-shadowing luminal contents and gas consistent with normal ingesta. There is no evidence of obstruction or foreign material noted. Pyloric outflow tract appears patent.

The visible small intestines are normal in wall thickness and layering. Small intestinal motility appears adequate (1-3 contractions per min). The lumen of the small intestine is **mildly distended with echogenic non-shadowing luminal contents and gas consistent with normal ingesta. There is no evidence of obstruction or foreign material noted.**

The visible colon is normal in wall thickness (< 0.2 cm) and layering. Contents are consistent with normal formed feces and gas.

### ***Pancreas***

The pancreas that is observed appears appropriately isoechoic to surrounding omental fat. Visible capsule is smooth and normal in contour. Visible pancreatic parenchyma is homogenous and unremarkable. There is no visible pancreatic duct dilation. There is no evidence of active peripancreatic inflammation.

### ***Free Abdomen***

There is no visible free peritoneal effusion noted in these images.

There is no apparent pathologic lymphadenopathy noted in these images.

### **PRIMARY FINDINGS**

- Mild/subtle splenomegaly– can be associated with congestion caused by sedation (if sedated) but can also be associated with diffuse infiltrative disease. Both benign conditions such as extramedullary hematopoiesis, lymphoid hyperplasia, amyloidosis as well as infiltrative neoplastic diseases such as round cell neoplasia should be considered.

- The liver changes are similarly mild, and non-specific but could represent an emerging microscopic hepatopathy including both benign or infiltrative neoplastic differentials.
- Concurrent chronic low grade smoldering concurrent cholangitis can't be ruled out and should be suspected in the face of appropriate clinical signs and/or lab changes.
- The gastric contents are most consistent with normal ingesta/chyme without definitive evidence of foreign material. Having said that, non-obstructive, non-discretely shadowing foreign material, i.e. hair ball versus other can't be definitely ruled out. Reevaluation following an additional 12-24 hours of fasting could be considered.

## SECONDARY FINDINGS

- Mild age-related kidney changes.

## INTERPRETATION OF THE FINDINGS & FURTHER RECOMMENDATIONS

If not recently evaluated, a T4 +/- Free T4 is recommended.

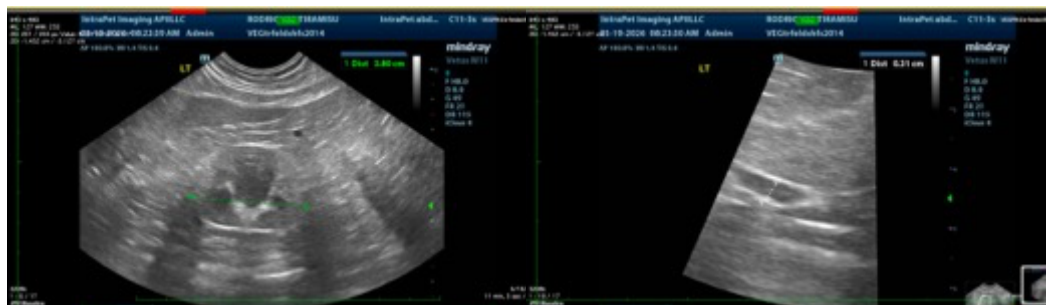A gastrointestinal malabsorption panel (including cobalamin, folate, TLI and PLI) to Texas A&M GI Laboratory is recommended for further evaluation of GI and pancreatic function.

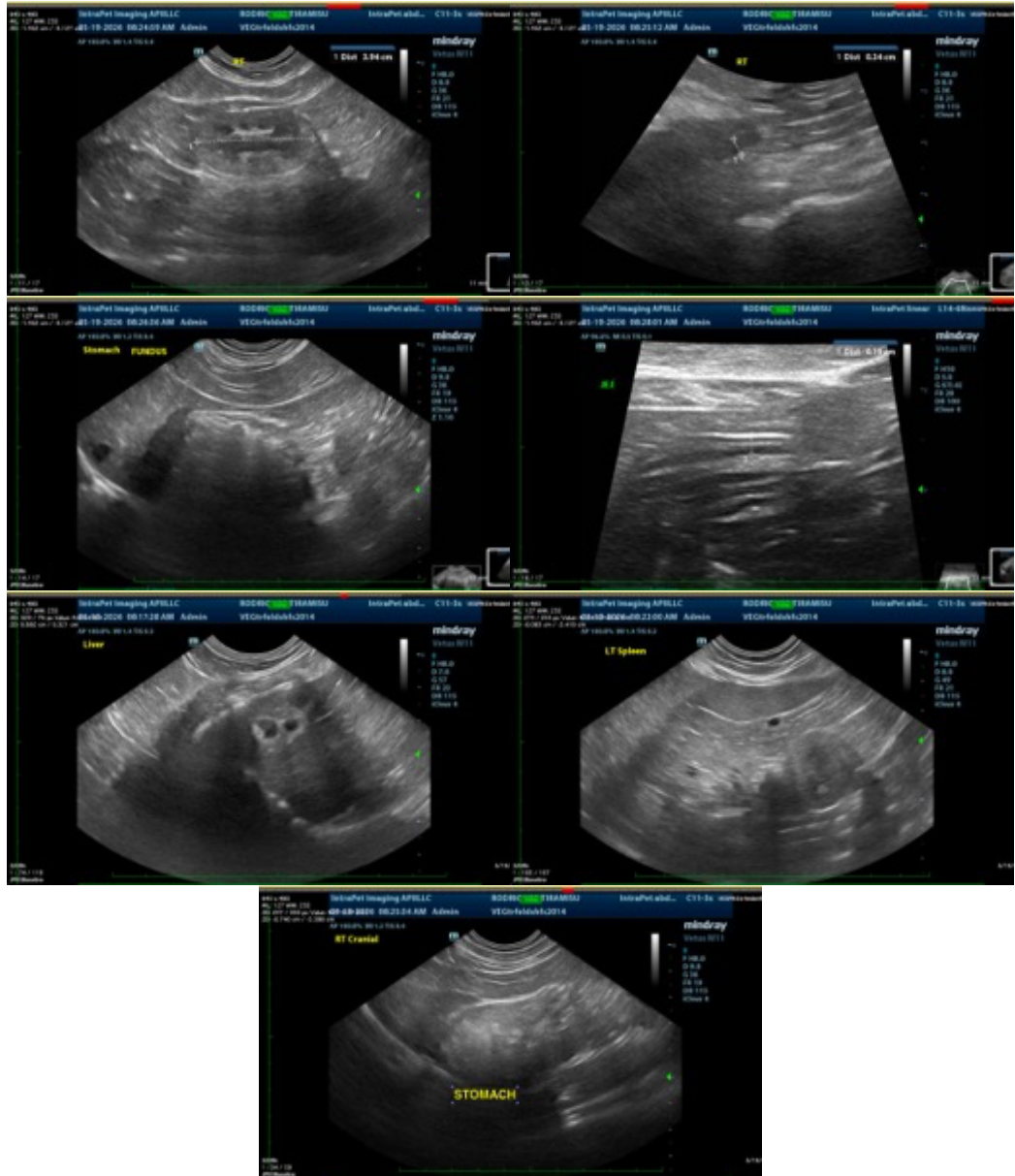
Fine needle aspirates of the liver and spleen could be considered if patient's coagulation status is appropriate.

Reassessment of the gastric contents may be appropriate.

In the meantime, in addition to supportive/symptomatic medical management of clinical signs and any further diagnostic or treatment recommendations indicated by the above diagnostics, if tolerated, a transition in diet is recommended, based on trial-and-error response.

Some options to consider include a gastrointestinal biome diet vs a hydrolyzed protein diet (sometimes several trials with different brands are necessary) vs a fiber response/colitis diet vs a bland, easy to digest or low-fat diet vs other.





The information and recommendations provided are based on the images presented by the referring veterinarian/sonographer. No evaluation can be communicated regarding pathology that was not visible in the image/video clips provided.

Thank you for this referral. If the clinical or image interpretation does not parallel your findings or if I can be of any further assistance please contact me.

Beth Johnson, DVM, DACVIM  
 info@sonopath.com