



## PATIENT

Mocha Garcia

## SPECIES

Canine

## BREED

Longhair Chihuahua

## SEX

FS

## AGE

14

## WEIGHT

4.66

## INTERPRETED BY

Beth Johnson, DVM  
DACVIM

## IMAGING PERFORMED BY

Matt

## HOSPITAL NAME

TLC Animal Hospital

## REFERRING VET

Dr. Vicky Dashley

## INVOICE

11979

## DATE

5/19/2026

## PRESENTING CLINICAL SIGNS

Unexplained weight loss pending TAMU GI panel. mild neutrophilia 10.4 (stress vs infection vs inflammation), glucose 115 (stress), bun 36 (consistent w/ previous BWs), USG 1.027, lymphoma screen negative.

## ULTRASONOGRAPHIC EXAMINATION OF THE ABDOMEN

### Urinary System

The urinary bladder is adequately distended with anechoic contents. No masses, inflammatory changes, echogenic sediment or cystoliths are observed. The urinary bladder, trigone and visible pelvic urethra are normal in thickness with a smooth mucosal surface.

The right kidney is normal in size (2.97 cm), shape and echogenicity. It has smooth peripheral margination. There is a normal 1:3 cortex to medulla ratio with appropriate corticomedullary distinction. There is no evidence of pyelectasia, mineral or infarcts observed.

The left kidney is normal in size (2.69 cm), shape and echogenicity. It has smooth peripheral margination. There is a normal 1:3 cortex to medulla ratio with appropriate corticomedullary distinction. There is no evidence of pyelectasia, mineral or infarcts observed.

### Adrenal Glands

The right adrenal gland is unable to be well visualized in these images.

The left adrenal gland is normal in size (0.45 cm at cranial pole and 0.41 cm at caudal pole), shape and overall architecture, echogenicity and echotexture. Visible surrounding vasculature appears normal.

### Spleen

The spleen is subjectively normal in size with a normal smooth capsular contour. Parenchyma is appropriately finely textured and homogenous with normal echogenicity relative to surrounding tissue (hyperechoic to liver). No focal nodules or masses are observed. Splenic vasculature appears normal.

### Liver

The liver is subjectively normal in size with normal smooth curvilinear peripheral contour. Parenchyma is appropriately hypoechoic to the spleen in echogenicity and appropriately mildly coarse and homogenous in echotexture. No focal lesions are observed. Visible vasculature and biliary tree appear normal without distension or congestion.

Gallbladder is moderately distended with anechoic bile as well as suspended and gravity dependent echogenic debris. The wall is smooth without visible thickening. There is no evidence of cystic or CBD dilation. There is no evidence of effusion or inflammation.

### Gastrointestinal

The visible stomach wall is normal in thickness and layering. The lumen of the stomach is empty with no evidence of obstruction, foreign material or infiltrative disease. Pyloric outflow tract appears patent.



## PATIENT

Mocha Garcia

## SPECIES

Canine

## BREED

Longhair Chihuahua

## SEX

FS

## AGE

14

## WEIGHT

4.66

## INTERPRETED BY

Beth Johnson, DVM  
DACVIM

## IMAGING PERFORMED BY

Matt

## HOSPITAL NAME

TLC Animal Hospital

## REFERRING VET

Dr. Vicky Dashley

## INVOICE

11979

## DATE

5/19/2026

The visible small intestines are normal in wall thickness and layering. Small intestinal motility appears adequate (1-3 contractions per min). The lumen of the small intestine is empty with no evidence of obstruction, foreign material or infiltrative disease.

The visible colon is normal in wall thickness (< 0.2 cm) and layering. Contents are consistent with normal formed feces and gas.

### **Pancreas**

The pancreas that is observed appears appropriately isoechoic to surrounding omental fat. Visible capsule is smooth and normal in contour. Visible pancreatic parenchyma is homogenous and unremarkable. There is no visible pancreatic duct dilation. There is no evidence of active peripancreatic inflammation.

### **Free Abdomen**

There is no visible free peritoneal effusion noted in these images.

There is no apparent pathologic lymphadenopathy noted in these images.

### **ULTRASONOGRAPHIC FINDINGS**

- Moderate gallbladder debris - Cholecystic debris is of unknown clinical significance. It can be seen with biliary stasis from fasting or illness. Cholecystic debris is not necessarily related to hepatobiliary disease. Echogenic bile is most commonly an incidental finding in dogs and should be interpreted in combination with clinical signs such as nausea, inappetence, cranial abdominal discomfort and/or laboratory changes such as increased ALP and/or increased Tbili.

### **INTERPRETATION OF THE FINDINGS & FURTHER RECOMMENDATIONS**

There is not a definitive ultrasonographically visible intraabdominal explanation for patient's reported unexplained weight loss. For the recommendations regarding the weight loss depend in part on daily caloric intake. If not already evaluated, a thorough evaluation of daily caloric intake is recommended to assure an adequate daily caloric intake is occurring vs an inadvertent reduction in calories due to change in diet and/or feeding schedule, competitive eating environment, etc.

Especially in the face of normal or even increased daily caloric intake, further evaluation of digestion and absorption is the next recommendation. As is reportedly already pending, a gastrointestinal malabsorption panel (including cobalamin, folate, TLI and PLI) to Texas A&M GI Laboratory is recommended for further evaluation of GI and pancreatic function.

Otherwise, and/or in addition to above, further evaluation for possible pain (dental, orthopedic, other), upper respiratory disease or oropharyngeal disease, cardiac disease and/or neurologic disease vs other as possible causes for unintentional weight loss is also recommended.



**PATIENT**

Mocha Garcia

**SPECIES**

Canine

**BREED**

Longhair Chihuahua

**SEX**

FS

**AGE**

14

**WEIGHT**

4.66

**INTERPRETED BY**

Beth Johnson, DVM  
DACVIM

**IMAGING PERFORMED BY**

Matt

**HOSPITAL NAME**

TLC Animal Hospital

**REFERRING VET**

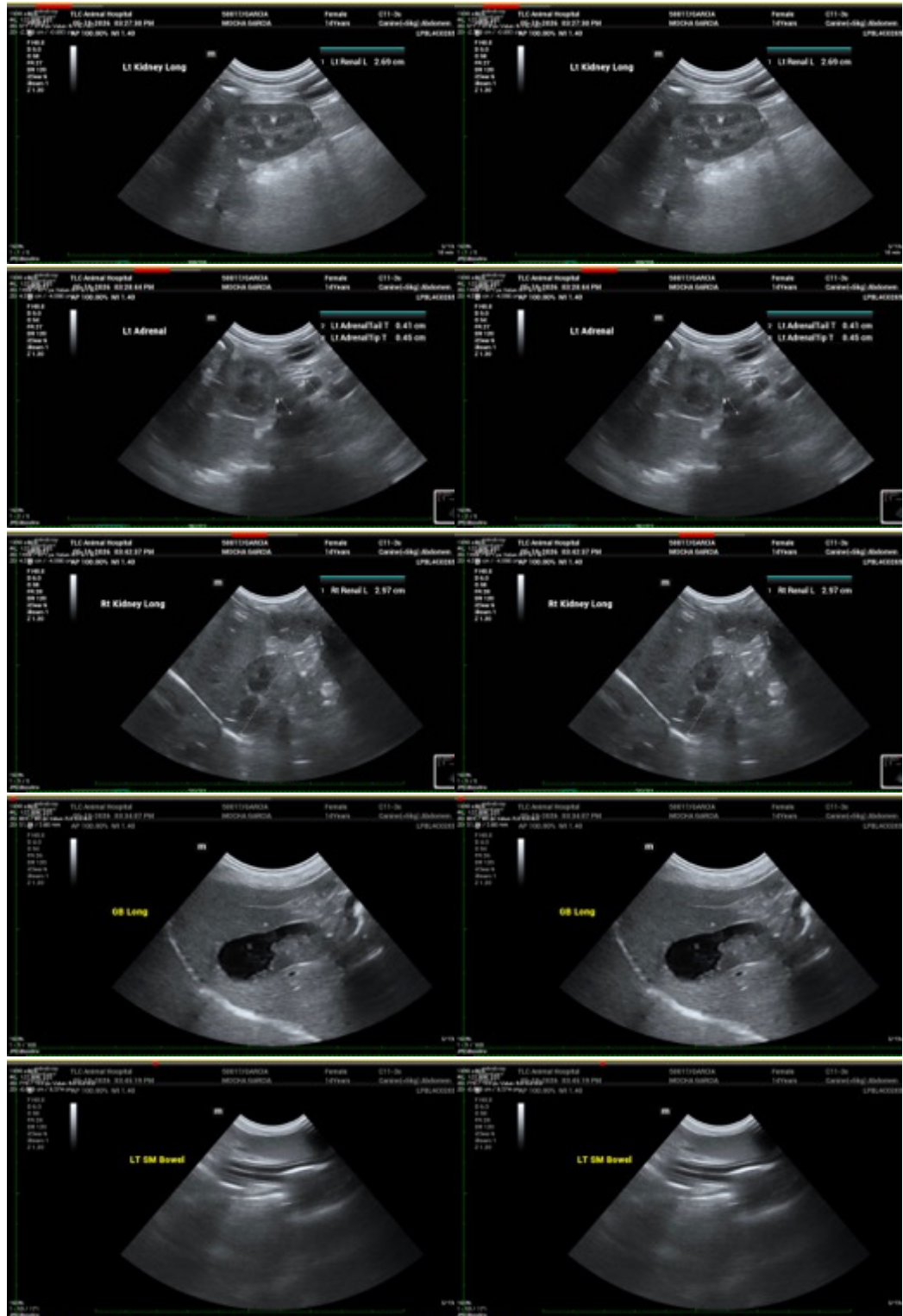
Dr. Vicky Dashley

**INVOICE**

11979

**DATE**

5/19/2026



The information and recommendations provided are based on the images presented by the referring



## PATIENT

Mocha Garcia

## SPECIES

Canine

## BREED

Longhair Chihuahua

## SEX

FS

## AGE

14

## WEIGHT

4.66

## INTERPRETED BY

Beth Johnson, DVM  
DACVIM

## IMAGING PERFORMED BY

Matt

## HOSPITAL NAME

TLC Animal Hospital

## REFERRING VET

Dr. Vicky Dashley

## INVOICE

11979

## DATE

5/19/2026

veterinarian/sonographer. No evaluation can be communicated regarding pathology that was not visible in the image/video clips provided.

Thank you for this referral. If the clinical or image interpretation does not parallel your findings or if I can be of any further assistance please contact me.

**Beth Johnson, DVM, DACVIM**  
info@sonopath.com