



**PATIENT**

Casey Mitchell

**SPECIES**

Canine

**BREED**

Hound x

**SEX**

Spayed Female

**AGE**

11 Years

**WEIGHT**

28 kg

**INTERPRETED BY**

Beth Johnson, DVM  
 DACVIM

**IMAGING PERFORMED BY**

Amanda Stewart

**HOSPITAL NAME**

Graham Animal  
 Hospital

**REFERRING VET**

Dr. Levstein

**INVOICE**

75244

**DATE**

5/19/26

**PRESENTING CLINICAL SIGNS**

Presented May 8 for wellness exam, senior pet with lipomas, weak/painful hind end (OA), and increased RR. Bloodwork showed elevated liver values. Concern for pathology vs old age vs mets? Current Medications: On Bravecto for prevention

Abnormal PE/Chem/CBC/UA Results: Increased: ALT at 137, ALP at 2281, GGT at 165, Cholesterol at 9.6, Triglycerides at 1.75 Radiographic Findings none Primary Question to Be Answered in This Exam Cause of elevated liver values? Appears nonclinical but would like to start nsaid, so inquiring as to whether this is deemed safe.

**ULTRASONOGRAPHIC EXAMINATION OF THE ABDOMEN**

**Urinary System**

The urinary bladder is adequately distended with anechoic contents. No masses, inflammatory changes, echogenic sediment or cystoliths are observed. The urinary bladder, trigone and visible pelvic urethra are normal in thickness with a smooth mucosal surface.

The right kidney is normal is size (7.25 cm), shape and echogenicity. It has smooth peripheral margination. There is a normal 1:3 cortex to medulla ratio with appropriate corticomedullary distinction. There is no evidence of pyelectasia, mineral or infarcts observed.

The left kidney is normal is size (7.58 cm), shape and echogenicity. It has smooth peripheral margination. There is a normal 1:3 cortex to medulla ratio with appropriate corticomedullary distinction. There is no evidence of pyelectasia, mineral or infarcts observed.

**Adrenal Glands**

The right adrenal gland is unable to be well visualized in these images.

The left adrenal gland is normal in size (0.56 cm at cranial pole and 0.53 cm at caudal pole), shape and overall architecture, echogenicity and echotexture. Visible surrounding vasculature appears normal.

**Spleen**

The spleen is subjectively normal in size with a normal smooth capsular contour. Parenchyma is appropriately finely textured and homogenous with normal echogenicity relative to surrounding tissue (hyperechoic to liver). No focal nodules or masses are observed. Splenic vasculature appears normal.

**Liver**

In the mid cranial abdomen there is an approximately 7.6 cm x 9.5 cm homogeneous, hypoechoic mass that appears to originate from the mid caudal liver. The remaining cranial liver is more normal in size, appearance, echotexture and echogenicity. Splenic origination can't be definitively ruled out but seems less likely based on most images.

The gallbladder is non-distended in size. The wall is smooth without visible thickening. Luminal contents are primarily anechoic. There is no evidence of cystic or common bile duct dilation.

**Gastrointestinal**

The visible stomach wall is normal in thickness and layering. The lumen of the stomach is mildly distended with a small to moderate amount of echogenic non-shadowing luminal contents and gas



**PATIENT**

Casey Mitchell

consistent with normal ingesta. There is no evidence of obstruction, foreign material or infiltrative disease. Pyloric outflow tract appears patent.

**SPECIES**

Canine

The visible small intestines are normal in wall thickness and layering. Small intestinal motility appears adequate (1-3 contractions per min). The lumen is mildly distended with echogenic non-shadowing luminal contents and gas consistent with normal ingesta/chyme. There is no evidence of obstruction, foreign material or infiltrative disease.

**BREED**

Hound x

The visible colon is normal in wall thickness (< 0.2 cm) and layering. Contents are consistent with normal formed feces and gas.

**Pancreas**

**SEX**

Spayed Female

The pancreas that is observed appears appropriately isoechoic to surrounding omental fat. Visible capsule is smooth and normal in contour. Visible pancreatic parenchyma is homogenous and unremarkable. There is no visible pancreatic duct dilation. There is no evidence of active peripancreatic inflammation.

**AGE**

11 Years

**Free Abdomen**

**WEIGHT**

28 kg

There is no visible free peritoneal effusion noted in these images.

There is no apparent pathologic lymphadenopathy noted in these images.

**ULTRASONOGRAPHIC FINDINGS**

**INTERPRETED BY**

Beth Johnson, DVM  
DACVIM

- Suspect mid caudal liver mass, which could represent a benign process such as a hepatoma/adenoma, steroid or vacuolar hepatopathy, inflammatory process, other, although infiltrative neoplasia including primary hepatocellular carcinoma, round cell neoplasia, other can't be ruled out without tissue sampling. As mentioned above, origination from spleen or other area can't be definitively ruled out but is believed to be less likely.

**IMAGING PERFORMED BY**

Amanda Stewart

**INTERPRETATION OF THE FINDINGS & FURTHER RECOMMENDATIONS**

Three view thoracic radiographs are recommended for further assessment of cardio-pulmonary status as well as to further evaluate for any evidence of metastatic disease, if not recently evaluated.

**HOSPITAL NAME**

Graham Animal  
Hospital

Fine needle aspirates of the mass are recommended if patient's coagulation status is appropriate.

**REFERRING VET**

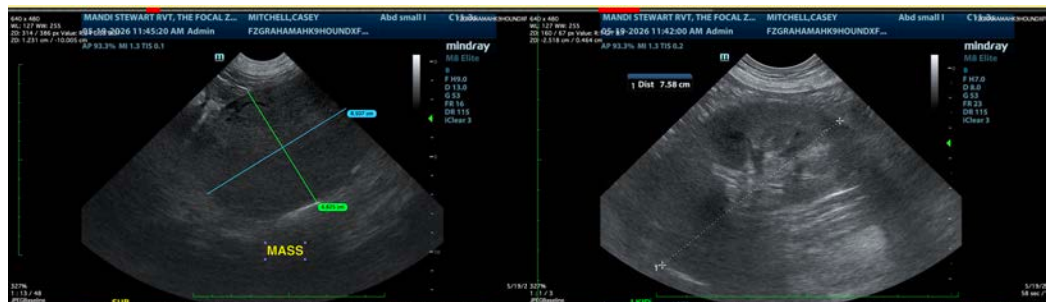Dr. Levstein

**INVOICE**

75244

**DATE**

5/19/26





**PATIENT**

Casey Mitchell

**SPECIES**

Canine

**BREED**

Hound x

**SEX**

Spayed Female

**AGE**

11 Years

**WEIGHT**

28 kg

**INTERPRETED BY**

Beth Johnson, DVM  
 DACVIM

**IMAGING PERFORMED BY**

Amanda Stewart

**HOSPITAL NAME**

Graham Animal  
 Hospital

**REFERRING VET**

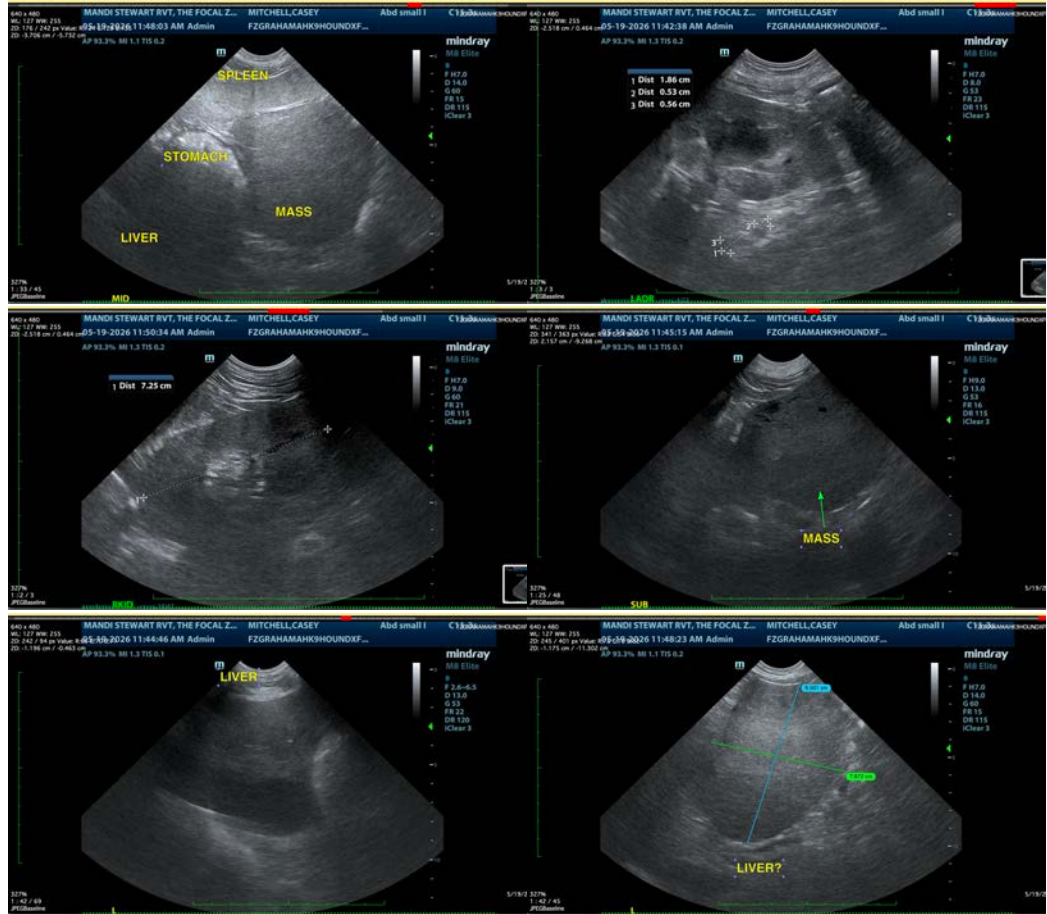
Dr. Levstein

**INVOICE**

75244

**DATE**

5/19/26



The information and recommendations provided are based on the images presented by the referring veterinarian/sonographer. No evaluation can be communicated regarding pathology that was not visible in the image/video clips provided.

Thank you for this referral. If the clinical or image interpretation does not parallel your findings or if I can be of any further assistance please contact me.

**Beth Johnson, DVM, DACVIM**  
 info@sonopath.com