

**DATE PRESENTING CLINICAL SIGNS**

5/19/22

5/17/2022: PE Not eating for 2 days, diarrhea. Abnormal for pet to not have interest in food. Pale pink mucous membranes, temp normal. Some stiffness in hips. Abdomen full/ tense and difficult to feel cranial aspect. Rectal- liquid brown stool, no fecal sample. Ran CBC, General Health Profile, Rads. See lab notes below.

PATIENT

Josie Murphy

SPECIES

Canine

BREED

Cocker Spaniel

SEX

Spayed Female

AGE

3/1/09

WEIGHT

27 Pounds

INTERPRETED BYBeth Johnson, DVM
DACVIM**IMAGING PERFORMED BY**

Rachel Brilhart RDMS

HOSPITAL NAME

Jacksonville VH

REFERRING VET

Dr. Larsson

INVOICE

37777

Current Medications: Metronidazole 125mg BID, Cerenia 24mg SID
Gabapentin 75mg BID for pain

Lab Results: Chem WNL. General Health Profile abnormal: Amylase 1726, ALT 119, HCT 23.4% mild anemia, HGB 8.2, Reticulocytes 147

WBC WNL, but neutrophils 11.83 w suspect bands, Monocytes 196, Platelets 59- clumping.

Radiographs: liver large possible mass caudal aspect of it versus spleen? Poor detail cranial abdomen appears to displace SI/LI caudoventrally

opacities L kidney multiple areas of spondylosis- thoracic vertebrae and upper lumbar.

Date of Previous IntraPet Ultrasound: No previous.

Sedation: Not required to complete full diagnostic ultrasound.

Stat Report: Declined.

ULTRASONOGRAPHIC EXAMINATION OF THE ABDOMEN**Urinary System**

The urinary bladder is moderately distended with anechoic contents. No masses, inflammatory changes, echogenic sediment or cystoliths are observed. The urinary bladder, trigone and visible pelvic urethra are normal in thickness with a smooth mucosal surface.

The right kidney is normal in size (5.89 cm), shape and echogenicity. It has smooth peripheral margination. There is a normal 1:3 cortex to medulla ratio with appropriate corticomedullary distinction. There is no evidence of pyelectasia, mineral or infarcts observed.

The left kidney is normal in size (6.2 cm), shape and echogenicity. It has smooth peripheral margination. There is a normal 1:3 cortex to medulla ratio with appropriate corticomedullary distinction. There is no evidence of pyelectasia, mineral or infarcts observed.

Adrenal Glands

The right adrenal gland is normal in size (2.5 cm long x 0.69 cm at the cranial pole and 0.62 cm at the caudal pole), shape and contour. Corticomedullary structure is unremarkable. Visible surrounding vasculature appears normal.

The left adrenal gland is normal in size (2.9 cm long x 0.53 cm at the cranial pole and 0.62 cm at the caudal pole), shape and contour. Corticomedullary structure is unremarkable. Visible surrounding vasculature appears normal.

Spleen

The spleen is subjectively large in size with a diffusely scalloped, irregular capsular contour. Parenchyma is diffusely mottled with multifocal mixed echogenic, cavitated masses of varying sizes that disrupt the capsule. Splenic vasculature appears normal.

Liver

The liver is similarly enlarged in size with scalloped, irregular contour. Parenchyma is similarly disrupted by the presence of multifocal mixed echogenic/cavitated masses, the largest of which measure 6.8 cm and is in the deep right liver, against the diaphragm, with a second more focal mass measuring 4.0 cm x 6.0 cm in the

ventral left liver with other similar appearing nodules/masses of varying sizes throughout the remaining architecture. Little to no normal parenchyma is visible in these images.

GB is moderately distended with anechoic bile and gravity dependent echogenic sediment. The wall is smooth without visible thickening. There is no evidence of cystic or CBD dilation. There is no evidence of effusion or inflammation.

Gastrointestinal

The stomach wall is normal in thickness (canine < 0.5 cm and feline < 0.4 cm) and layering. The lumen of the stomach is mildly distended with very echogenic reverberation artifact from intraluminal gas. There is no evidence of obstruction, foreign material or infiltrative disease; however, complete visualization of far wall is partially inhibited by gas. Pyloric outflow tract appears patent.

The visible small intestines are normal in wall thickness and layering (canine duodenum < 0.5 cm and feline duodenum < 0.4 cm; other < 0.3 cm). Small intestinal motility appears adequate (1-3 contractions per min). The lumen of the small intestine is empty with no evidence of obstruction, foreign material or infiltrative disease.

The visible colon is normal in wall thickness (< 0.2 cm) and layering. Contents are consistent with normal formed feces and gas.

Pancreas

The pancreas is similarly prominent in size with a similar scalloped, irregular capsule, characterized by mixed echogenic/cavitated masses throughout the pancreatic parenchyma.

Free Abdomen

There is a small to moderate amount of anechoic free fluid in the cranial abdomen, primarily around the pancreas and spleen. There is no apparent lymphadenopathy.

PRIMARY FINDINGS

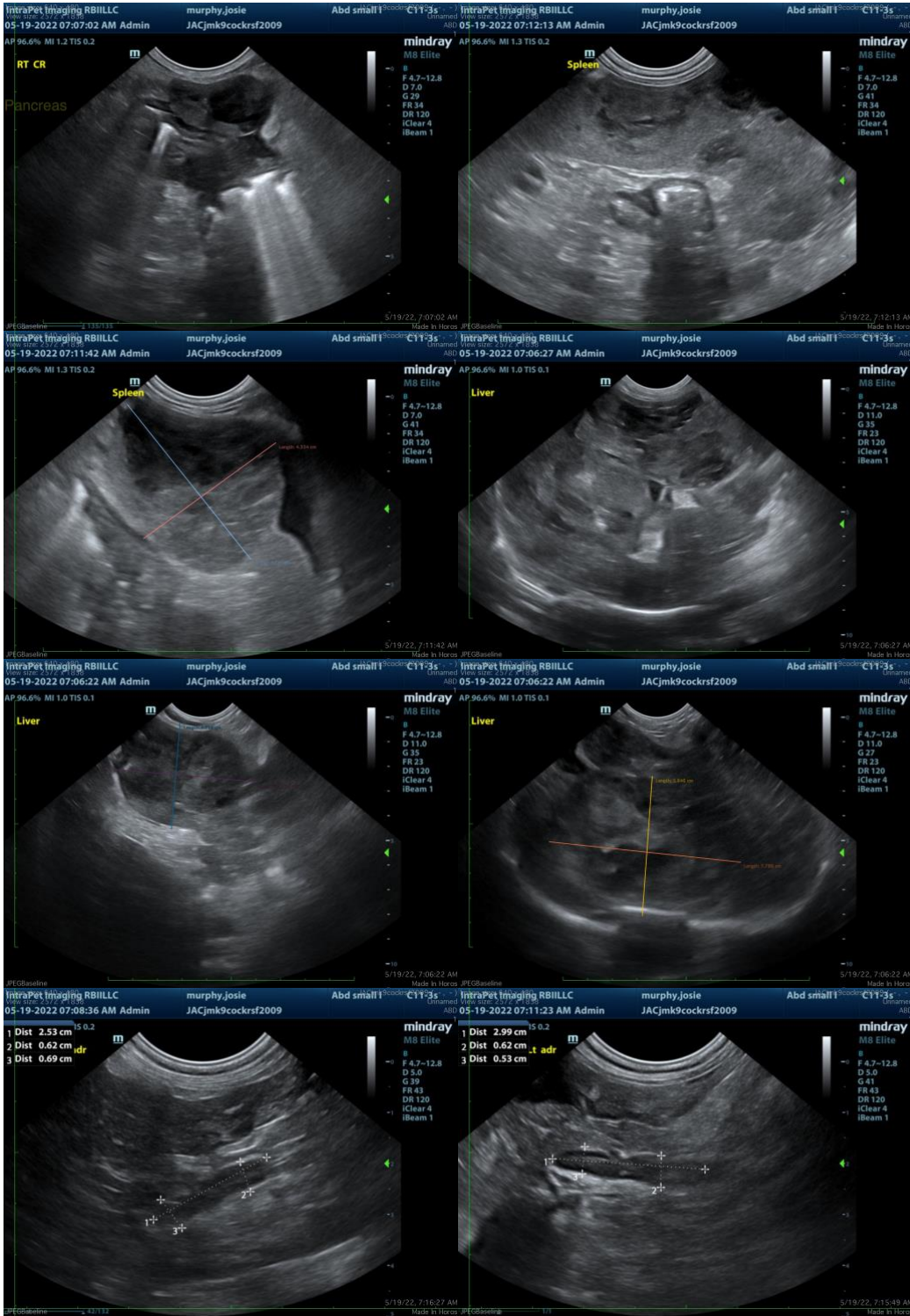
- Mixed echogenic cavitated masses throughout the liver, spleen and pancreas – most concerning for infiltrative or metastatic neoplasia.

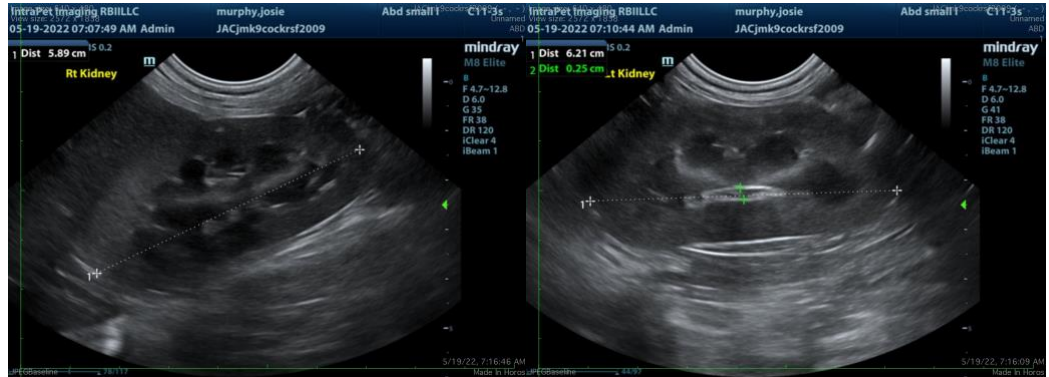
SECONDARY FINDINGS

- GB is moderately distended with anechoic bile and gravity dependent echogenic sediment. The wall is smooth without visible thickening. There is no evidence of cystic or CBD dilation. There is no evidence of effusion or inflammation.

INTERPRETATION OF THE FINDINGS & FURTHER RECOMMENDATIONS

A fine needle aspirate of the spleen, liver and/or pancreas could be considered if patient's coagulation status is appropriate, or sampling of abdominal fluid could be considered for cytology. 3-view thoracic radiographs are recommended for full evaluation of metastatic disease, if not recently evaluated. Surgical biopsies could be considered if cytology is non-diagnostic. However, full removal of the visible gross disease is not considered surgically likely.





The information and recommendations provided are based on the images presented by the referring veterinarian/sonographer. No evaluation can be communicated regarding pathology that was not visible in the image/video clips provided.

Thank you for this referral. If the clinical or image interpretation does not parallel your findings or if I can be of any further assistance please contact me.

Beth Johnson, DVM, DACVIM
Beth.Johnson@sonopath.com