

**DATE PRESENTING CLINICAL SIGNS**

5/19/22 Presents for a long term history of chronic vomiting about 1 time per week.

**PATIENT**

Beauregard Headrick

Current Medications: Cerenia inj once 1mg/kg SQ 5/17, Convenia inj once 1mg/kg SQ 5/17, Prednisolone 1mg/kg po SID 5/17. Gabapentin 100mg 2-3 hours prior to scan.

Lab Results: Tbili 1.6 on 5/17.

Date of Previous IntraPet Ultrasound: No previous.

Sedation: Not required to complete full diagnostic ultrasound.

Stat Report: Not requested.

**SPECIES**

Feline

**ULTRASONOGRAPHIC EXAMINATION OF THE ABDOMEN****BREED**

DSH

**Urinary System**

Urinary bladder is moderately distended. It has a normal uniform wall thickness (<0.2 cm). Contents include primarily anechoic fluid combined with suspended echogenic non-shadowing debris within the fluid. No masses or cystoliths are observed. The trigone and visible pelvic urethra are normal in thickness with a smooth mucosal surface.

**SEX**

Neutered Male

The right kidney is normal in size (4.24 cm), shape and echogenicity. It has smooth peripheral margination. There is a normal 1:3 cortex to medulla ratio with appropriate corticomedullary distinction. There is no evidence of pyelectasia, mineral or infarcts observed.

**AGE**

1/16/16

The left kidney is normal in size (3.9 cm), shape and echogenicity. It has smooth peripheral margination. There is a normal 1:3 cortex to medulla ratio with appropriate corticomedullary distinction. There is no evidence of pyelectasia, mineral or infarcts observed.

**WEIGHT**

10.6 Pounds

**Adrenal Glands**

The right adrenal gland is normal in size (0.42 cm thick), shape and contour. Corticomedullary structure is unremarkable. Visible surrounding vasculature appears normal.

The left adrenal gland is normal in size (0.54 cm thick), shape and contour. Corticomedullary structure is unremarkable. Visible surrounding vasculature appears normal.

**INTERPRETED BY**

Beth Johnson, DVM  
DACVIM

**IMAGING PERFORMED BY**

Rachel Brilhart RDMS

**HOSPITAL NAME**

Eastern AH

**Spleen**

The spleen is subjectively normal in size with a normal smooth capsular contour. Parenchyma is appropriately finely textured and homogenous with normal echogenicity relative to surrounding tissue (hyperechoic to liver). No focal nodules or masses are observed. Splenic vasculature appears normal.

**REFERRING VET**

Dr. Haviland

**Liver**

The liver is subjectively normal in size with normal smooth curvilinear peripheral contour. Parenchyma is appropriately hypoechoic to the spleen in echogenicity and appropriately mildly coarse and homogenous in echotexture. No focal lesions are observed. Visible vasculature and biliary tree appear normal without distension or congestion.

**INVOICE**

37791

The gallbladder is non-distended in size. The wall is smooth without visible thickening. Luminal contents are primarily anechoic. There is no evidence of cystic or common bile duct dilation.

**Gastrointestinal**

The stomach wall is normal in thickness (canine < 0.5 cm and feline < 0.4 cm) and layering. The lumen of the stomach is empty with no evidence of obstruction, foreign material or infiltrative disease, except for near the pylorus, where there is a highly reflective, echogenic, granular curved interface with strong acoustic

shadowing. There is no evidence of gastric distention or bowel plication, etc. to indicate a full obstruction. Pyloric outflow tract appears patent.

The visible small intestines are normal in wall thickness and layering (canine duodenum < 0.5 cm and feline duodenum < 0.4 cm; other < 0.3 cm). Small intestinal motility appears adequate (1-3 contractions per min). The lumen of the small intestine is empty with no evidence of obstruction, foreign material or infiltrative disease.

The visible colon is normal in wall thickness (< 0.2 cm) and layering. Contents are consistent with normal formed feces and gas.

### ***Pancreas***

The pancreas is diffusely prominent in size and mildly irregular in shape with a diffusely coarse echotexture and slightly hypoechoic echogenicity. No evidence of surrounding free fluid or hyperechoic mesentery or fat to imply inflammation.

### ***Free Abdomen***

There is no evidence of peritoneal effusion. There is no apparent lymphadenopathy.

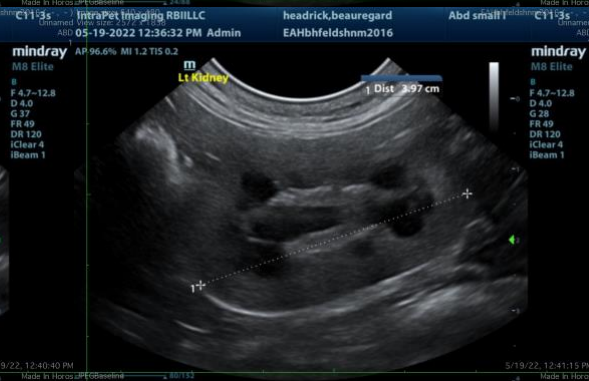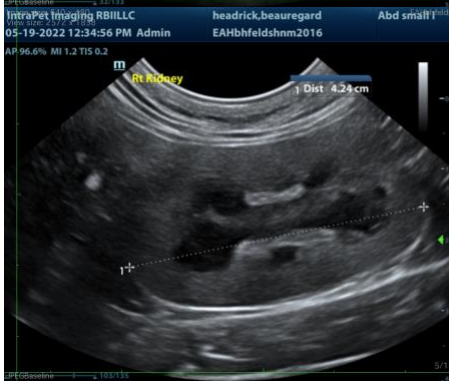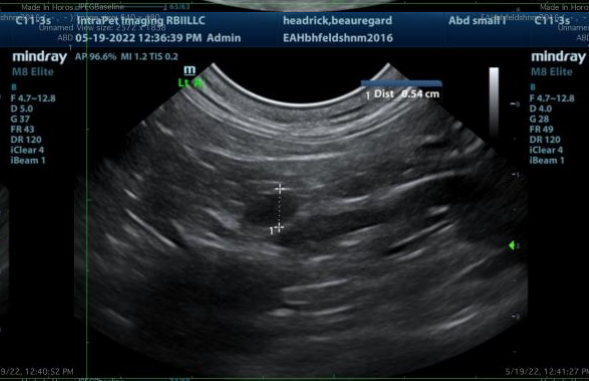
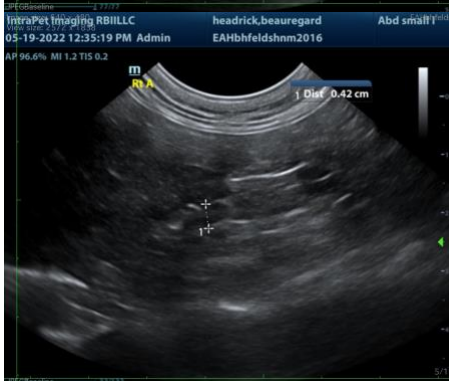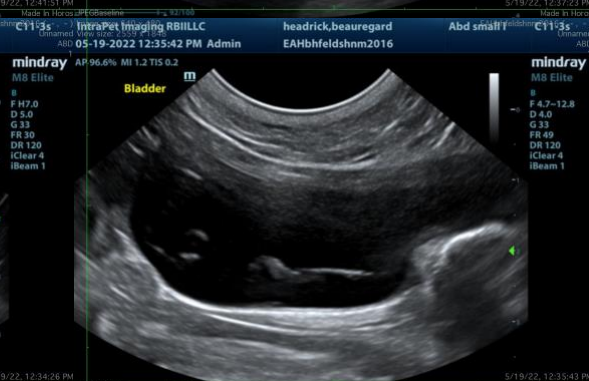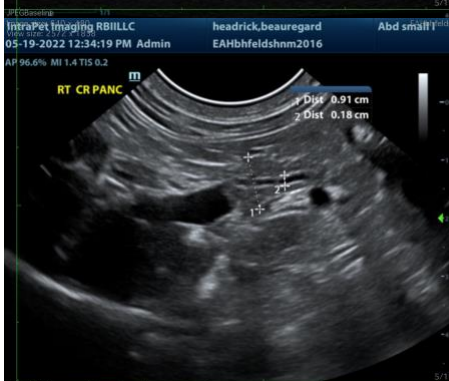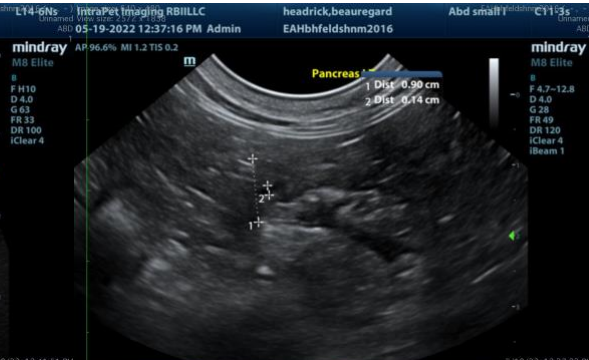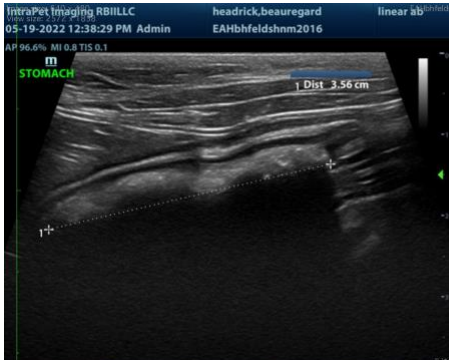## **ULTRASONOGRAPHIC FINDINGS**

- Granular echogenic reflective density within the gastric lumen near the pylorus that produces strong acoustic shadowing – concerning for soft foreign material such as a hairball or cloth-like foreign object. There is no evidence of gastric distention or bowel plication to indicate full obstruction. However, intermittent or partial obstruction cannot be ruled out. Normal ingesta is considered possible, but less likely.
- Prominent, coarse pancreas – Rule outs include normal age related pancreatic remodeling versus chronic pancreatitis. Chronic smoldering pancreatitis cannot be ruled out, given this patient's intermittent vomiting. However, there is no evidence of active acute inflammation ultrasonographically.
- Urinary bladder sediment – Urine changes are most consistent with incidental suspended lipid in a cat, however, cellular debris or crystalluria cannot be ruled out and should be interpreted in combination with urinalysis results.

## **INTERPRETATION OF THE FINDINGS & FURTHER RECOMMENDATIONS**

Recommendations include a urinalysis, and, if indicated based on urinalysis results, a urine culture, given the urinary bladder debris. Other recommends, given the pancreatic changes as well as the chronic gastrointestinal signs, include a gastrointestinal malabsorption panel including TLI, PLI, folate and cobalamin to Texas A&M GI laboratory.

Pending results, recommendations include management of possible pancreatitis/gastroenteritis with supportive medical care and close monitoring of the gastric contents. If the density remains present with prolonged fasting, and clinical signs persist, surgical exploratory gastrotomy or endoscopic gastroscopy are recommended for further evaluation and removal of the suspected foreign material. If no foreign material is present, biopsies should be obtained at that time.



**The information and recommendations provided are based on the images presented by the referring veterinarian/sonographer. No evaluation can be communicated regarding pathology that was not visible in the image/video clips provided.**

Thank you for this referral. If the clinical or image interpretation does not parallel your findings or if I can be of any further assistance please contact me.

**Beth Johnson, DVM, DACVIM**  
Beth.Johnson@sonopath.com