



PATIENT

Fiona Hull

SPECIES

Feline

BREED

DSH

SEX

Spayed Female

AGE

11 Years 6 Months

WEIGHT

5.29 kgs

INTERPRETED BY

Beth Johnson, DVM
DACVIM

IMAGING PERFORMED BY

Renee Trionfetti, VMD

HOSPITAL NAME

Firefly UC

REFERRING VET

Gina Watzka, DVM

INVOICE

37137

DATE

5/18/26

PRESENTING CLINICAL SIGNS

History: AUS to further evaluate weight loss (about 2 lbs in 8 mos), despite a good appetite and intermittent vomiting. Hx of FHO in 2020 otherwise has been healthy.

Abnormal PE/Chem/CBC/UA Results: CBC/CHEM/T4 - normal. Whole body rads - unremarkable.

ULTRASONOGRAPHIC EXAMINATION OF THE ABDOMEN

Urinary System

Urinary bladder is adequately distended with anechoic contents. No masses, inflammatory changes, echogenic sediment or cystoliths are observed. The urinary bladder, trigone and visible pelvic urethra are normal in thickness with a smooth mucosal surface.

Kidneys are bilaterally irregular and diffusely echogenic with decreased corticomedullary distinction and poor visualization of internal architecture. There is no pyelectasia noted and no mineral is observed. The left kidney is small/normal in size, measuring 3.49 cm. The right kidney is small, measuring 3.15 cm.

Adrenal Glands

Left adrenal gland is normal in size (0.2 cm at cranial pole and 0.3 cm at caudal pole), shape and overall architecture, echogenicity and echotexture. Visible surrounding vasculature appears normal.

Right adrenal gland is normal in size (0.2 cm at cranial pole and 0.3 cm at caudal pole), shape and overall architecture, echogenicity and echotexture. Visible surrounding vasculature appears normal.

Spleen

Spleen is subjectively normal in size with a normal smooth capsular contour. Parenchyma is appropriately finely textured and homogenous with normal echogenicity relative to surrounding tissue (hyperechoic to liver). No focal nodules or masses are observed. Splenic vasculature appears normal.

Liver

Liver is subjectively normal in size with normal smooth curvilinear peripheral contour. Parenchyma is appropriately hypoechoic to the spleen in echogenicity and appropriately mildly coarse and homogenous in echotexture. No focal lesions are observed. Visible vasculature and biliary tree appear normal without distension or congestion.

Gallbladder is non-distended in size. The wall is smooth without visible thickening. Luminal contents are primarily anechoic. There is no evidence of cystic or common bile duct dilation.

Gastrointestinal

The visible stomach wall is normal in thickness and layering. The lumen of the stomach is empty with no evidence of obstruction, foreign material or infiltrative disease. Pyloric outflow tract appears patent.

The visible small intestine demonstrates areas of moderate to severely thick muscularis layer relative to mucosa (disruption of the normal 1:3 muscularis:mucosa ratio). Small intestinal submucosa is slightly



PATIENT

Fiona Hull

SPECIES

Feline

BREED

DSH

SEX

Spayed Female

AGE

11 Years 6 Months

WEIGHT

5.29 kgs

INTERPRETED BY

Beth Johnson, DVM
DACVIM

IMAGING PERFORMED BY

Renee Trionfetti, VMD

HOSPITAL NAME

Firefly UC

REFERRING VET

Gina Watzka, DVM

INVOICE

37137

DATE

5/18/26

irregular, thick and hyperechoic, without evident loss of layering appreciated. The lumen of the small intestine is empty with no evidence of obstruction or foreign material.

The visible colon is normal in wall thickness (< 0.2 cm) and layering. Contents are consistent with normal formed feces and gas.

Pancreas

Pancreas is prominent (enlarged) in size, hypoechoic to surrounding tissue and has a mildly irregular undulating contour. Parenchyma is coarse with mixed echogenic remodeling noted. No pancreatic duct dilation is noted.

Free Abdomen

There is no visible free peritoneal effusion noted in these images.

The mesenteric lymph nodes are prominent in size with swollen capsular contour. Normal elongated shape (length to width ratio) is maintained. There is no loss of parenchymal detail.

ULTRASONOGRAPHIC FINDINGS

- Moderate inflammatory bowel disease pattern- Thick muscularis has been reported with infiltrative bowel disease including both benign inflammatory disease as well as infiltrative neoplasia such as lymphoma. No loss of layering or distinct characteristics of malignancy are present. Therefore, differentials cannot be further ranked without tissue sampling.
- Concurrent chronic low grade smoldering pancreatitis can't be ruled out and should be suspected in the face of appropriate clinical signs.
- Very mildly reactive mesenteric lymphadenopathy- infiltrative neoplastic disease cannot be ruled out but is considered less likely.
- Mild bilateral kidney disease changes, most visibly significant in the right kidney.

INTERPRETATION OF THE FINDINGS & FURTHER RECOMMENDATIONS

- If not recently evaluated, a urinalysis, and if indicated based on urinalysis results, urine culture is recommended. If protein is present in an otherwise quiet sediment, protein quantification with a urine protein to creatinine ration is recommended.
- A gastrointestinal malabsorption panel (including cobalamin, folate, TLI and PLI) to Texas A&M GI Laboratory is recommended for further evaluation of GI and pancreatic function.
- Ideally, biopsies of the GI tract, being sure to include ileum, if possible, are recommended to definitively diagnose and therefore manage the infiltrative bowel disease.
- If biopsies cannot be obtained, empirical therapies could include a probiotic (if diarrhea is present, such as visbiome or proviable), empirical deworming with a 5-day course of Panacur and, if tolerated, a transition in diet, based on trial-and-error response, beginning with a hydrolyzed protein diet. Some patients respond to one brand/version of a hydrolyzed protein diet better than another brand, so several trials may be required.
- Additional considerations could include cobalamin supplementation (unless cobalamin level is



PATIENT

Fiona Hull

SPECIES

Feline

BREED

DSH

SEX

Spayed Female

AGE

11 Years 6 Months

WEIGHT

5.29 kgs

INTERPRETED BY

Beth Johnson, DVM
DACVIM

IMAGING PERFORMED BY

Renee Trionfetti, VMD

HOSPITAL NAME

Firefly UC

REFERRING VET

Gina Watzka, DVM

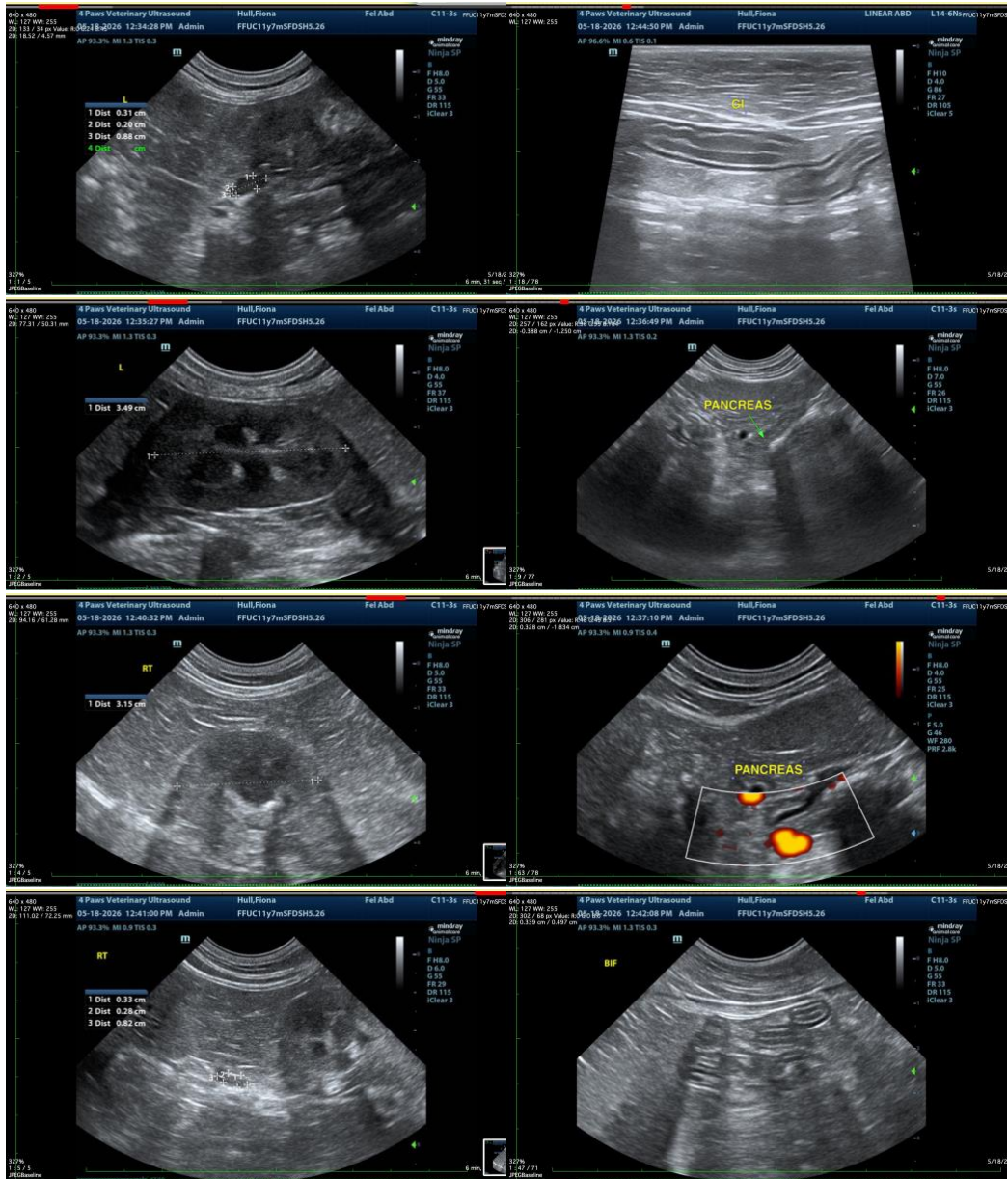
INVOICE

37137

DATE

5/18/26

evaluated and supplementation is not warranted) and prednisolone (if not contraindicated based on patient contraindications, co-morbidities, etc.).



The information and recommendations provided are based on the images presented by the referring veterinarian/sonographer. No evaluation can be communicated regarding pathology that was not visible in the image/video clips provided.

Thank you for this referral. If the clinical or image interpretation does not parallel your findings or if I can be of any further assistance please contact me.

Beth Johnson, DVM DACVIM



PATIENT

info@sonopath.com

Fiona Hull

SPECIES

Feline

BREED

DSH

SEX

Spayed Female

AGE

11 Years 6 Months

WEIGHT

5.29 kgs

INTERPRETED BY

Beth Johnson, DVM
DACVIM

**IMAGING
PERFORMED BY**

Renee Trionfetti, VMD

HOSPITAL NAME

Firefly UC

REFERRING VET

Gina Watzka, DVM

INVOICE

37137

DATE

5/18/26