



|                                |   |
|--------------------------------|---|
| <b>PATIENT</b>                 | <b>PRESENTING CLINICAL SIGNS</b>  |
| Lewis Chalaturnyk              | Acute weight loss over the last two months, recently diagnosed stage 2 kidney disease. Vomiting has increased in frequency over the last month to every 2-3 days. It was previously only occasional (e.g., furballs). The vomitus is described as mixed, sometimes a large volume of water after drinking, and sometimes containing undigested kibble. Appetite is reported as normal. Stool is softer than normal, but the patient is observed straining to defecate. Urination is reported as normal. Royal Canin Urinary SO dry food diet. This was started as a general wellness measure for an older cat, not for a history of urinary issues. |
| <b>SPECIES</b>                 |   |
| Feline                         |   |
| <b>BREED</b>                   |   |
| DSH                            |   |
| <b>SEX</b>                     | Abnormal PE/Chem/CBC/UA Results: Light brown loose diarrhea defecated during AUS, no blood or mucous - thin BCS, topline muscle wasting - missing most teeth BW from 5/12/26 HCT 37% mild neutrophilia (11.2, normal 2.3-10.29) UA: usg 1.020, inactive sediment Glc 9.16 (3.95-8.84) SDMA 21 (0-14) BUN 15.1 (5.7-12.9) Creat normal @ 165 (71-212) GGT 11 (0-4) rest of chem WNL TT4 normal at 24 (10-60)   |
| Neutered Male                  |   |
| <b>AGE</b>                     | <b>ULTRASONOGRAPHIC EXAMINATION OF THE ABDOMEN</b>  |
| 17 Years                       | <b>Urinary System</b>   |
| <b>WEIGHT</b>                  | Urinary bladder is adequately distended. It has a normal uniform wall thickness. Contents include primarily anechoic fluid with occasional echogenic non-shadowing debris, most consistent with incidental suspended lipid in a cat, possibly combined with exfoliated cells, mucous and/or small blood clots. Both sterile inflammation as well as urinary tract infection can also present with echogenic debris. No masses or definitive cystoliths are observed. The trigone and visible pelvic urethra are normal in thickness with a smooth mucosal surface.  |
| <b>INTERPRETED BY</b>          | Kidneys are bilaterally irregular and diffusely echogenic with decreased corticomedullary distinction and poor visualization of internal architecture. No mineral is observed. The left kidney is normal in size, measuring 3.9 cm. The right kidney is small-normal in size measuring 3.3 cm. Mild pyelectasia is noted bilaterally.   |
| Beth Johnson, DVM<br>DACVIM    | <b>Adrenal Glands</b>   |
| <b>IMAGING PERFORMED BY</b>    | The right adrenal gland is normal in size (0.40 cm), shape and overall architecture, echogenicity and echotexture. Visible surrounding vasculature appears normal.  |
| Dr. Goeres                     | The area of the left adrenal gland is examined without evident adrenal gland pathology.   |
| <b>HOSPITAL NAME</b>           | <b>Spleen</b>   |
| Kelowna Veterinary<br>Hospital | The spleen is subjectively normal in size with a normal smooth capsular contour. Parenchyma is appropriately finely textured and homogenous with normal echogenicity relative to surrounding tissue (hyperechoic to liver). No focal nodules or masses are observed. Splenic vasculature appears normal.  |
| <b>REFERRING VET</b>           | <b>Liver</b>  |
| Dr. Koo                        | Liver is subjectively enlarged (swollen contour). Mild parenchymal remodeling with diffusely mildly coarse architecture and increased portal markings is present. No focal nodules or masses are observed. Visible vasculature and biliary tree appear normal without distension or congestion.   |
| <b>INVOICE</b>                 |   |
| 75162                          |   |
| <b>DATE</b>                    |   |
| 5/14/26                        |   |



## PATIENT

Lewis Chalaturnyk

## SPECIES

Feline

## BREED

DSH

## SEX

Neutered Male

## AGE

17 Years

## WEIGHT

3 kg

## INTERPRETED BY

Beth Johnson, DVM  
DACVIM

## IMAGING PERFORMED BY

Dr. Goeres

## HOSPITAL NAME

Kelowna Veterinary  
Hospital

## REFERRING VET

Dr. Koo

## INVOICE

75162

## DATE

5/14/26

The gallbladder is non-distended in size. The wall is smooth without visible thickening. Luminal contents are primarily anechoic. There is no evidence of cystic or common bile duct dilation.

### ***Gastrointestinal***

The visible stomach wall is normal in thickness and layering. The lumen of the stomach is empty with no evidence of obstruction, foreign material or infiltrative disease. Pyloric outflow tract appears patent.

The visible small intestine demonstrates areas of markedly/significantly thick muscularis layer relative to mucosa (disruption of the normal 1:3 muscularis:mucosa ratio). Small intestinal submucosa is slightly irregular, thick and hyperechoic, without evident loss of layering appreciated. The lumen of the small intestine is empty with no evidence of obstruction or foreign material.

The visible colon is normal in wall thickness (< 0.2 cm) and layering. Contents are consistent with normal formed feces and gas.

### ***Pancreas***

The pancreas that is observed appears appropriately isoechoic to surrounding omental fat. Visible capsule is smooth and normal in contour. Visible pancreatic parenchyma is homogenous and unremarkable. There is no visible pancreatic duct dilation. There is no evidence of active peripancreatic inflammation.

### ***Free Abdomen***

There is no visible free peritoneal effusion noted in these images.

Mesenteric and colic lymph nodes are enlarged with swollen irregular capsular contour and loss of normal length to width ratio (rounded in shape). Nodes are hypoechoic with loss of normal parenchymal detail.

## **ULTRASONOGRAPHIC FINDINGS**

- Marked/significant inflammatory bowel disease (IBD) pattern – Thick muscularis has been reported with infiltrative bowel disease including both benign inflammatory disease as well as infiltrative neoplasia such as lymphoma. No loss of layering or distinct characteristics of malignancy are present. Therefore, differentials cannot be further ranked without tissue sampling.
- Hypoechoic hepatomegaly – This appearance is consistent with an acute hepatopathy or acute cholangiohepatitis. Infiltrative neoplasia (round cell neoplasia) should also be considered.
- Aggressive mesenteric and caudal abdominal/colic lymph nodes – concerning for infiltrative round cell or metastatic neoplasia. A benign aggressive inflammatory response cannot be ruled out without tissue sampling +/- culture.
- Mild bilateral chronic kidney disease changes with mild bilateral pyelectasia.
- Mild amount of echogenic urinary bladder debris.



**PATIENT**

Lewis Chalaturnyk

**SPECIES**

Feline

**BREED**

DSH

**SEX**

Neutered Male

**AGE**

17 Years

**WEIGHT**

3 kg

**INTERPRETED BY**

Beth Johnson, DVM  
DACVIM

**IMAGING PERFORMED BY**

Dr. Goeres

**HOSPITAL NAME**

Kelowna Veterinary  
Hospital

**REFERRING VET**

Dr. Koo

**INVOICE**

75162

**DATE**

5/14/26

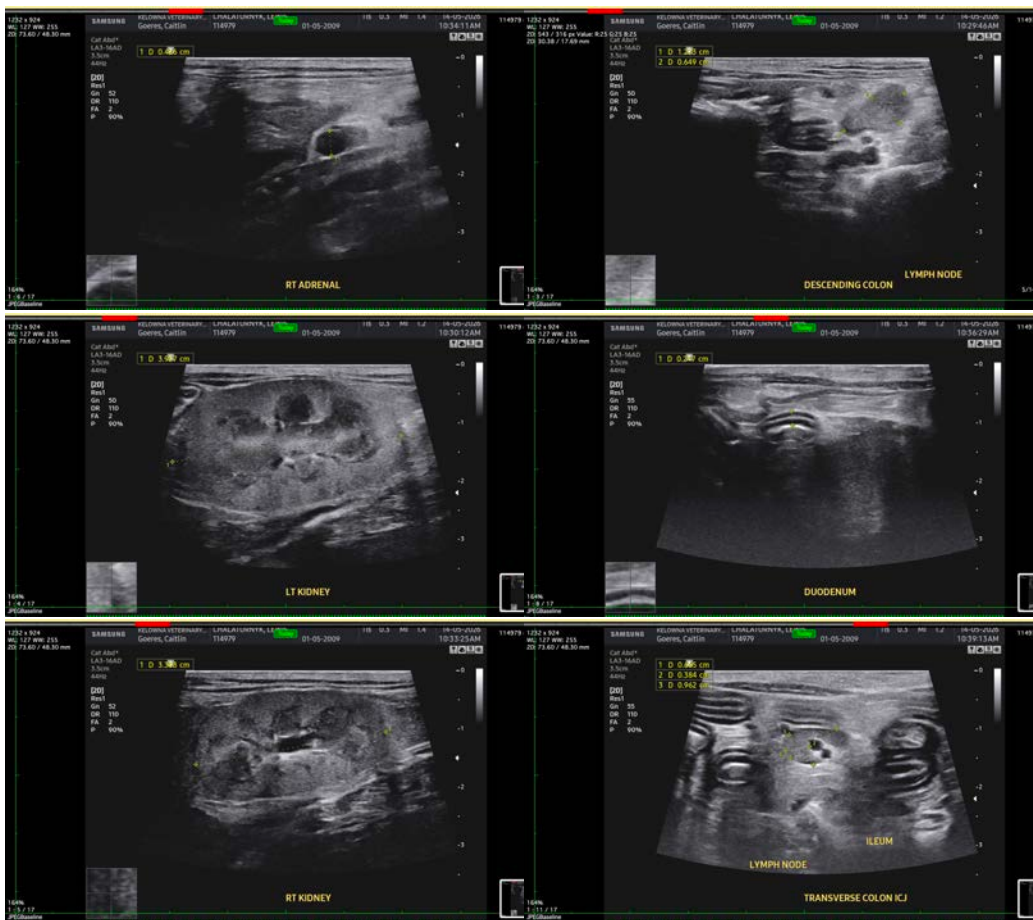
**INTERPRETATION OF THE FINDINGS & FURTHER RECOMMENDATIONS**

As is reportedly already pending, fine needle aspirates of the lymph nodes could be considered if patient's coagulation status is appropriate. Additionally, fine needle aspirates of the liver could be considered.

A gastrointestinal malabsorption panel (including cobalamin, folate, TLI and PLI) to Texas A&M GI Laboratory is recommended for further evaluation of GI and pancreatic function.

If a cytologic diagnosis is unable to be obtained, ultimately biopsies of the GI tract may be necessary for definitive diagnosis and to further guide medical management.

Other than supportive/symptomatic medical management of clinical signs, further treatment recommendations are largely dependent on results of the above.





## PATIENT

Lewis Chalaturnyk

## SPECIES

Feline

## BREED

DSH

## SEX

Neutered Male

## AGE

17 Years

## WEIGHT

3 kg

## INTERPRETED BY

Beth Johnson, DVM  
DACVIM

## IMAGING PERFORMED BY

Dr. Goeres

## HOSPITAL NAME

Kelowna Veterinary  
Hospital

## REFERRING VET

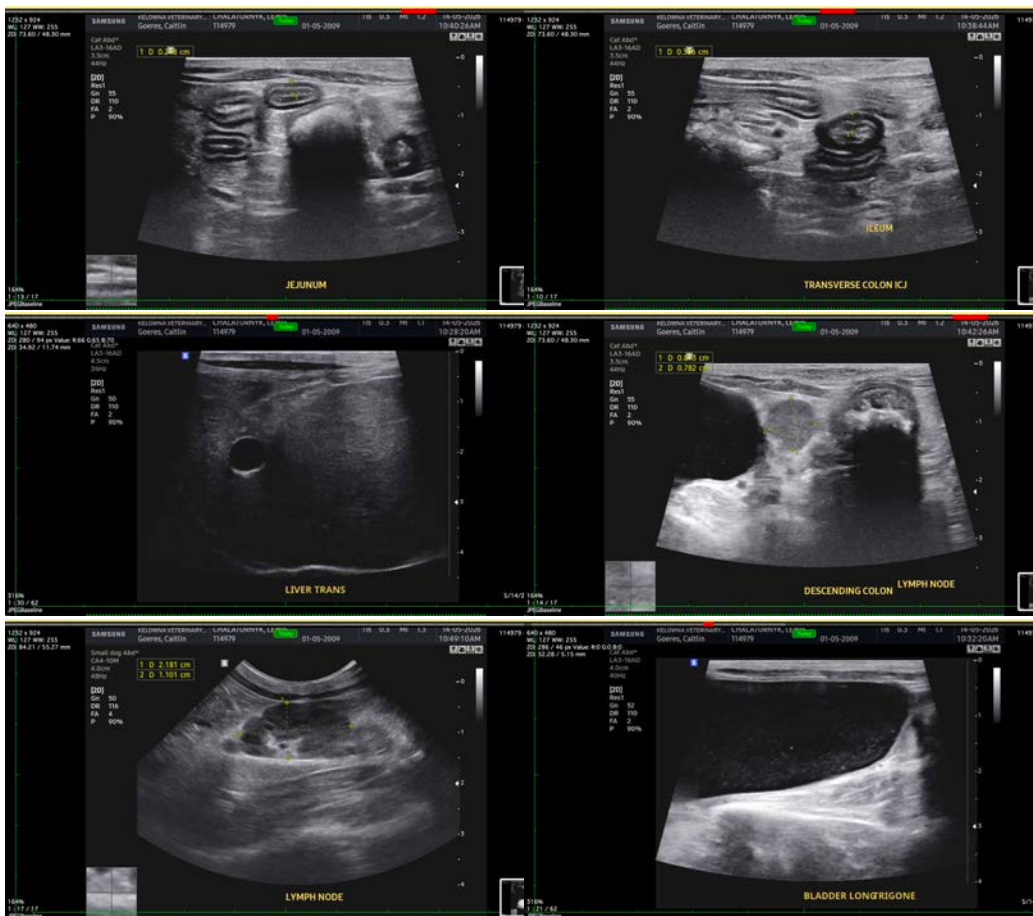
Dr. Koo

## INVOICE

75162

## DATE

5/14/26



The information and recommendations provided are based on the images presented by the referring veterinarian/sonographer. No evaluation can be communicated regarding pathology that was not visible in the image/video clips provided.

Thank you for this referral. If the clinical or image interpretation does not parallel your findings or if I can be of any further assistance please contact me.

**Beth Johnson, DVM, DACVIM**  
info@sonopath.com