



PATIENT

Dakota Wald

SPECIES

Canine

BREED

Red Heeler

SEX

Male

AGE

4 Years 2 Months

WEIGHT

49.6

INTERPRETED BY

Beth Johnson, DVM
DACVIM

IMAGING PERFORMED BY

Carissa Hayden

HOSPITAL NAME

Elizabeth Animal
Hospital

REFERRING VET

Kim Allyn, DVM

INVOICE

75137

DATE

5/14/26

PRESENTING CLINICAL SIGNS

No diarrhea reported. No missing toys at this time. Previous episodes of vomiting occurred in April and once between then and now, but these resolved quickly. Last night, Dakota was normal and active, playing ball until bedtime. Vomiting began overnight, with the owner noting Dakota was uncomfortable and unable to get comfortable, constantly moving around. No abnormal material noted in the vomitus, only dog food. No increased grass ingestion reported. Owner reports Dakota drank water before leaving home and was able to keep it down.

Abnormal PE/Chem/CBC/UA Results: PE: Exam was normal Blood Work all looked great from April

ULTRASONOGRAPHIC EXAMINATION OF THE ABDOMEN

Urinary System

The urinary bladder is adequately distended with anechoic contents. No masses, inflammatory changes, echogenic sediment or cystoliths are observed. The urinary bladder, trigone and visible pelvic urethra are normal in thickness with a smooth mucosal surface.

Prostate is normal in size for an intact male. Parenchyma is diffusely homogenous and relatively hyperechoic. Normal distinct margins and symmetrical bilobed shape are maintained.

The right kidney is normal in size (5.99 cm), shape and echogenicity. It has smooth peripheral margination. There is a normal 1:3 cortex to medulla ratio with appropriate corticomedullary distinction. There is no evidence of pyelectasia, mineral or infarcts observed.

The left kidney is normal in size (6.36 cm), shape and echogenicity. It has smooth peripheral margination. There is a normal 1:3 cortex to medulla ratio with appropriate corticomedullary distinction. There is no evidence of pyelectasia, mineral or infarcts observed.

Adrenal Glands

The right adrenal gland is normal in size (0.43 cm at cranial pole and 0.54 cm at caudal pole), shape and overall architecture, echogenicity and echotexture. Visible surrounding vasculature appears normal.

The left adrenal gland is normal in size (0.43 cm at cranial pole and 0.58 cm at caudal pole), shape and overall architecture, echogenicity and echotexture. Visible surrounding vasculature appears normal.

Spleen

The spleen is subjectively normal in size with a normal smooth capsular contour. Parenchyma is appropriately finely textured and homogenous with normal echogenicity relative to surrounding tissue (hyperechoic to liver). No focal nodules or masses are observed. Splenic vasculature appears normal.

Liver

The liver is subjectively normal in size with normal smooth curvilinear peripheral contour. Parenchyma is appropriately hypoechoic to the spleen in echogenicity and appropriately mildly coarse and homogenous in echotexture. No focal lesions are observed. Visible vasculature and biliary tree appear normal without distension or congestion.

The gallbladder is non-distended in size. The wall is smooth without visible thickening. Luminal contents are primarily anechoic. There is no evidence of cystic or common bile duct dilation.



PATIENT

Dakota Wald

SPECIES

Canine

BREED

Red Heeler

SEX

Male

AGE

4 Years 2 Months

WEIGHT

49.6

INTERPRETED BY

Beth Johnson, DVM
DACVIM

IMAGING PERFORMED BY

Carissa Hayden

HOSPITAL NAME

Elizabeth Animal
Hospital

REFERRING VET

Kim Allyn, DVM

INVOICE

75137

DATE

5/14/26

Gastrointestinal

The visible stomach wall is normal in thickness and layering. The lumen of the stomach is moderately to markedly distended with fluid. The pylorus is mildly fluid distended. There is no visible evidence of foreign material, shadowing, or an obstructive cause.

The visible small intestines are normal in wall thickness and layering. Small intestinal motility appears adequate (1-3 contractions per min). The lumen of the small intestine is mildly distended with very echogenic reverberation artifact from intraluminal gas. There is no evidence of obstruction, foreign material, or infiltrative disease; however, visualization is partially inhibited by gas. In some views shadowing is slightly concerning for shadowing that could be associated with foreign material, but gas and colonic contents are overlying small bowel and making it difficult to distinguish from the shadowing that would be seen with foreign material.

The visible colon is normal in wall thickness (< 0.2 cm) and layering. Contents are consistent with normal formed feces and gas.

Pancreas

The pancreas that is observed appears appropriately isoechoic to surrounding omental fat. Visible capsule is smooth and normal in contour. Visible pancreatic parenchyma is homogenous and unremarkable. There is no visible pancreatic duct dilation. There is no evidence of active peripancreatic inflammation.

Free Abdomen

There is no visible free peritoneal effusion noted in these images.

There is no apparent pathologic lymphadenopathy noted in these images.

ULTRASONOGRAPHIC FINDINGS

- A proximal small bowel i.e., proximal duodenal obstruction could result in the gastric distention described, and given the shadowing from gas and overlying colon throughout the images, foreign material and a partial or emerging early obstruction can't be ruled out, but there is no definitively visible foreign material or definitive shadowing associated with foreign material noted in these images at this time.

INTERPRETATION OF THE FINDINGS & FURTHER RECOMMENDATIONS

If supportive/symptomatic medical management of patient's reported acute vomiting does not result in improvement of clinical signs, an additional 12-24 hours of fasting followed by recheck imaging and/or potentially alternative imaging such as contrast radiography versus other is recommended.

In the meantime, passage of a nasogastric tube to alleviate the fluid distention of the stomach may offer some comfort.



PATIENT

Dakota Wald

SPECIES

Canine

BREED

Red Heeler

SEX

Male

AGE

4 Years 2 Months

WEIGHT

49.6

INTERPRETED BY

Beth Johnson, DVM
DACVIM

IMAGING PERFORMED BY

Carissa Hayden

HOSPITAL NAME

Elizabeth Animal Hospital

REFERRING VET

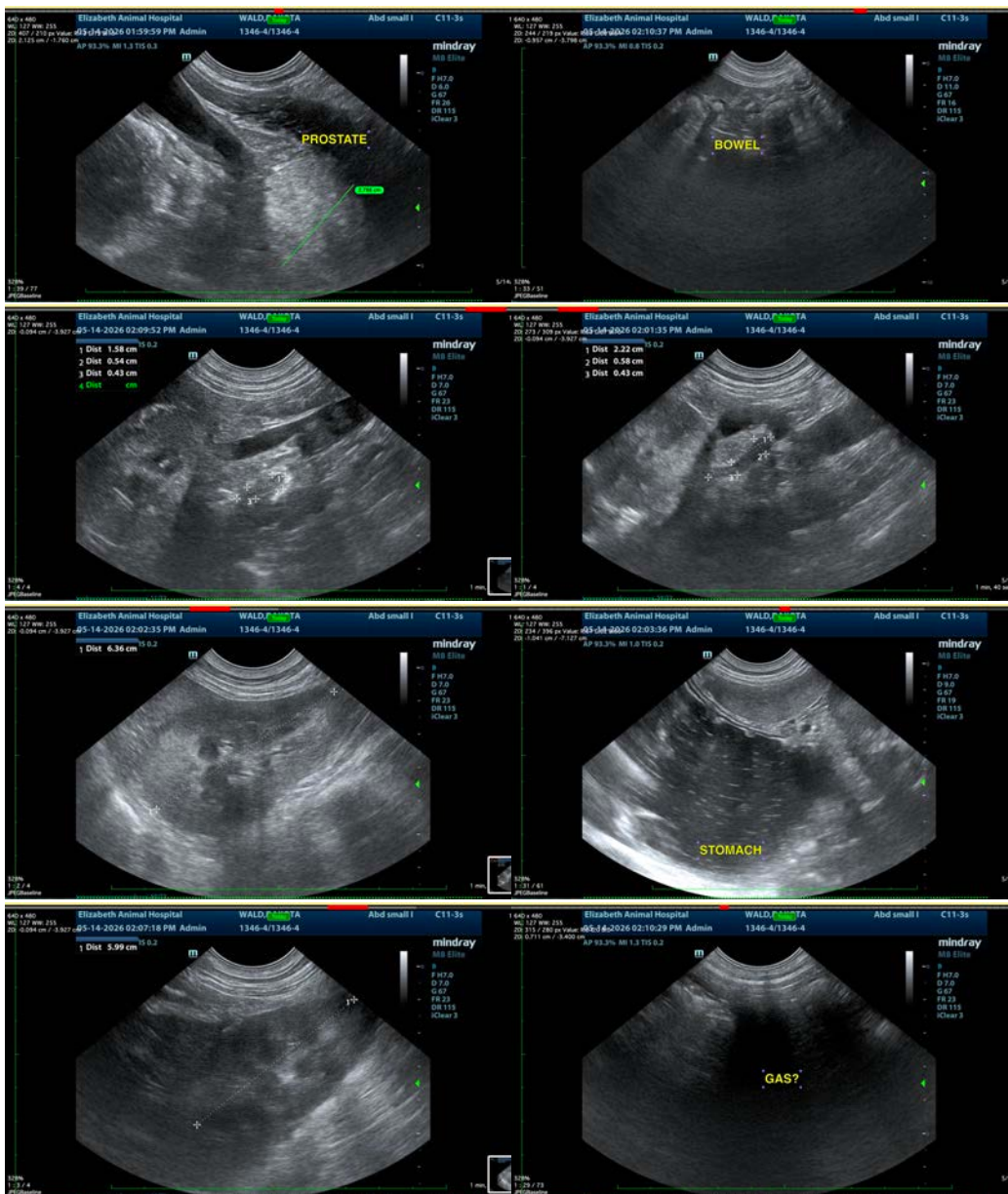
Kim Allyn, DVM

INVOICE

75137

DATE

5/14/26



The information and recommendations provided are based on the images presented by the referring veterinarian/sonographer. No evaluation can be communicated regarding pathology that was not visible in the image/video clips provided.

Thank you for this referral. If the clinical or image interpretation does not parallel your findings or if I can be of any further assistance please contact me.

Beth Johnson, DVM, DACVIM
info@sonopath.com