



PATIENT

Addie Vareka

SPECIES

Canine

BREED

Pit Bull x

SEX

Spayed Female

AGE

5 Years 8 Months

WEIGHT

43 lbs

INTERPRETED BY

Beth Johnson, DVM
DACVIM

IMAGING PERFORMED BY

Mary Kermendy, CVT

HOSPITAL NAME

Wauwatosa Veterinary
Clinic

REFERRING VET

Dr. Elaine Binor

INVOICE

75151

DATE

5/14/26

PRESENTING CLINICAL SIGNS

History of food sensitivity to chicken for years. Currently on a beef based diet. Had a previous episode of vomiting and diarrhea on 2-26-26, which resolved and she was doing well. Owner is currently out of town and caregiver was instructed to use peanut butter treats to administer medications (Rimadyl and Fluoxetine). Shortly after using the peanut butter treats Allie started vomiting and having loose stool with hematochezia. Previous Cortisol level was low normal at 2.3. ACTH is pending. Abdominal imaging to check for GI infiltrative disease such as IBD or GI neoplasia. Treated with SQ fluids, B12, Cerenia, probiotics, a bland diet, and metronidazole.

ULTRASONOGRAPHIC EXAMINATION OF THE ABDOMEN

Urinary System

The urinary bladder is adequately distended with anechoic contents. No masses, inflammatory changes, echogenic sediment or cystoliths are observed. The urinary bladder, trigone and visible pelvic urethra are normal in thickness with a smooth mucosal surface.

The right kidney is normal is size (5.9 cm), shape and echogenicity. It has smooth peripheral margination. There is a normal 1:3 cortex to medulla ratio with appropriate corticomedullary distinction. There is no evidence of pyelectasia, mineral or infarcts observed. A subtle hyperechoic band parallel to the corticomedullary border is present.

The left kidney is normal is size (4.8 cm), shape and echogenicity. It has smooth peripheral margination. There is a normal 1:3 cortex to medulla ratio with appropriate corticomedullary distinction. There is no evidence of pyelectasia, mineral or infarcts observed. A subtle hyperechoic band parallel to the corticomedullary border is present.

Adrenal Glands

The area of the right adrenal gland is examined without evident adrenal gland pathology.

The left adrenal gland is normal in size (0.49 cm at cranial pole and 0.48 cm at caudal pole), shape and overall architecture, echogenicity and echotexture. Visible surrounding vasculature appears normal.

Spleen

Spleen is subjectively large in size (2.2 cm thick at the hilus) with normal smooth margins. Parenchyma is normal in echogenicity with a diffusely coarse/heterogenous echotexture. No discrete sizable focal nodules or masses are observed. Splenic vasculature appears normal.

Liver

The liver is subjectively normal in size with normal smooth curvilinear peripheral contour. Parenchyma is appropriately hypoechoic to the spleen in echogenicity and appropriately mildly coarse and homogenous in echotexture. No focal lesions are observed. Visible vasculature and biliary tree appear normal without distension or congestion.

The gallbladder is non-distended in size. The wall is smooth without visible thickening. Luminal contents are primarily anechoic. There is no evidence of cystic or common bile duct dilation.



PATIENT

Addie Vareka

SPECIES

Canine

BREED

Pit Bull x

SEX

Spayed Female

AGE

5 Years 8 Months

WEIGHT

43 lbs

INTERPRETED BY

Beth Johnson, DVM
DACVIM

IMAGING PERFORMED BY

Mary Kermendy, CVT

HOSPITAL NAME

Wauwatosa Veterinary
Clinic

REFERRING VET

Dr. Elaine Binor

INVOICE

75151

DATE

5/14/26

Gastrointestinal

The visible stomach wall is normal in thickness and layering. The lumen of the stomach is empty with no evidence of obstruction, foreign material or infiltrative disease. Pyloric outflow tract appears patent.

The visible small intestine demonstrates areas of moderately thick muscularis layer relative to mucosa (disruption of the normal 1:3 muscularis:mucosa ratio). Small intestinal submucosa is slightly irregular, thick and hyperechoic, without evident loss of layering appreciated. The lumen of the small intestine is empty with no evidence of obstruction or foreign material.

The visible colon is normal in wall thickness (< 0.2 cm) and layering. The lumen is diffusely mildly to moderately distended with soft stool.

Pancreas

The pancreas that is observed appears appropriately isoechoic to surrounding omental fat. Visible capsule is smooth and normal in contour. Visible pancreatic parenchyma is homogenous and unremarkable. There is no visible pancreatic duct dilation. There is no evidence of active peripancreatic inflammation.

Free Abdomen

There is no visible free peritoneal effusion noted in these images.

There is no apparent pathologic lymphadenopathy noted in these images.

ULTRASONOGRAPHIC FINDINGS

- Moderate inflammatory bowel disease (IBD) pattern – Thick muscularis has been reported with infiltrative bowel disease including both benign inflammatory disease as well as infiltrative neoplasia such as lymphoma. No loss of layering or distinct characteristics of malignancy are present. Therefore, differentials cannot be further ranked without tissue sampling.
- Mildly/subtly coarse splenomegaly – can be associated with congestion caused by sedation (if sedated) but can also be associated with diffuse infiltrative disease. Both benign conditions such as extramedullary hematopoiesis, lymphoid hyperplasia, as well as infiltrative neoplastic diseases such as round cell neoplasia should be considered.
- Subtle/mild bilateral medullary rim sign - This finding is of unknown clinical significance and can be a normal variant, often idiopathic. Medullary rim sign can be present with renal disease including lymphoma, hypercalcemic nephropathy, Leptospirosis, tubular disease, other and should be interpreted in combination with other more specific indications of kidney disease such as isosthenuria, proteinuria, azotemia, etc. This is a common incidental finding in patients with diabetes mellitus.

INTERPRETATION OF THE FINDINGS & FURTHER RECOMMENDATIONS

A routine fecal/giardia exam could be considered if not recently evaluated.

A gastrointestinal malabsorption panel (including cobalamin, folate, TLI and PLI) to Texas A&M GI Laboratory is recommended for further evaluation of GI and pancreatic function.



PATIENT

Addie Vareka

SPECIES

Canine

BREED

Pit Bull x

SEX

Spayed Female

AGE

5 Years 8 Months

WEIGHT

43 lbs

INTERPRETED BY

Beth Johnson, DVM
DACVIM

IMAGING PERFORMED BY

Mary Kermendy, CVT

HOSPITAL NAME

Wauwatosa Veterinary
Clinic

REFERRING VET

Dr. Elaine Binor

INVOICE

75151

DATE

5/14/26

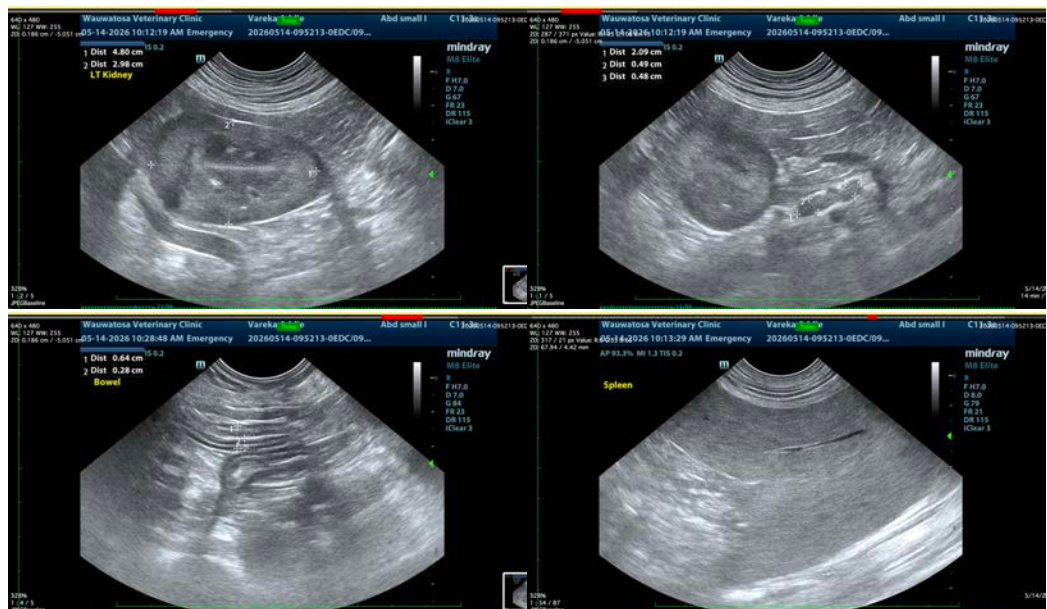
A fecal enteropathogen PCR panel to Texas A&M GI Laboratory could be considered for further evaluation of possible infectious disease. Contact lab for recommendations on how long to discontinue antibiotics (if indicated) prior to obtaining a stool sample for submission.

As is reportedly already pending, based on baseline cortisol results a full ACTH stimulation test is recommended.

In the meantime:

- Supportive/symptomatic medical management of clinical signs is recommended, including anti-emetics, gastroprotectants (+/- sucralfate, especially with any history of hematemesis), an appetite stimulant and fluid therapy if indicated, etc.
- Additionally, empirical deworming with a 5-day course of Panacur is recommended.
- A full course of empirical Helicobacter triple therapy could be considered.
- A probiotic, such a visbiome or proviable, may be helpful.
- Finally, if tolerated, a transition in diet could be considered, based on trial-and-error response with some options to consider including a gastrointestinal biome diet vs a hydrolyzed protein diet (sometimes several trials with different brands are necessary) vs an easy to digest, bland or low-fat diet vs other.

Fecal microbe transplant therapy could also be considered.





PATIENT

Addie Vareka

SPECIES

Canine

BREED

Pit Bull x

SEX

Spayed Female

AGE

5 Years 8 Months

WEIGHT

43 lbs

INTERPRETED BY

Beth Johnson, DVM
DACVIM

IMAGING PERFORMED BY

Mary Kermendy, CVT

HOSPITAL NAME

Wauwatosa Veterinary
Clinic

REFERRING VET

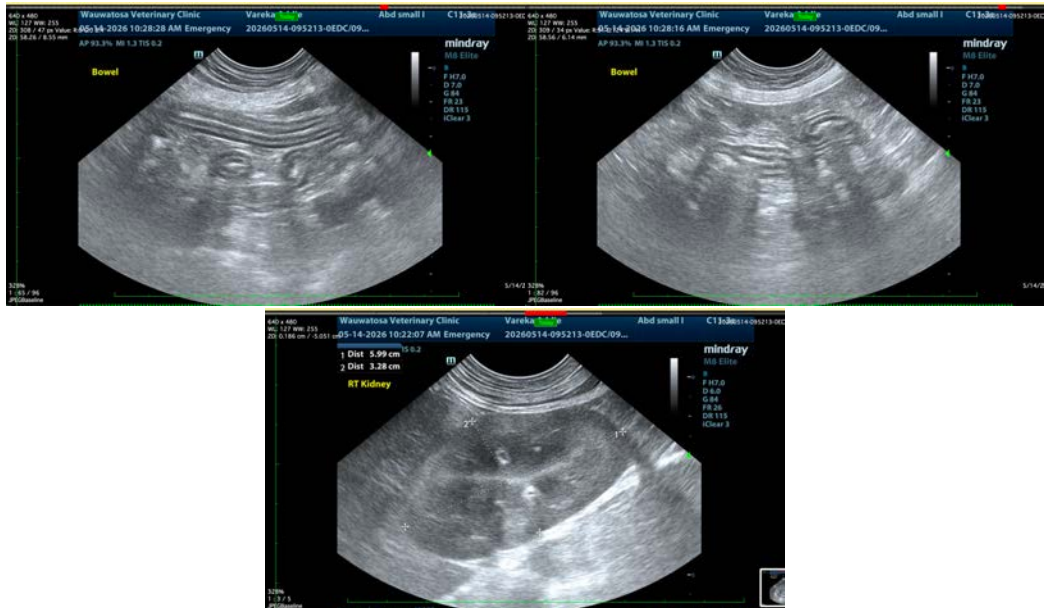
Dr. Elaine Binor

INVOICE

75151

DATE

5/14/26



The information and recommendations provided are based on the images presented by the referring veterinarian/sonographer. No evaluation can be communicated regarding pathology that was not visible in the image/video clips provided.

Thank you for this referral. If the clinical or image interpretation does not parallel your findings or if I can be of any further assistance please contact me.

Beth Johnson, DVM, DACVIM
info@sonopath.com