

**PATIENT**

Bella Marriott

**SPECIES**

Canine

**BREED**

Yorkshire Terrier

**SEX**

FS

**AGE**

14 years

**WEIGHT**

13.4 lbs

**INTERPRETED BY**

Beth Johnson, DVM  
DACVIM

**IMAGING PERFORMED BY**

Pamela Harrigan,  
RDCS, Certified  
Veterinary  
Sonographer

**HOSPITAL NAME**

Falmouth Animal  
Hospital

**REFERRING VET**

Dr. Lilan Hauser

**INVOICE**

11950

**DATE**

5/13/2026

**PRESENTING CLINICAL SIGNS**

Long history of pancreatitis. Diarrhea, yellow, frequent, urgent. Eating but also trying to bury food. cPL 424, ALT 172, ALP 383, lipase 801. PCR panel: all negative. Fecal negative. ACTH stim: pre 0.98m oist 10 0 WNL, not Addison's or Cushing's. \*Sedated torb/dexdomitor.

**ULTRASONOGRAPHIC EXAMINATION OF THE ABDOMEN**

**Urinary System**

The urinary bladder is adequately distended with anechoic contents. No masses, inflammatory changes, echogenic sediment or cystoliths are observed. The urinary bladder, trigone and visible pelvic urethra are normal in thickness with a smooth mucosal surface.

The right kidney is normal is size (4.58 cm), shape and echogenicity. It has smooth peripheral margination. There is a normal 1:3 cortex to medulla ratio with appropriate corticomedullary distinction. Trace pyelectasia is noted bilaterally. There is no evidence of mineral or infarcts observed.

The left kidney is normal is size (4.41 cm), shape and echogenicity. It has smooth peripheral margination. There is a normal 1:3 cortex to medulla ratio with appropriate corticomedullary distinction. Trace pyelectasia noted bilaterally. There is no evidence of mineral or infarcts observed.

**Adrenal Glands**

The right adrenal gland is normal in size (0.43 cm at cranial pole and 0.57 cm at caudal pole), shape and overall architecture, echogenicity and echotexture. Visible surrounding vasculature appears normal.

The left adrenal gland is normal in size (0.5 cm at cranial pole and 0.5 cm at caudal pole), shape and overall architecture, echogenicity and echotexture. Visible surrounding vasculature appears normal.

**Spleen**

Spleen is subjectively normal in size with a normal smooth capsular contour. Parenchyma is appropriately finely textured and homogenous with normal echogenicity relative to surrounding tissue (hyperechoic to liver). Multifocal well-demarcated hyperechoic homogenous nodule is noted. Splenic vasculature appears normal.

**Liver**

Liver is subjectively enlarged (swollen contour) without disruption of architecture. It has a normal homogenous echotexture. Parenchyma is diffusely hyperechoic characterized by less prominent than normal portal vein walls and increased echogenicity relative to the spleen and falciform fat. No focal lesions are observed. Visible vasculature and biliary tree appear normal without distension or congestion.

Gallbladder is moderately distended with anechoic bile as well as suspended and gravity dependent echogenic debris. The wall is smooth without visible thickening. There is no evidence of cystic or CBD dilation. There is no evidence of effusion or inflammation.

**Gastrointestinal**

The visible stomach wall is normal in thickness and layering. The lumen of the stomach is empty with no evidence of obstruction, foreign material or infiltrative disease. Pyloric outflow tract appears patent.



**PATIENT**

Bella Marriott

The visible small intestines are normal in wall thickness and layering. Very subtle, hyperechoic mucosal fogging or speckling is noted. Small intestinal motility appears adequate (1-3 contractions per min). The lumen of the small intestine is empty with no evidence of obstruction or foreign material

**SPECIES**

Canine

The visible colon is normal in wall thickness (< 0.2 cm) and layering. Contents are consistent with normal formed feces and gas.

**Pancreas**

**BREED**

Yorkshire Terrier

The observed pancreas appears appropriately isoechoic to surrounding omental fat. The capsule is mildly irregular in shape. Parenchyma is mildly heterogenous and coarse. There is no visible pancreatic duct dilation. There is no evidence of active peripancreatic inflammation.

**SEX**

FS

**Free Abdomen**

There is no visible free peritoneal effusion noted in these images.

**AGE**

14 years

There is no apparent pathologic lymphadenopathy noted in these images.

**PRIMARY FINDINGS**

**WEIGHT**

13.4 lbs

- Hyperechoic hepatomegaly – This appearance is non-specific and most consistent with a benign steroid (endocrine) or vacuolar hepatopathy or reactive or idiopathic hepatopathy. Inflammatory and/or infiltrative disease (such as round cell neoplasia) are also possible, but considered less likely.
- Mild gallbladder debris - Cholecystic debris is of unknown clinical significance. It can be seen with biliary stasis from fasting or illness. Cholecystic debris is not necessarily related to hepatobiliary disease. Echogenic bile is most commonly an incidental finding in dogs and should be interpreted in combination with clinical signs such as nausea, inappetence, cranial abdominal discomfort and/or laboratory changes such as increased ALP and/or increased Tbili.
- Very subtle mucosal speckling – Mucosal speckling is often present with inflammatory bowel disease (IBD). It is not specific for type or severity of disease. Mild speckling change can occur as a normal patient variant in the post-prandial state.
- Pancreatic age-related remodeling/Chronic pancreatitis – Mild irregularities are consistent with benign age-related change. Low-grade smoldering chronic pancreatitis cannot be ruled out and should be suspected in the face of appropriate clinical signs.

**INTERPRETED BY**

Beth Johnson, DVM  
DACVIM

**IMAGING PERFORMED BY**

Pamela Harrigan,  
RDCS, Certified  
Veterinary  
Sonographer

**HOSPITAL NAME**

Falmouth Animal  
Hospital

**REFERRING VET**

Dr. Lilan Hauser

**SECONDARY FINDINGS**

- Hyperechoic splenic nodule – most consistent with benign myelolipomas. Other differentials such as fibrosis or calcification caused by old hematomas or infarcts, chronic inflammation, granulomatous disease or metastatic disease cannot be ruled out, but are considered less likely.
- Trace pyelectasia bilaterally.

**INVOICE**

11950

**DATE**

5/13/2026

**INTERPRETATION OF THE FINDINGS & FURTHER RECOMMENDATIONS**

The changes noted above are very subtle/mild without a definitive ultrasonographically visible explanation for patient's reported ongoing diarrhea and nausea. Further gastrointestinal workup



**PATIENT**

Bella Marriott

**SPECIES**

Canine

**BREED**

Yorkshire Terrier

**SEX**

FS

**AGE**

14 years

**WEIGHT**

13.4 lbs

**INTERPRETED BY**

Beth Johnson, DVM  
DACVIM

**IMAGING PERFORMED BY**

Pamela Harrigan,  
RDCS, Certified  
Veterinary  
Sonographer

**HOSPITAL NAME**

Falmouth Animal  
Hospital

**REFERRING VET**

Dr. Lilan Hauser

**INVOICE**

11950

**DATE**

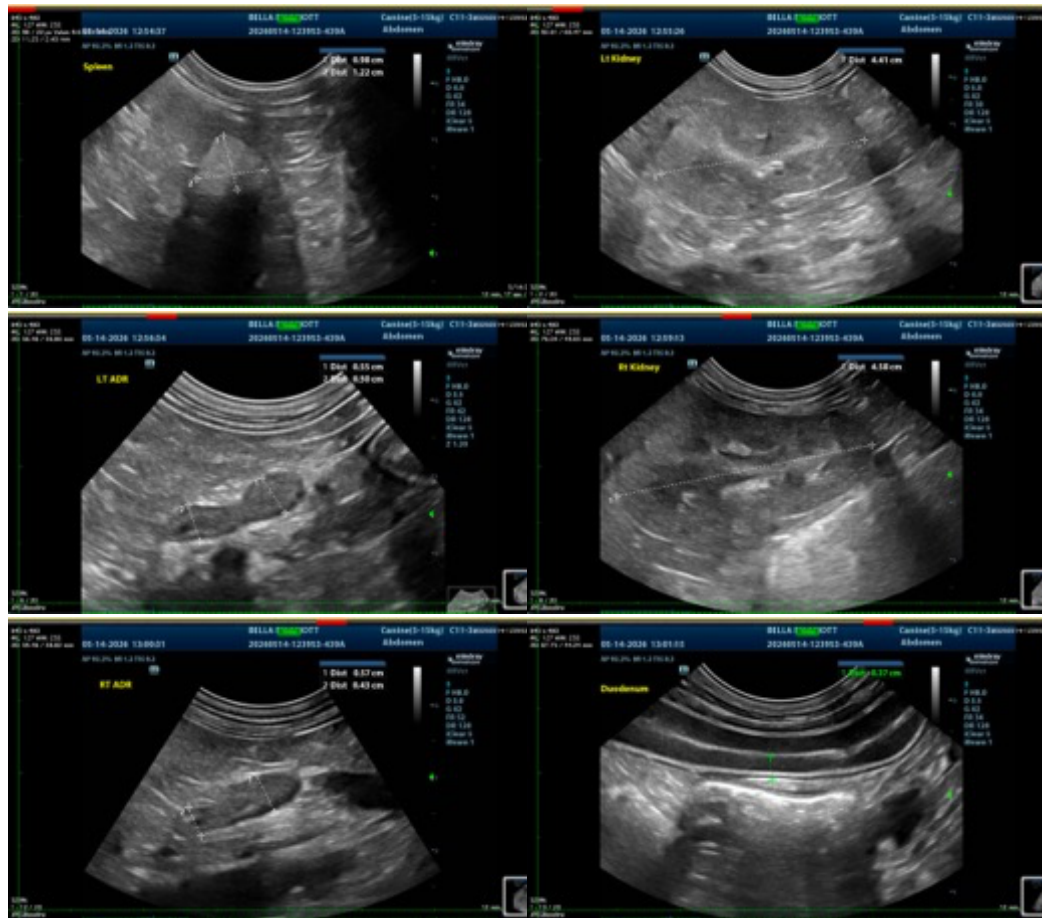
5/13/2026

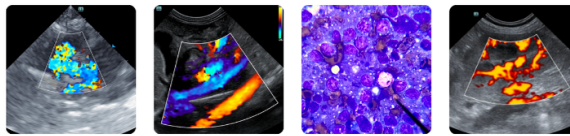
recommendations include:

- A gastrointestinal malabsorption panel (including cobalamin, folate, TLI and PLI) to Texas A&M GI Laboratory is recommended for further evaluation of GI and pancreatic function.
- A fecal enteropathogen PCR panel to Texas A&M GI Laboratory could be considered for further evaluation of possible infectious disease. Contact lab for recommendations on how long to discontinue antibiotics (if indicated) prior to obtaining a stool sample for submission.
- If not recently evaluated, urinalysis and, if indicated based on urinalysis results, urine culture is recommended. If protein is present in an otherwise quiet sediment, protein quantification with a urine protein to creatinine ration is recommended.

In the meantime, supportive/symptomatic medical management of clinical signs is recommended, including a probiotic (such as visbiome or proviable), empirical deworming with a 5-day course of Panacur and, if tolerated, a transition in diet, based on trial-and-error response, beginning possibly with a gastrointestinal biome diet vs a hydrolyzed protein diet vs other. Some patients respond to one brand/version of a hydrolyzed protein diet better than another brand, so several brand attempts may be required.

Fecal microbe transplant therapy could also be considered.





**PATIENT**

Bella Marriott

**SPECIES**

Canine

**BREED**

Yorkshire Terrier

**SEX**

FS

**AGE**

14 years

**WEIGHT**

13.4 lbs

**INTERPRETED BY**

Beth Johnson, DVM  
DACVIM

**IMAGING PERFORMED BY**

Pamela Harrigan,  
RDCS, Certified  
Veterinary  
Sonographer

**HOSPITAL NAME**

Falmouth Animal  
Hospital

**REFERRING VET**

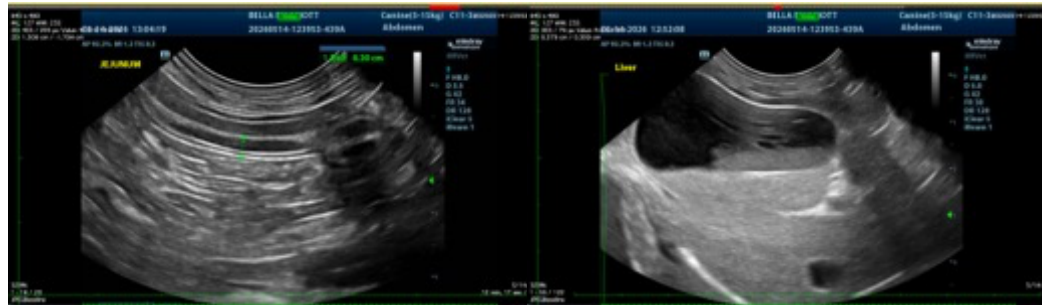
Dr. Lilan Hauser

**INVOICE**

11950

**DATE**

5/13/2026



The information and recommendations provided are based on the images presented by the referring veterinarian/sonographer. No evaluation can be communicated regarding pathology that was not visible in the image/video clips provided.

Thank you for this referral. If the clinical or image interpretation does not parallel your findings or if I can be of any further assistance please contact me.

**Beth Johnson, DVM, DACVIM**  
info@sonopath.com