



## PATIENT

Jane Jasper

## SPECIES

Canine

## BREED

Vizsla

## SEX

Spayed Female

## AGE

9 Years

## WEIGHT

56 lbs

## INTERPRETED BY

Beth Johnson, DVM  
DACVIM

## IMAGING PERFORMED BY

Dr. Sheldon

## HOSPITAL NAME

Advanced PetCare of  
Oakland

## REFERRING VET

Dr. Langfelt

## INVOICE

75083

## DATE

5/12/26

## PRESENTING CLINICAL SIGNS

PU/PD x2 years with chronic ALP elevation

## ULTRASONOGRAPHIC EXAMINATION OF THE ABDOMEN

### *Urinary System*

The urinary bladder is adequately distended with anechoic contents. No masses, inflammatory changes, echogenic sediment or cystoliths are observed. The urinary bladder, trigone and visible pelvic urethra are normal in thickness with a smooth mucosal surface.

Kidneys are overall normal in size and shape with smooth peripheral margination. A normal 1:3 cortex to medulla ratio is maintained. The medulla and cortices are uniform in texture with some mild increased cortical echogenicity and mild loss of corticomedullary distinction, expected in this age patient. There is no evidence of mineral or infarcts observed. Left kidney measures 7.14 cm. Right kidney measures 7.12 cm. Trace pyelectasia noted bilaterally.

### *Adrenal Glands*

The right adrenal gland is normal in size (0.95 cm at cranial pole and 0.63 cm at caudal pole), shape and overall architecture, echogenicity and echotexture. Visible surrounding vasculature appears normal.

The left adrenal gland is normal in size (0.61 cm at cranial pole and 0.71 cm at caudal pole), shape and overall architecture, echogenicity and echotexture. Visible surrounding vasculature appears normal.

### *Spleen*

The spleen is subjectively normal in size with a normal smooth capsular contour. Parenchyma is appropriately finely textured and homogenous with normal echogenicity relative to surrounding tissue (hyperechoic to liver). No focal nodules or masses are observed. Splenic vasculature appears normal.

### *Liver*

Liver is subjectively enlarged with mildly irregular margins. Parenchyma is mildly heterogenous characterized by multiple poorly defined hypoechoic nodules within otherwise hyperechoic liver parenchyma. Visible vasculature and biliary tree appear normal without distension or congestion.

Gallbladder is moderately distended with anechoic bile as well as suspended and gravity dependent echogenic debris. The wall is smooth without visible thickening. There is no evidence of cystic or CBD dilation. There is no evidence of effusion or inflammation.

### *Gastrointestinal*

The visible stomach wall is normal in thickness and layering. The lumen of the stomach is empty with no evidence of obstruction, foreign material or infiltrative disease. Pyloric outflow tract appears patent.

The visible small intestines are normal in wall thickness and layering. Small intestinal motility appears adequate (1-3 contractions per min). The lumen of the small intestine is empty with no evidence of obstruction, foreign material or infiltrative disease.

The visible colon is normal in wall thickness (< 0.2 cm) and layering. Contents are consistent with normal formed feces and gas.



## PATIENT

Jane Jasper

## SPECIES

Canine

## BREED

Vizsla

## SEX

Spayed Female

## AGE

9 Years

## WEIGHT

56 lbs

## INTERPRETED BY

Beth Johnson, DVM  
DACVIM

## IMAGING PERFORMED BY

Dr. Sheldon

## HOSPITAL NAME

Advanced PetCare of  
Oakland

## REFERRING VET

Dr. Langfelt

## INVOICE

75083

## DATE

5/12/26

## **Pancreas**

The pancreas that is observed appears appropriately isoechoic to surrounding omental fat. Visible capsule is smooth and normal in contour. Visible pancreatic parenchyma is homogenous and unremarkable. There is no visible pancreatic duct dilation. There is no evidence of active peripancreatic inflammation.

## **Free Abdomen**

There is no visible free peritoneal effusion noted in these images.

There is no apparent pathologic lymphadenopathy noted in these images.

## **PRIMARY FINDINGS**

- Mildly heterogenous liver – These changes are most consistent with benign processes such as nodular hyperplasia, steroid (vacuolar) hepatopathy, extramedullary hematopoiesis or possibly chronic inflammatory disease and less commonly infiltrative round cell or metastatic neoplasia.
- Very mild gallbladder debris - Cholecystic debris is of unknown clinical significance. It can be seen with biliary stasis from fasting or illness. Cholecystic debris is not necessarily related to hepatobiliary disease. Echogenic bile is most commonly an incidental finding in dogs and should be interpreted in combination with clinical signs such as nausea, inappetence, cranial abdominal discomfort and/or laboratory changes such as increased ALP and/or increased Tbili.

## **SECONDARY FINDINGS**

- Mild to moderate age related kidney changes with trace bilateral pyelectasia.

## **INTERPRETATION OF THE FINDINGS & FURTHER RECOMMENDATIONS**

This is a largely unremarkable structural abdomen without a definitive ultrasonographically visible explanation for patient's reported clinical signs or laboratory changes.

Differentials for PU/PD are vast and include, but are not limited to:

Primary polyuria caused by chronic kidney disease, pyelonephritis, liver disease, diabetes mellitus, hyperthyroidism, hypercalcemia, hyperadrenocorticism, hypoadrenocorticism, E.coli infections ie) pyometra in females, polycythemia, central diabetes insipidus or primary nephrogenic diabetes insipidus.

Primary polydipsia caused by psychogenic polydipsia, fever, pain, or central nervous system disease.

Most causes of PU/PD can be diagnosed with a comprehensive history and physical exam, a first AM urine specific gravity to see if urine concentration is possible (as most animals naturally consume less water overnight) followed by a comprehensive CBC, serum chemistry panel, electrolytes, and urinalysis.

If not, next step(s) may include a urine culture, low dose dexamethasone suppression test, T4, bile acids, Leptospirosis testing and/or an empirical course of antibiotics.

If a diagnosis is still not obtained, a more advanced work-up is indicated and consultation with an internist may be warranted.



**PATIENT**

Jane Jasper

**SPECIES**

Canine

**BREED**

Vizsla

**SEX**

Spayed Female

**AGE**

9 Years

**WEIGHT**

56 lbs

**INTERPRETED BY**

Beth Johnson, DVM  
DACVIM

**IMAGING PERFORMED BY**

Dr. Sheldon

**HOSPITAL NAME**

Advanced PetCare of  
Oakland

**REFERRING VET**

Dr. Langfelt

**INVOICE**

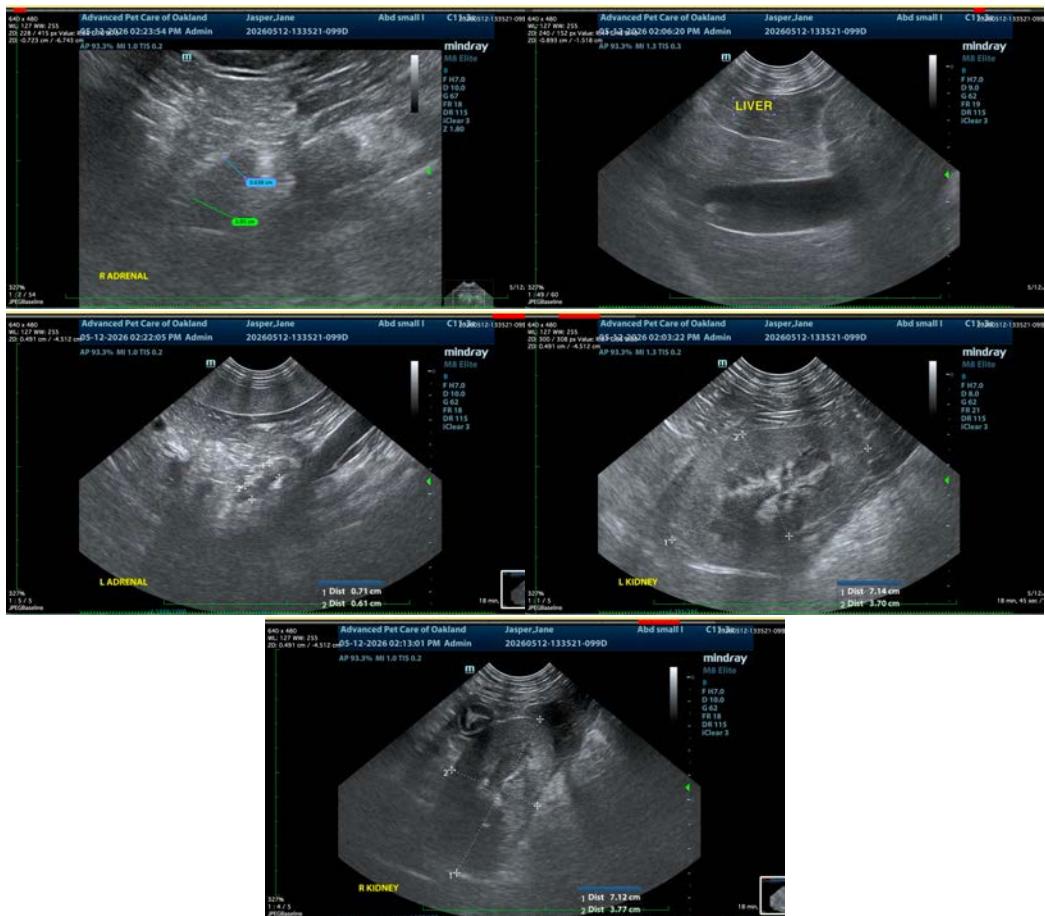
75083

**DATE**

5/12/26

Differentials for a primary cholestatic liver enzyme pattern (increased ALP) are vast and non-specific. Differentials include, but are not limited to, benign nodular hyperplasia which occurs in 70% of older dogs and often does not result in an abnormal ultrasound, reactive or idiopathic/vacuolar hepatopathy, cholestasis and/or hyperadrenocorticism as well as many chronic non-hepatobiliary diseases such as chronic infections/inflammation from dental disease, IBD, neoplasia, hyperlipidemia, hypothyroidism, chronic pancreatitis, chronic stress, etc.

- Adrenocortical testing such as a low dose dexamethasone suppression test could be considered if clinical signs of hyperadrenocorticism are present.
- Ursodiol could be considered if gallbladder sludge is noted as a finding.
- A fine needle aspirate of the liver could be considered if patient's coagulation status is appropriate.
- Otherwise, recommendations include addressing any other concurrent disease and monitoring. If values are progressive, recheck imaging is recommended.





## PATIENT

Jane Jasper

## SPECIES

Canine

## BREED

Vizsla

## SEX

Spayed Female

## AGE

9 Years

## WEIGHT

56 lbs

## INTERPRETED BY

Beth Johnson, DVM  
DACVIM

## IMAGING PERFORMED BY

Dr. Sheldon

## HOSPITAL NAME

Advanced PetCare of  
Oakland

## REFERRING VET

Dr. Langfelt

## INVOICE

75083

## DATE

5/12/26

The information and recommendations provided are based on the images presented by the referring veterinarian/sonographer. No evaluation can be communicated regarding pathology that was not visible in the image/video clips provided.

Thank you for this referral. If the clinical or image interpretation does not parallel your findings or if I can be of any further assistance please contact me.

**Beth Johnson, DVM, DACVIM**  
info@sonopath.com