



PATIENT

Baxter Campbell

SPECIES

Canine

BREED

Briard

SEX

Intact Male

AGE

9 Years

WEIGHT

48 kg

INTERPRETED BY

Beth Johnson, DVM
 DACVIM

IMAGING PERFORMED BY

Amanda Stewart

HOSPITAL NAME

Main Street Animal
 Hospital

REFERRING VET

Dr. Brochu

INVOICE

75064

DATE

5/12/26

PRESENTING CLINICAL SIGNS

Cranial abdomen distension when in for exam 5/4/2026. No other abnormalities noted on exam or presentation from owner. Radiographs performed. Current Medications: None.

Abnormal PE/Chem/CBC/UA Results: Rads attached adiographic Findings ventral abdomen splenic margins rounded, decreased serosal detail mid abdomen both right lateral and DV but no visible displacement of GI. Primary Question to Be Answered in This Exam cause for splenic enlargement.

ULTRASONOGRAPHIC EXAMINATION OF THE ABDOMEN

Urinary System

The urinary bladder is adequately distended with anechoic contents. No masses, inflammatory changes, echogenic sediment or cystoliths are observed. The urinary bladder, trigone and visible pelvic urethra are normal in thickness with a smooth mucosal surface.

Prostate is symmetrically enlarged (4.7 cm wide in the sagittal view) with smooth margins that are well differentiated from surrounding tissue. Normal bilobed shape is maintained. Parenchyma is diffusely hyperechoic. Several small anechoic cysts are noted. No mineral is noted.

The right kidney is normal is size (9.03 cm), shape and echogenicity. It has smooth peripheral margination. There is a normal 1:3 cortex to medulla ratio with appropriate corticomedullary distinction. There is no evidence of pyelectasia, mineral or infarcts observed.

The left kidney is normal is size (9.08 cm), shape and echogenicity. It has smooth peripheral margination. There is a normal 1:3 cortex to medulla ratio with appropriate corticomedullary distinction. There is no evidence of pyelectasia, mineral or infarcts observed.

Adrenal Glands

The right adrenal gland is normal in size (1.8 cm at cranial pole and 0.84 cm at caudal pole), shape and overall architecture, echogenicity and echotexture. Visible surrounding vasculature appears normal.

The left adrenal gland is normal in size (0.51 cm at cranial pole and 0.52 cm at caudal pole), shape and overall architecture, echogenicity and echotexture. Visible surrounding vasculature appears normal.

Spleen

Spleen is subjectively large in size with a normal smooth capsular contour. Parenchyma is appropriately finely textured and homogenous with normal echogenicity relative to surrounding tissue (hyperechoic to liver). No focal nodules or masses are observed. Splenic vasculature appears normal. The spleen is folded upon itself, which is a positional non-pathologic variant. In views where the hilus is able to be measured, the spleen appears to measure approximately 2.8 cm thick.

Liver

The liver is subjectively normal in size with normal smooth curvilinear peripheral contour. Parenchyma is appropriately hypoechoic to the spleen in echogenicity and appropriately mildly coarse and homogenous in echotexture. No focal lesions are observed. Visible vasculature and biliary tree appear normal without distension or congestion.



PATIENT

Baxter Campbell

The gallbladder is non-distended in size. The wall is smooth without visible thickening. Luminal contents are primarily anechoic. There is no evidence of cystic or common bile duct dilation.

Gastrointestinal

SPECIES

Canine

The visible stomach wall is normal in thickness and layering. The lumen of the stomach is mildly distended with very echogenic reverberation artifact from intraluminal gas. There is no evidence of obstruction, foreign material, or infiltrative disease; however, visualization is partially inhibited by gas.

BREED

Briard

The visible small intestines are normal in wall thickness and layering. Small intestinal motility appears adequate (1-3 contractions per min). The lumen of the small intestine is mildly distended with very echogenic reverberation artifact from intraluminal gas. There is no evidence of obstruction, foreign material, or infiltrative disease; however, visualization is partially inhibited by gas.

SEX

Intact Male

The visible colon is normal in wall thickness (< 0.2 cm) and layering. Contents are consistent with normal formed feces and gas.

AGE

9 Years

The pancreas that is observed appears appropriately isoechoic to surrounding omental fat. Visible capsule is smooth and normal in contour. Visible pancreatic parenchyma is homogenous and unremarkable. There is no visible pancreatic duct dilation. There is no evidence of active peripancreatic inflammation.

WEIGHT

48 kg

Free Abdomen

INTERPRETED BY

Beth Johnson, DVM
 DACVIM

There is no visible free peritoneal effusion noted in these images.

There is no apparent pathologic lymphadenopathy noted in these images.

Both testicles are visualized. The left contains several subtle hypoechoic densities, one measuring 0.40 cm in diameter and one measuring 0.80 cm in diameter.

IMAGING PERFORMED BY

Amanda Stewart

PRIMARY FINDINGS

HOSPITAL NAME

Main Street Animal Hospital

- Splenomegaly- can be associated with congestion caused by sedation (if sedated) but can also be associated with diffuse infiltrative disease. Both benign conditions such as extramedullary hematopoiesis, lymphoid hyperplasia, as well as infiltrative neoplastic diseases such as round cell neoplasia should be considered.
- Several hypo- to possibly anechoic densities within the left testicle could represent benign or malignant disease.

REFERRING VET

Dr. Brochu

SECONDARY FINDINGS

INVOICE

75064

- Benign Prostatic Hyperplasia with cysts – Prostatic findings are most consistent with Benign Prostatic Hyperplasia (BPH) and concurrent benign prostatic cysts. Active prostatitis cannot be ruled out. Infiltrative neoplasia cannot be ruled out but is considered less likely.

DATE

5/12/26

INTERPRETATION OF THE FINDINGS & FURTHER RECOMMENDATIONS

Fine needle aspirates of the spleen could be considered if patient's coagulation status is appropriate.



PATIENT

Baxter Campbell

SPECIES

Canine

BREED

Briard

SEX

Intact Male

AGE

9 Years

WEIGHT

48 kg

INTERPRETED BY

Beth Johnson, DVM
 DACVIM

IMAGING PERFORMED BY

Amanda Stewart

HOSPITAL NAME

Main Street Animal
 Hospital

REFERRING VET

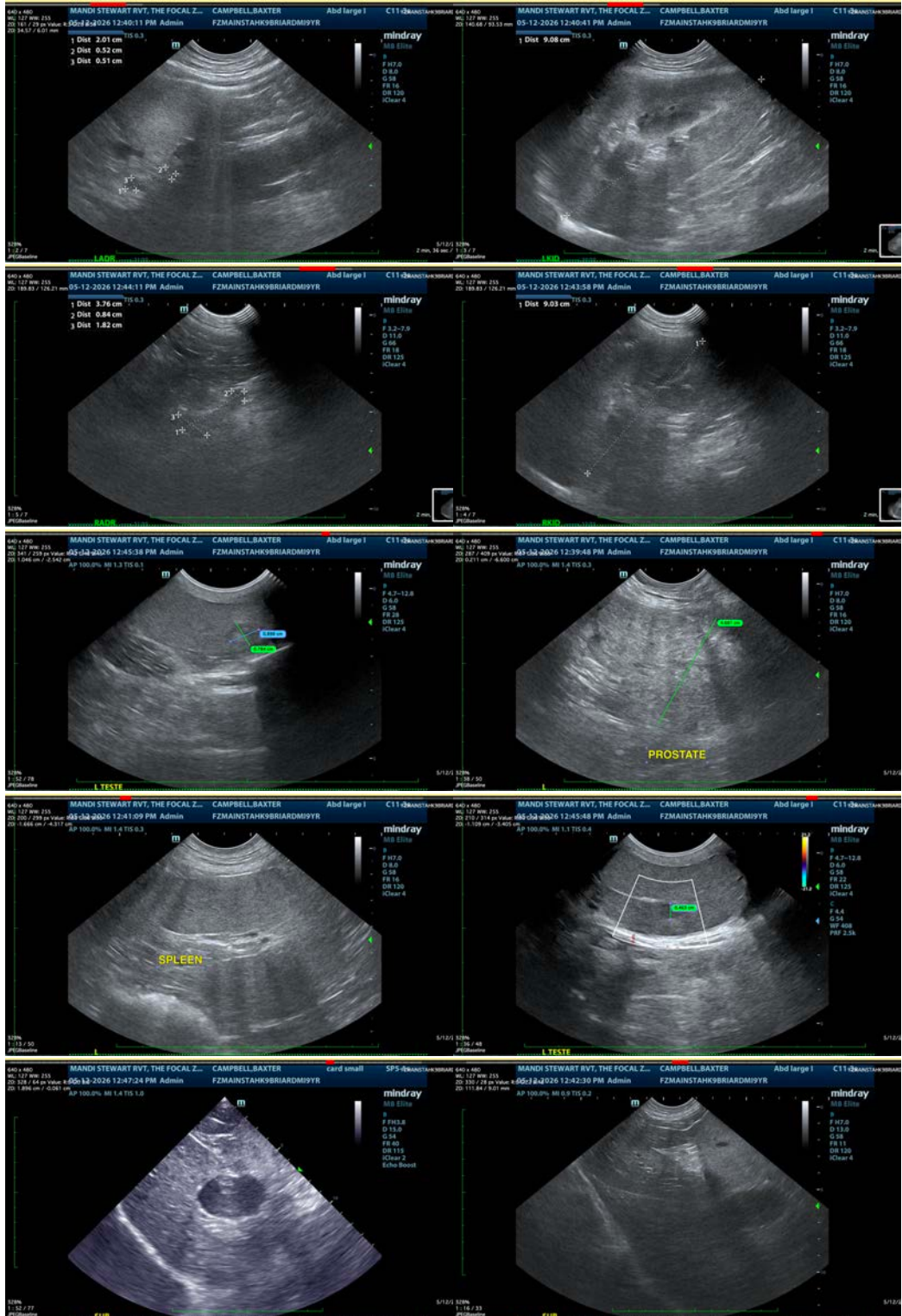
Dr. Brochu

INVOICE

75064

DATE

5/12/26





PATIENT

Baxter Campbell

SPECIES

Canine

BREED

Briard

SEX

Intact Male

AGE

9 Years

WEIGHT

48 kg

INTERPRETED BY

Beth Johnson, DVM
DACVIM

**IMAGING
PERFORMED BY**

Amanda Stewart

HOSPITAL NAME

Main Street Animal
Hospital

REFERRING VET

Dr. Brochu

INVOICE

75064

DATE

5/12/26

The information and recommendations provided are based on the images presented by the referring veterinarian/sonographer. No evaluation can be communicated regarding pathology that was not visible in the image/video clips provided.

Thank you for this referral. If the clinical or image interpretation does not parallel your findings or if I can be of any further assistance please contact me.

Beth Johnson, DVM, DACVIM
info@sonopath.com