

PATIENT

Jewelie Johnson

SPECIES

Canine

BREED

Chesapeake Bay
Retriever

SEX

Intact Female

AGE

7 Years

WEIGHT

62 lbs

INTERPRETED BY

Beth Johnson, DVM
DACVIM

IMAGING PERFORMED BY

Julia Bakker DVM

HOSPITAL NAME

Orange Blossom
Veterinary Imaging

REFERRING VET

Stephen Romero DVM

INVOICE

16107

DATE

05/11/26

PRESENTING CLINICAL SIGNS

Patient presented on 5/9/26 for hyporexia and vomiting. History of B-cell lymphoma treated with CHOP protocol which finished 1/2026. Started LOPP 4/30/26 including lomustine and prednisone for recurrence. Current medications: Prednisone, Lomustine, Cerenia, milk thistle. On 5/9 CBC/Chem showed hyperalbuminemia 4.6, lymphopenia# 0.61. Oncology recommended a follow up AUS

ULTRASONOGRAPHIC EXAMINATION OF THE ABDOMEN

Urinary System

Urinary bladder is adequately distended with anechoic contents. No masses, inflammatory changes, echogenic sediment or cystoliths are observed. The urinary bladder, trigone and visible pelvic urethra are normal in thickness with a smooth mucosal surface.

Left kidney is normal in size (6.41 cm), shape and echogenicity. It has smooth peripheral margination. There is a normal 1:3 cortex to medulla ratio with appropriate corticomedullary distinction. There is no evidence of pyelectasia, mineral or infarcts observed. In one view, there's a very subtle possible discrete hypoechoic approximately 1.0 cm in diameter nodular area noted in the left kidney. This finding is not corroborated in other views.

Right kidney is normal in size (5.98 cm), shape and echogenicity. It has smooth peripheral margination. There is a normal 1:3 cortex to medulla ratio with appropriate corticomedullary distinction. There is no evidence of pyelectasia, mineral or infarcts observed.

Adrenal Glands

Left adrenal gland is normal in size (0.44 cm at cranial pole and 0.57 cm at caudal pole), shape and overall architecture, echogenicity and echotexture. Visible surrounding vasculature appears normal.

Right adrenal gland is normal in size (1.8 cm at cranial pole and 0.43 cm at caudal pole), shape and overall architecture, echogenicity and echotexture. Visible surrounding vasculature appears normal.

Spleen

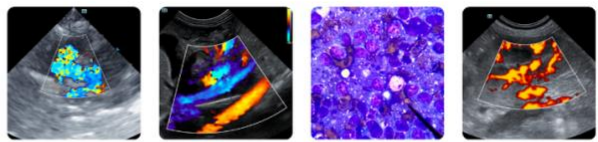
Spleen is subjectively normal in size with a normal smooth capsular contour. Parenchyma is appropriately finely textured and homogenous with normal echogenicity relative to surrounding tissue (hyperechoic to liver). No focal nodules or masses are observed. Splenic vasculature appears normal.

Liver

Liver is subjectively enlarged (swollen contour) without disruption of architecture. It has a normal homogenous echotexture. Parenchyma is diffusely hyperechoic characterized by less prominent than normal portal vein walls and increased echogenicity relative to the spleen and falciform fat. No focal lesions are observed. Visible vasculature and biliary tree appear normal without distension or congestion.

Gallbladder is non-distended in size. The wall is smooth without visible thickening. Luminal contents are primarily anechoic. There is no evidence of cystic or common bile duct dilation.

Gastrointestinal



PATIENT

Jewelie Johnson

The visible stomach wall is normal in thickness and layering. The lumen of the stomach is empty with no evidence of obstruction, foreign material or infiltrative disease. Pyloric outflow tract appears patent.

SPECIES

Canine

The visible small intestines are normal in wall thickness and layering. Small intestinal motility appears adequate (1-3 contractions per min). The lumen of the small intestine is empty with no evidence of obstruction, foreign material or infiltrative disease.

BREED

Chesapeake Bay
Retriever

The visible colon is normal in wall thickness (< 0.2 cm) and layering. Contents are consistent with normal formed feces and gas.

SEX

Intact Female

The pancreas that is observed appears appropriately isoechoic to surrounding omental fat. Visible capsule is smooth and normal in contour. Visible pancreatic parenchyma is homogenous and unremarkable. There is no visible pancreatic duct dilation. There is no evidence of active peripancreatic inflammation.

AGE

7 Years

Free Abdomen

WEIGHT

62 lbs

Both ovaries are well visualized. The left contains several discrete homogenous hypo- and anechoic densities consistent with possible follicles versus cysts. Medial to the spleen, is approximately 2.2 cm x 0.7 cm in size homogenous hypoechoic density likely representing a lymph node.

INTERPRETED BY

Beth Johnson, DVM
DACVIM

In the area of the trifurcation is approximately 1.7 cm x 2.4 cm hypo- to almost anechoic appearing round density that I can't determine between a lymph node versus a mildly fluid dilated tubular structure with differentials including potentially the uterus in that area versus colon versus other.

ULTRASONOGRAPHIC FINDINGS

- Possible left renal nodule would be concerning for infiltrative round cell neoplasia such as lymphoma given patient's history if it's a real finding. Having said that, it's a subtle change and only subtly suspected in one view.
- Hyperechoic hepatomegaly- This appearance is non-specific and most consistent with a benign steroid (endocrine) or vacuolar hepatopathy or reactive or idiopathic hepatopathy. Inflammatory and/or infiltrative disease (such as round cell neoplasia) are also possible but considered less likely.
- Lymphadenopathy medial to the spleen and potentially in the area of the aortic trifurcation may be present, although the appearance of the density medial to the spleen maintains a normal more reactive lymph node shape and the density in the area of the trifurcation as described above almost appears fluid filled and could represent an end-on view of a fluid filled tubular structure such as uterus or colon.

IMAGING PERFORMED BY

Julia Bakker DVM

HOSPITAL NAME

Orange Blossom
Veterinary Imaging

REFERRING VET

Stephen Romero DVM

INVOICE

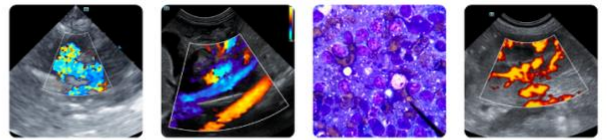
16107

DATE

05/11/26

INTERPRETATION OF THE FINDINGS & FURTHER RECOMMENDATIONS

The changes described above are all subtle and difficult to definitively diagnose. There's not a definitive ultrasonographically visible intra-abdominal explanation for patient's reported hyporexia or vomiting. If patient's clinical signs are not believed to be secondary to the reported underlying lymphoma and/or the chemotherapy associated with treatment etc., then further gastrointestinal workup may be indicated.



PATIENT

Jewelie Johnson

SPECIES

Canine

BREED

Chesapeake Bay Retriever

SEX

Intact Female

AGE

7 Years

WEIGHT

62 lbs

INTERPRETED BY

Beth Johnson, DVM
DACVIM

IMAGING PERFORMED BY

Julia Bakker DVM

HOSPITAL NAME

Orange Blossom Veterinary Imaging

REFERRING VET

Stephen Romero DVM

INVOICE

16107

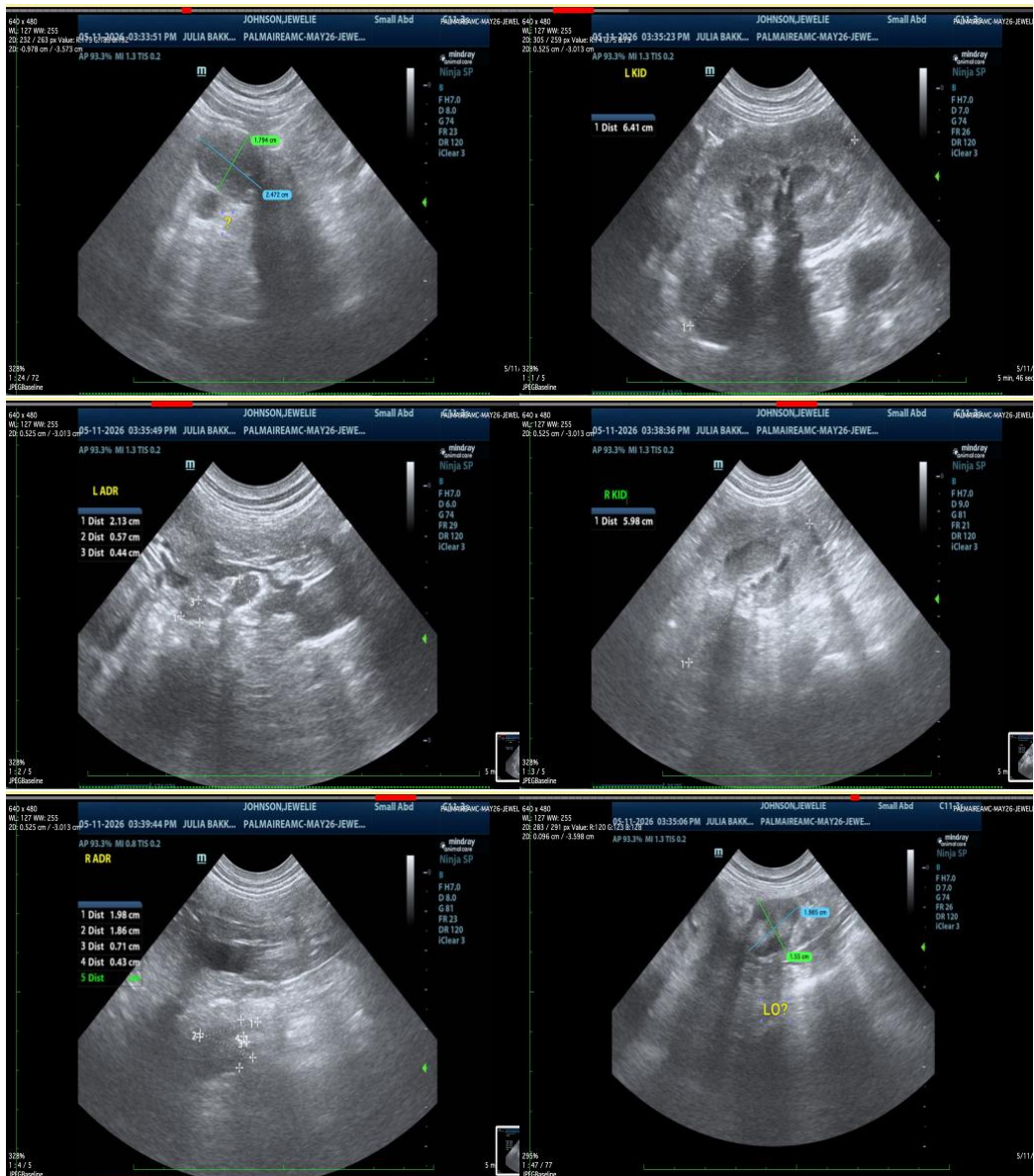
DATE

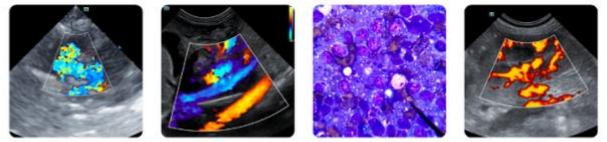
05/11/26

In the meantime, additionally three view thoracic radiographs are recommended for further assessment of cardio-pulmonary status as well as to further evaluate for any evidence of metastatic disease, if not recently evaluated.

Fine needle aspirates of the left kidney +/- liver +/- the structure described medial to the spleen +/- aortic trifurcation could all be considered if patient's coagulation status is appropriate.

Alternatively, advanced imaging of the abdomen such as an abdominal contrast CT scan may be helpful.





PATIENT

Jewelie Johnson

SPECIES

Canine

BREED

Chesapeake Bay Retriever

SEX

Intact Female

AGE

7 Years

WEIGHT

62 lbs

INTERPRETED BY

Beth Johnson, DVM
DACVIM

IMAGING PERFORMED BY

Julia Bakker DVM

HOSPITAL NAME

Orange Blossom Veterinary Imaging

REFERRING VET

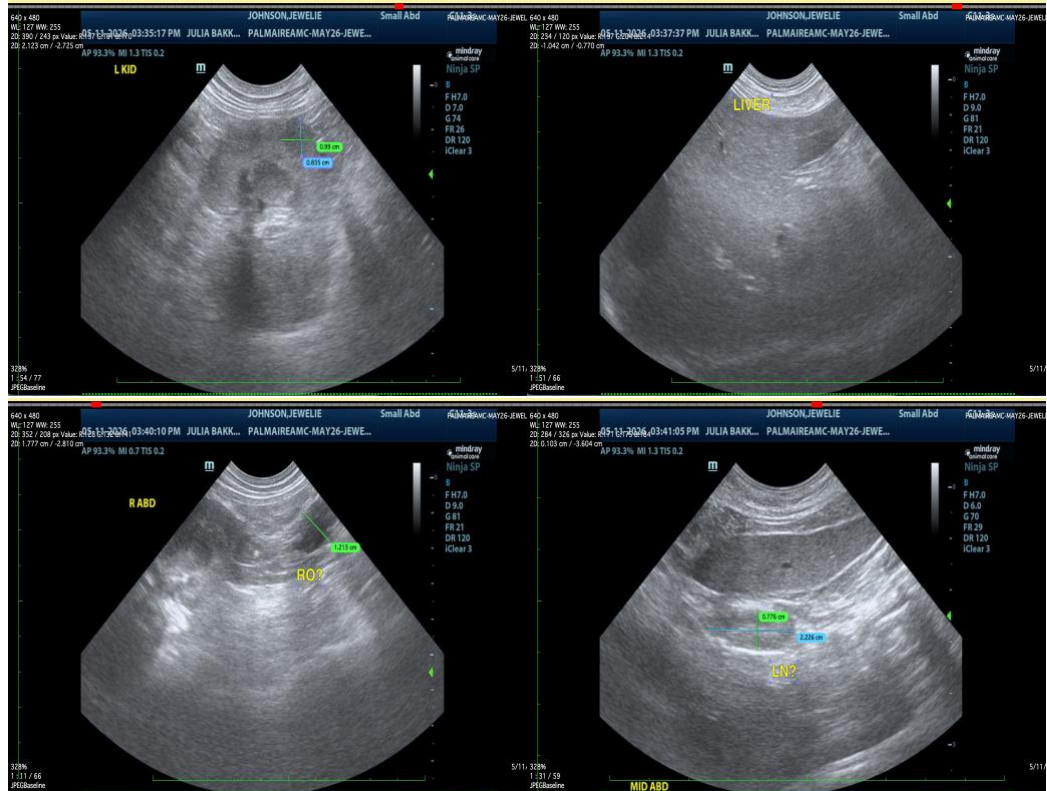
Stephen Romero DVM

INVOICE

16107

DATE

05/11/26



The information and recommendations provided are based on the images presented by the referring veterinarian/sonographer. No evaluation can be communicated regarding pathology that was not visible in the image/video clips provided.

Thank you for this referral. If the clinical or image interpretation does not parallel your findings or if I can be of any further assistance, please contact me.

Beth Johnson, DVM DACVIM

info@sonopath.com