

**PATIENT**

Rocco Spinosa

**SPECIES**

Canine

**BREED**

Chihuahua

**SEX**

Neutered Male

**AGE**

13 Years

**WEIGHT**

11.8 Pounds

**INTERPRETED BY**

Beth Johnson, DVM  
DACVIM

**IMAGING PERFORMED BY**

Kelly Vazquez

**HOSPITAL NAME**

Animal General on the  
Hudson

**REFERRING VET**

Dr. Daniel Tierney

**INVOICE**

47304

**DATE**

5/10/23

**PRESENTING CLINICAL SIGNS**

Patient presents for elevated ALT. Patient has at times been more aggressive, has "marked" in the house more. Current meds: Glucosamine, Elevated CBD, HW prevention and flea/tick.

Abnormal PE/Chem/CBC/UA Results: ALT 146. U/A: pH 8.5, struvite crystals seen 4-10, no UTI (culture neg). USG: 1.022.

**ULTRASONOGRAPHIC EXAMINATION OF THE ABDOMEN**

**Urinary System**

Urinary bladder is adequately distended. It has a normal uniform wall thickness. Contents include primarily anechoic fluid with occasional echogenic non-shadowing debris, most consistent with exfoliated cells, mucous and/or small blood clots. Both sterile inflammation as well as urinary tract infection can also present with echogenic debris. No masses observed. A small, punctate cystolith measuring 0.28 cm in diameter is noted. The trigone and visible pelvic urethra are normal in thickness with a smooth mucosal surface.

Prostate is normal in size, echotexture and echogenicity for a neutered male.

The right kidney is normal in size (3.25 cm), shape and echogenicity. It has smooth peripheral margination. There is a normal 1:3 cortex to medulla ratio with appropriate corticomedullary distinction. There is no evidence of pyelectasia, mineral or infarcts observed. A hyperechoic band parallel to the corticomedullary border is present.

The left kidney is normal in size (3.28 cm), shape and echogenicity. It has smooth peripheral margination. There is a normal 1:3 cortex to medulla ratio with appropriate corticomedullary distinction. There is no evidence of pyelectasia, mineral or infarcts observed. A hyperechoic band parallel to the corticomedullary border is present.

**Adrenal Glands**

The right adrenal gland is normal in size (1.11 cm long x 0.62 cm at the cranial pole and 0.26 cm at the caudal pole), shape and contour. Corticomedullary structure is unremarkable. Visible surrounding vasculature appears normal.

The left adrenal gland is normal in size (1.49 cm long x 0.34 cm at the cranial pole and 0.44 cm at the caudal pole), shape and contour. Corticomedullary structure is unremarkable. Visible surrounding vasculature appears normal.

**Spleen**

The spleen is subjectively normal in size with a normal smooth capsular contour. Parenchyma is appropriately finely textured and homogenous with normal echogenicity relative to surrounding tissue (hyperechoic to liver). No focal nodules or masses are observed. Splenic vasculature appears normal.

**Liver**

The liver is subjectively normal in size with normal smooth curvilinear peripheral contour. Parenchyma is appropriately hypoechoic to the spleen in echogenicity and appropriately mildly coarse and homogenous in echotexture. No focal lesions are observed. Visible vasculature and biliary tree appear normal without distension or congestion. The portal vein to caudal vena cava ratio is normal at 1:1.

The gallbladder is non-distended in size. The wall is smooth without visible thickening. Luminal contents are primarily anechoic. There is no evidence of cystic or common bile duct dilation.



**PATIENT**

Rocco Spinosa

**SPECIES**

Canine

**BREED**

Chihuahua

**SEX**

Neutered Male

**AGE**

13 Years

**WEIGHT**

11.8 Pounds

**INTERPRETED BY**

Beth Johnson, DVM  
DACVIM

**IMAGING PERFORMED BY**

Kelly Vazquez

**HOSPITAL NAME**

Animal General on the  
Hudson

**REFERRING VET**

Dr. Daniel Tierney

**INVOICE**

47304

**DATE**

5/10/23

**Gastrointestinal**

The visible stomach wall is normal in thickness and layering. The lumen of the stomach is mildly distended with very echogenic reverberation artifact from intraluminal gas. There is no evidence of obstruction, foreign material or infiltrative disease; however, complete visualization of far wall is partially inhibited by gas. Pyloric outflow tract appears patent.

The visible small intestines are normal in wall thickness and layering (canine duodenum < 0.5 cm and feline duodenum < 0.4 cm; other < 0.3 cm). Small intestinal motility appears adequate (1-3 contractions per min). The lumen of the small intestine is empty with no evidence of obstruction, foreign material or infiltrative disease.

The visible colon is normal in wall thickness (< 0.2 cm) and layering. Contents are consistent with normal formed feces and gas.

**Pancreas**

The pancreatic parenchyma is appropriately isoechoic to surrounding tissue. Visible capsule is smooth and normal in contour. There is no visible pancreatic duct dilation. There is no evidence of active peripancreatic inflammation.

**Free Abdomen**

There is no evidence of free peritoneal effusion noted in these images.

There is no apparent lymphadenopathy noted in these images.

**ULTRASONOGRAPHIC FINDINGS**

- **Bilateral medullary rim sign** - This finding is of unknown clinical significance and can be a normal variant, often idiopathic. Medullary rim sign can be present with renal disease including FIP, lymphoma, hypercalcemic nephropathy, Leptospirosis, tubular disease, other and should be interpreted in combination with other more specific indications of kidney disease such as isosthenuria, proteinuria, azotemia, etc. This is a common incidental finding in patients with diabetes mellitus.
- Small urinary bladder cystoliths and mild urinary bladder debris.

**INTERPRETATION OF THE FINDINGS & FURTHER RECOMMENDATIONS**

Given this patient's reported mild ALT increase, recommendations include an "antigen search" for sources of reactive hepatopathy (including testing for Leptospirosis), followed by a course of empirical antibiotics and hepatic nutraceuticals, with monitoring of ALT for improvement. If improvement is not noted and/or enzyme increase progresses, a liver biopsy may be warranted.

Given the concurrent reported behavior change, bile acids should also be considered.

Despite a negative urine culture, there is some concern for a urinary tract infection, given the struvite crystalluria, as struvite cystoliths are uncommon without a concurrent infection. Therefore, rechecking the urine culture, being sure the sample is being obtained at least 7-10 days off of antibiotics, or empirical trying a course of antibiotics to see if the urinary accidents improve, could be considered.



**PATIENT**

Rocco Spinosa

**SPECIES**

Canine

**BREED**

Chihuahua

**SEX**

Neutered Male

**AGE**

13 Years

**WEIGHT**

11.8 Pounds

**INTERPRETED BY**

Beth Johnson, DVM  
DACVIM

**IMAGING PERFORMED BY**

Kelly Vazquez

**HOSPITAL NAME**

Animal General on the  
Hudson

**REFERRING VET**

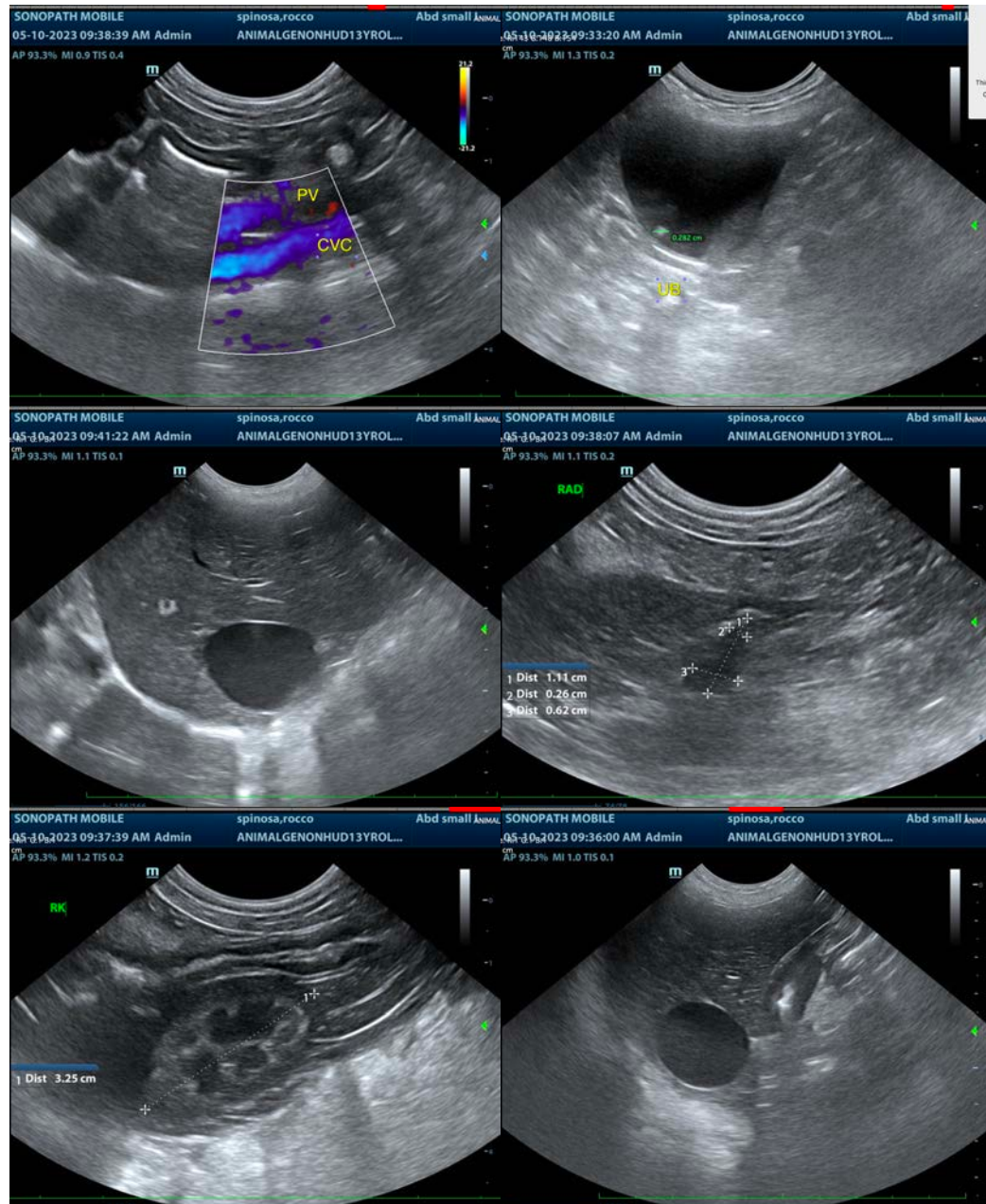
Dr. Daniel Tierney

**INVOICE**

47304

**DATE**

5/10/23





**PATIENT**

Rocco Spinosa

**SPECIES**

Canine

**BREED**

Chihuahua

**SEX**

Neutered Male

**AGE**

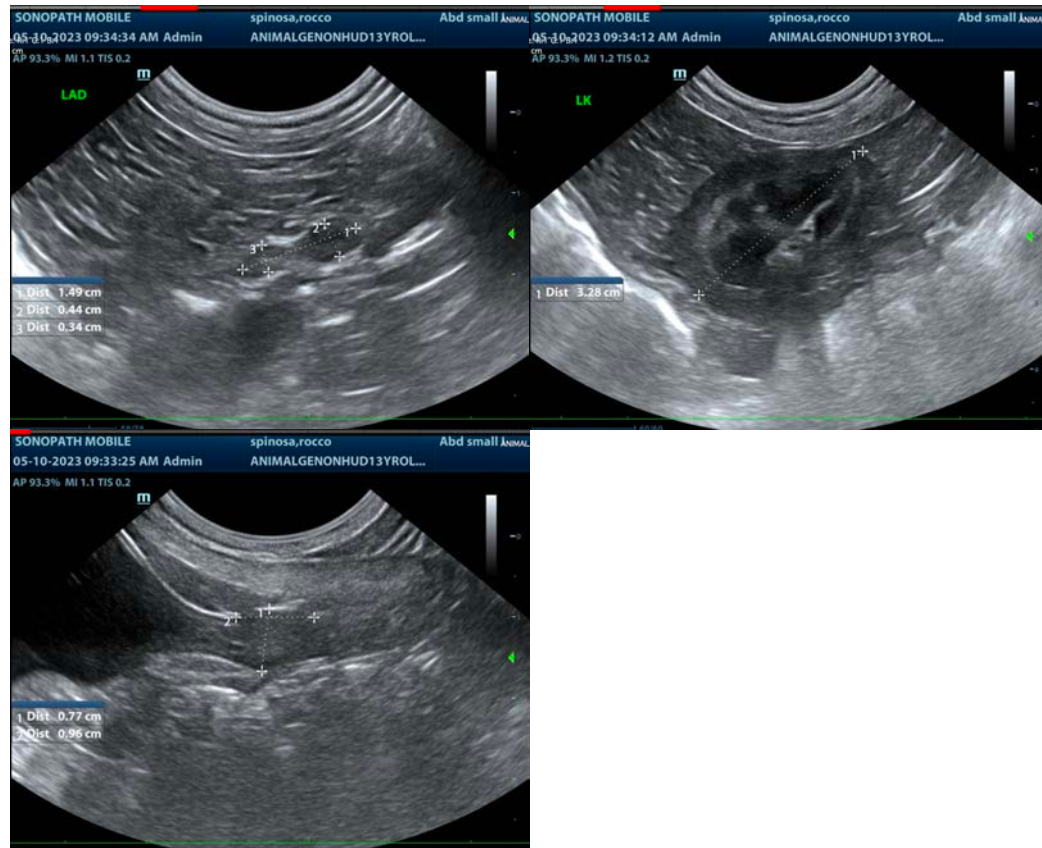
13 Years

**WEIGHT**

11.8 Pounds

**INTERPRETED BY**

Beth Johnson, DVM  
DACVIM



**IMAGING PERFORMED BY**

Kelly Vazquez

**HOSPITAL NAME**

Animal General on the Hudson

**REFERRING VET**

Dr. Daniel Tierney

**INVOICE**

47304

**DATE**

5/10/23

The information and recommendations provided are based on the images presented by the referring veterinarian/sonographer. No evaluation can be communicated regarding pathology that was not visible in the image/video clips provided.

Thank you for this referral. If the clinical or image interpretation does not parallel your findings or if I can be of any further assistance please contact me.

**Beth Johnson, DVM, DACVIM**  
Beth.Johnson@sonopath.com