



**PATIENT**

Maya Perez

**SPECIES**

Canine

**BREED**

Yorkie x

**SEX**

Spayed Female

**AGE**

12 Years

**WEIGHT**

15.4 lbs

**INTERPRETED BY**

Beth Johnson, DVM  
 DACVIM

**IMAGING PERFORMED BY**

Kathleen Byrnes

**HOSPITAL NAME**

Monroe Road Animal  
 Hospital

**REFERRING VET**

Dr. Davis

**INVOICE**

74949

**DATE**

5/1/26

**PRESENTING CLINICAL SIGNS**

P presented for Double Cavity US due to episode of not wanting to eat, vomiting bile, wet cough, concern for aspiration, elevated liver enzymes, cough resolved on antibiotics, p is having dark loose stool, concern for toxin, dietary indiscretion, stress colitis, heart related cough. Currently on Pimobendan. Previous US read by Dr. Johnson 3/11/26-heterogeneous liver, emerging mass liver, hypoechoic splenic nodule, age related kidney changes, several u.bladder calculi, mild reactive iliac lymph nodes. Previous Echo read by Dr. Blass on 11/24/25- Deg Mitral and Tricuspid DZ

**ULTRASONOGRAPHIC EXAMINATION OF THE ABDOMEN**

**Urinary System**

The urinary bladder is adequately distended with anechoic contents. No masses or inflammatory changes are observed. Several pinpoint cystoliths are noted within the urinary bladder. The urinary bladder, trigone and visible pelvic urethra are normal in thickness with a smooth mucosal surface.

Kidneys are overall normal in size and shape with smooth peripheral margination. A normal 1:3 cortex to medulla ratio is maintained. The medulla and cortices are uniform in texture with some mild increased cortical echogenicity and mild loss of corticomedullary distinction, expected in this age patient. There is no evidence of pyelectasia, mineral or infarcts observed. Left measured 4.1 cm. Right measured 4.0 cm.

**Adrenal Glands**

The right adrenal gland is normal in size (0.48 cm at cranial pole and 0.59 cm at caudal pole), shape and overall architecture, echogenicity and echotexture. Visible surrounding vasculature appears normal.

The left adrenal gland is normal in size (0.54 cm at cranial pole and 0.59 cm at caudal pole), shape and overall architecture, echogenicity and echotexture. Visible surrounding vasculature appears normal.

**Spleen**

The spleen is subjectively normal in size with a normal smooth capsular contour. Parenchyma is appropriately finely textured and homogenous with normal echogenicity relative to surrounding tissue (hyperechoic to liver), except for an approximately 0.50 cm in diameter non-capsule disrupting, hypo- to anechoic nodule in the mid spleen. Splenic vasculature appears normal.

**Liver**

Liver is subjectively enlarged with mildly irregular margins. Parenchyma is diffusely moderately heterogenous characterized by multiple poorly defined hypoechoic nodules within otherwise hyperechoic liver parenchyma. Focally in the mid caudal abdomen there remains a slightly more discrete, mildly heterogeneous, hypoechoic density measuring 1.6 cm x 1.9 cm in size. Visible vasculature and biliary tree appear normal without distension or congestion

The gallbladder is non-distended in size. The wall is smooth without visible thickening. Luminal contents are primarily anechoic. There is no evidence of cystic or common bile duct dilation.

**Gastrointestinal**

The visible stomach wall is normal in thickness and layering. The stomach is moderately distended with echogenic non-shadowing luminal contents and gas consistent with normal ingesta. There is no



**PATIENT**

Maya Perez

evidence of obstruction, foreign material or infiltrative disease. If patient was appropriately fasted, delayed gastric emptying could be considered. Non-shadowing foreign material is considered less likely but cannot be definitively ruled out.

**SPECIES**

Canine

If clinical signs are consistent (vomiting, etc.), recommendations include supportive medical care, 24 hours fasting and re-image.

**BREED**

Yorkie x

The visible small intestines are normal in wall thickness and layering. Small intestinal motility appears adequate (1-3 contractions per min). The lumen is mildly distended with echogenic non-shadowing luminal contents and gas consistent with normal ingesta/chyme. There is no evidence of obstruction, foreign material or infiltrative disease.

**SEX**

Spayed Female

The visible colon is normal in wall thickness (< 0.2 cm) and layering. Contents are consistent with normal formed feces and gas.

***Pancreas***

**AGE**

12 Years

The pancreas that is observed appears appropriately isoechoic to surrounding omental fat. Visible capsule is smooth and normal in contour. Visible pancreatic parenchyma is homogenous and unremarkable. There is no visible pancreatic duct dilation. There is no evidence of active peripancreatic inflammation.

**WEIGHT**

15.4 lbs

***Free Abdomen***

**INTERPRETED BY**

Beth Johnson, DVM  
 DACVIM

There is no visible free peritoneal effusion noted in these images.

Medial iliac lymph nodes are prominent in size with swollen capsular contour. Normal elongated shape (length to width ratio) is maintained. There is no loss of parenchymal detail.

The visible heart base (RA) and pericardium are unremarkable without obvious pathology noted in these images at this time. If cardiac function evaluation is desired, a full echocardiogram is recommended.

**IMAGING PERFORMED BY**

Kathleen Byrnes

**ULTRASONOGRAPHIC FINDINGS**

- This study is almost identical/static to the previous recent ultrasound with a diffusely moderately heterogeneous liver as well as a static, slightly more focal density in the mid to caudal liver, a static splenic nodule, static mildly reactive medial iliac lymph nodes, age related kidney changes and urinary bladder mineral debris.

**HOSPITAL NAME**

Monroe Road Animal Hospital

**INTERPRETATION OF THE FINDINGS & FURTHER RECOMMENDATIONS**

**REFERRING VET**

Dr. Davis

Given the static/unchanged nature of the ultrasound, previous recommendations regarding those changes are unchanged. Given the patient's newly reported gastrointestinal signs, however, other diagnostic recommendations to consider include a routine fecal/giardia exam if not recently evaluated.

**INVOICE**

74949

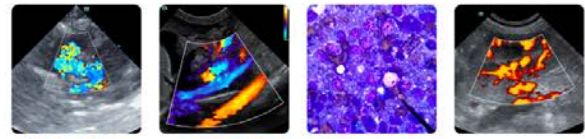
A gastrointestinal malabsorption panel (including cobalamin, folate, TLI and PLI) to Texas A&M GI Laboratory is recommended for further evaluation of GI and pancreatic function.

**DATE**

5/1/26

If not recently evaluated, a full general metabolic health screen is recommended to include CBC/Chem panel, electrolytes, and urinalysis.

A fecal enteropathogen PCR panel to Texas A&M GI Laboratory could be considered for further evaluation of possible infectious disease. Contact lab for recommendations on how long to discontinue antibiotics (if indicated) prior to obtaining a stool sample for submission.



**PATIENT**

Maya Perez

**SPECIES**

Canine

**BREED**

Yorkie x

**SEX**

Spayed Female

**AGE**

12 Years

**WEIGHT**

15.4 lbs

**INTERPRETED BY**

Beth Johnson, DVM  
 DACVIM

**IMAGING PERFORMED BY**

Kathleen Byrnes

**HOSPITAL NAME**

Monroe Road Animal  
 Hospital

**REFERRING VET**

Dr. Davis

**INVOICE**

74949

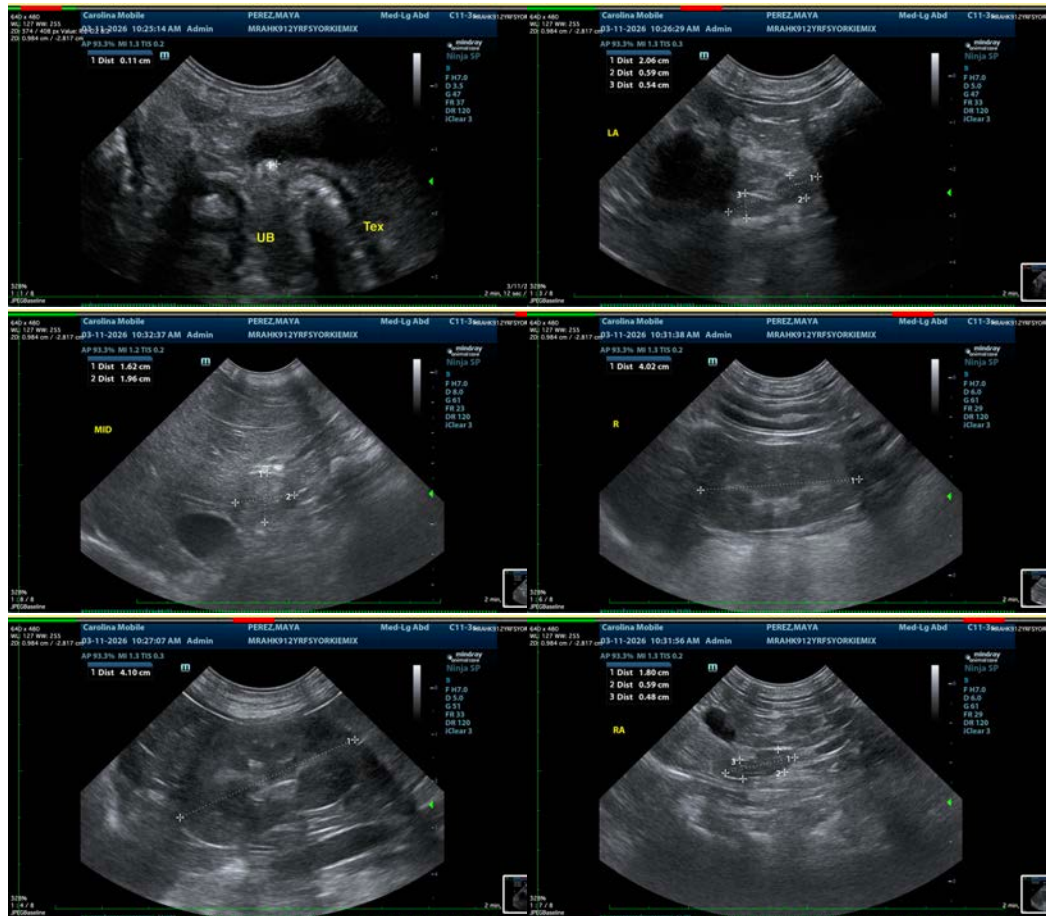**DATE**

5/1/26

A baseline cortisol is recommended. If baseline cortisol is less than 2, a full ACTH stimulation test is recommended to rule out hypoadrenocorticism.

In the meantime:

- Supportive/symptomatic medical management of clinical signs is recommended, including anti-emetics, gastroprotectants (+/- sucralfate, especially with any history of hematemesis), an appetite stimulant and fluid therapy if indicated, etc.
- Additionally, empirical deworming with a 5-day course of Panacur is recommended.
- A full course of empirical Helicobacter triple therapy could be considered.
- A probiotic, such a visbiome or proviable, may be helpful.
- Finally, if tolerated, a transition in diet could be considered, based on trial-and-error response with some options to consider including a gastrointestinal biome diet vs a hydrolyzed protein diet (sometimes several trials with different brands are necessary) vs an easy to digest, bland or low-fat diet vs other.





**PATIENT**

Maya Perez

**SPECIES**

Canine

**BREED**

Yorkie x

**SEX**

Spayed Female

**AGE**

12 Years

**WEIGHT**

15.4 lbs

**INTERPRETED BY**

Beth Johnson, DVM  
 DACVIM

**IMAGING PERFORMED BY**

Kathleen Byrnes

**HOSPITAL NAME**

Monroe Road Animal  
 Hospital

**REFERRING VET**

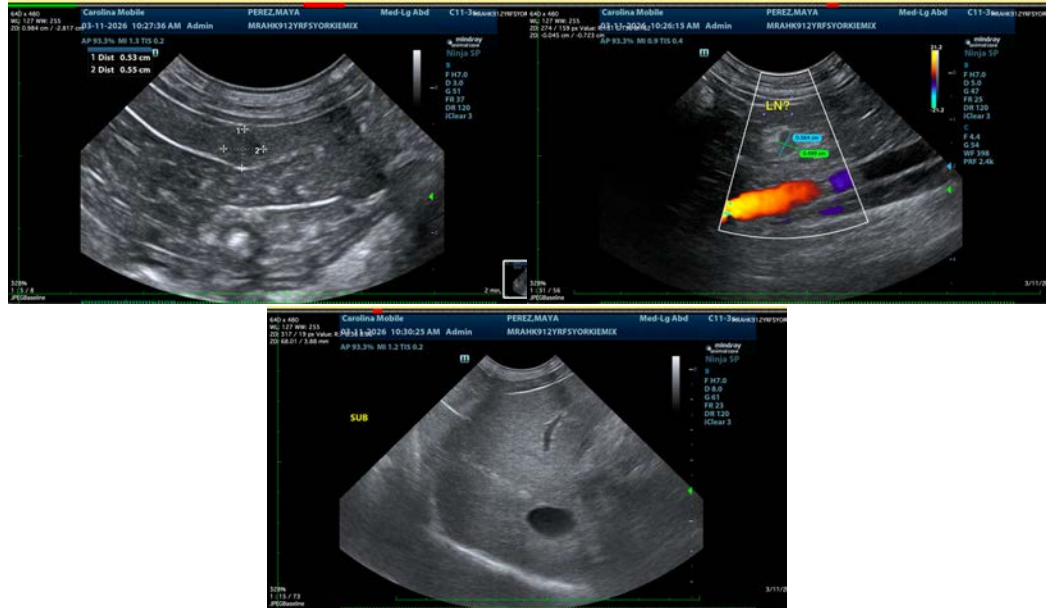
Dr. Davis

**INVOICE**

74949

**DATE**

5/1/26



The information and recommendations provided are based on the images presented by the referring veterinarian/sonographer. No evaluation can be communicated regarding pathology that was not visible in the image/video clips provided.

Thank you for this referral. If the clinical or image interpretation does not parallel your findings or if I can be of any further assistance please contact me.

**Beth Johnson, DVM, DACVIM**  
 info@sonopath.com