



## PATIENT

Mila Adlem

## SPECIES

Canine

## BREED

French Bulldog

## SEX

Spayed Female

## AGE

8 Years

## WEIGHT

10 kg

## INTERPRETED BY

Beth Johnson, DVM  
DACVIM

## IMAGING PERFORMED BY

Dr. Goeres

## HOSPITAL NAME

Kelowna Veterinary  
Hospital

## REFERRING VET

Dr. Sidhu

## INVOICE

74365

## DATE

4/9/26

## PRESENTING CLINICAL SIGNS

Recent bloodwork with dermatologist shows pan hypoproteinemia and low vitamin B12 levels. Diagnosed with pancreatitis a year ago. Hx of allergies, recently on hypo diet and apoquel. R/o protein losing enteropathy.

Abnormal PE/Chem/CBC/UA Results: PE unremarkable other than severe brachycephalic airway disease TLI > 50 (5-35) B12 120 (209-617) No significant proteinuria on recent UA TP 42 (55-75) Alb 23 (27-39) Glob 19 (24-40) specCPL in Oct 2025 WNL

## ULTRASONOGRAPHIC EXAMINATION OF THE ABDOMEN

### Urinary System

The urinary bladder is adequately distended with anechoic contents. No masses, inflammatory changes, echogenic sediment or cystoliths are observed. The urinary bladder, trigone and visible pelvic urethra are normal in thickness with a smooth mucosal surface.

The right kidney is normal in size (4.7 cm), shape and echogenicity. It has smooth peripheral margination. There is a normal 1:3 cortex to medulla ratio with appropriate corticomedullary distinction. There is no evidence of pyelectasia, mineral or infarcts observed.

The left kidney is normal in size (4.7 cm), shape and echogenicity. It has smooth peripheral margination. There is a normal 1:3 cortex to medulla ratio with appropriate corticomedullary distinction. There is no evidence of pyelectasia, mineral or infarcts observed.

### Adrenal Glands

The right adrenal gland is normal in size (0.65 cm at cranial pole and 0.67 cm at caudal pole), shape and overall architecture, echogenicity and echotexture. Visible surrounding vasculature appears normal.

The caudal pole of the left adrenal gland is normal in size (0.51 cm), shape and overall architecture, echogenicity and echotexture. Visible surrounding vasculature appears normal. The cranial pole is unable to be visualized in these images.

### Spleen

The spleen is subjectively normal in size with a normal smooth capsular contour. Parenchyma is appropriately finely textured and homogenous with normal echogenicity relative to surrounding tissue (hyperechoic to liver). No focal nodules or masses are observed. Splenic vasculature appears normal.

### Liver

The liver is subjectively normal in size with normal smooth curvilinear peripheral contour. Parenchyma is appropriately hypoechoic to the spleen in echogenicity and appropriately mildly coarse and homogenous in echotexture. No focal lesions are observed. Visible vasculature and biliary tree appear normal without distension or congestion.

The gallbladder is non-distended in size. The wall is smooth without visible thickening. Luminal contents are primarily anechoic. There is no evidence of cystic or common bile duct dilation.

### Gastrointestinal



## PATIENT

Mila Adlem

## SPECIES

Canine

## BREED

French Bulldog

## SEX

Spayed Female

## AGE

8 Years

## WEIGHT

10 kg

## INTERPRETED BY

Beth Johnson, DVM  
DACVIM

## IMAGING PERFORMED BY

Dr. Goeres

## HOSPITAL NAME

Kelowna Veterinary  
Hospital

## REFERRING VET

Dr. Sidhu

## INVOICE

74365

## DATE

4/9/26

The visible stomach wall is normal in thickness and layering. The lumen of the stomach is mildly distended with very echogenic reverberation artifact from intraluminal gas. There is no evidence of obstruction, foreign material, or infiltrative disease; however, visualization is partially inhibited by gas.

Small intestine is diffusely mildly thick with a relatively thick mucosa compared to other layers. Normal wall layering is preserved; however, the mucosa is more echogenic than normal and contains hyperechoic striations perpendicular to the lumen. The lumen of the small intestine is empty with no evidence of obstruction or foreign material. Duodenum wall measures approximately 0.70 cm thick with jejunal measurements averaging right at 0.40 cm.

The visible colon is normal in wall thickness (< 0.2 cm) and layering. Contents are consistent with normal formed feces and gas.

### **Pancreas**

The pancreas that is observed appears appropriately isoechoic to surrounding omental fat. Visible capsule is smooth and normal in contour. Visible pancreatic parenchyma is homogenous and unremarkable. There is no visible pancreatic duct dilation. There is no evidence of active peripancreatic inflammation.

### **Free Abdomen**

There is no visible free peritoneal effusion noted in these images.

There is no apparent pathologic lymphadenopathy noted in these images.

## **ULTRASONOGRAPHIC FINDINGS**

- Lymphangiectasia – Small bowel findings are most consistent with lacteal dilation. These findings can be observed with protein-losing enteropathies caused by either primary lymphangiectasia or primary infiltrative inflammatory disease with secondary lymphangiectasia. Infiltrative neoplasia is possible but considered less likely. Histopathology is necessary to definitively determine underlying cause.

## **INTERPRETATION OF THE FINDINGS & FURTHER RECOMMENDATIONS**

- A gastrointestinal malabsorption panel (including cobalamin, folate, TLI and PLI) to Texas A&M GI Laboratory is recommended for further evaluation of GI and pancreatic function.
- A baseline cortisol is recommended. If baseline cortisol is less than 2, a full ACTH stimulation test is recommended to rule out hypoadrenocorticism.
- Ideally, biopsies of the GI tract are recommended to definitively diagnose and therefore manage the infiltrative bowel process.
- If biopsies cannot be obtained safely due to low albumin or patient stability, etc., empirical therapies could include diet change to an ultra-low-fat diet, empirical deworming with a 5-day course of Panacur, cobalamin supplementation, a probiotic and prednisolone (if not contraindicated based on patient contraindications, co-morbidities, etc.).
- Calcium monitoring, and supplementation, if necessary, is also recommended.



**PATIENT**

Mila Adlem

**SPECIES**

Canine

**BREED**

French Bulldog

**SEX**

Spayed Female

**AGE**

8 Years

**WEIGHT**

10 kg

**INTERPRETED BY**

Beth Johnson, DVM  
DACVIM

**IMAGING PERFORMED BY**

Dr. Goeres

**HOSPITAL NAME**

Kelowna Veterinary  
Hospital

**REFERRING VET**

Dr. Sidhu

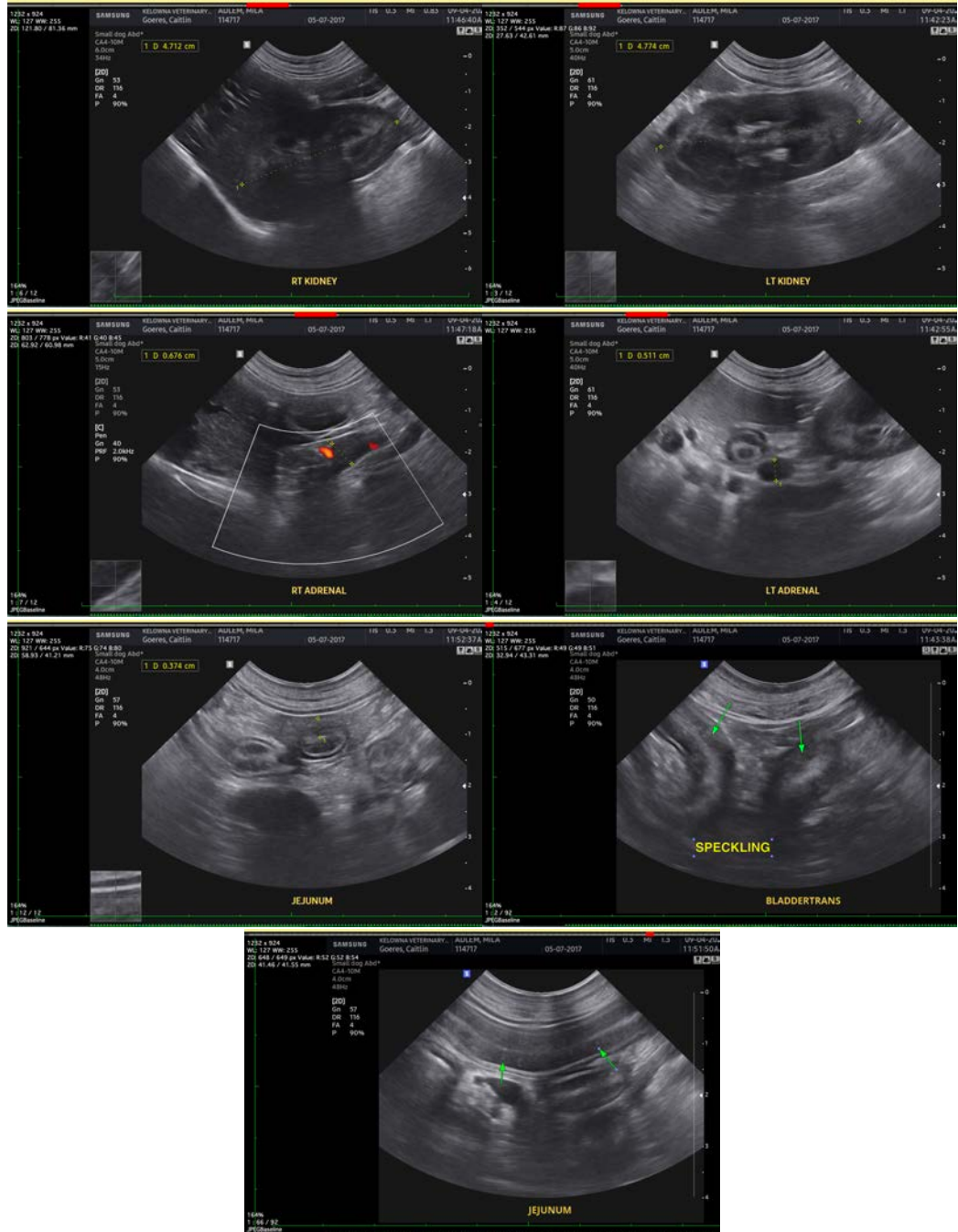
**INVOICE**

74365

**DATE**

4/9/26

- Additionally, if patient's coagulation status is otherwise appropriate, anti-thrombotics such as clopidogrel or low dose aspirin may also be warranted.





## PATIENT

Mila Adlem

## SPECIES

Canine

## BREED

French Bulldog

## SEX

Spayed Female

## AGE

8 Years

## WEIGHT

10 kg

## INTERPRETED BY

Beth Johnson, DVM  
DACVIM

## IMAGING PERFORMED BY

Dr. Goeres

## HOSPITAL NAME

Kelowna Veterinary  
Hospital

## REFERRING VET

Dr. Sidhu

## INVOICE

74365

## DATE

4/9/26

The information and recommendations provided are based on the images presented by the referring veterinarian/sonographer. No evaluation can be communicated regarding pathology that was not visible in the image/video clips provided.

Thank you for this referral. If the clinical or image interpretation does not parallel your findings or if I can be of any further assistance please contact me.

**Beth Johnson, DVM, DACVIM**  
info@sonopath.com