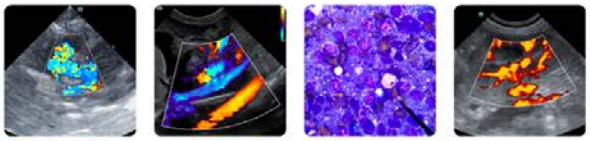

PATIENT
Abby Mannix

SPECIES
Canine

BREED
Shepherd x

SEX
Spayed Female

AGE
10 Years 10 Months

WEIGHT
53.4

INTERPRETED BY
Beth Johnson, DVM DACVIM

IMAGING PERFORMED BY
Heather

HOSPITAL NAME
Animal Care Clinic of Flanders

REFERRING VET
Dr. Hallihan

INVOICE
74315

DATE
4/9/26

PRESENTING CLINICAL SIGNS

Worsening anemia (regen), lethargic diagnosed with addisions - mass in ear cranial - bleeding in ear canal, pre-operative u/s, k+ high, just started prednisone SID 2.5mg yesterday and zycortal 2ml every 25 days.

Abnormal PE/Chem/CBC/UA Results: hct-26%, hct was 31% 2 days prior, relic - 495, k+- 6.7, na - 140, chloride - 107, acth stem pre- 2.5, post .53

ULTRASONOGRAPHIC EXAMINATION OF THE ABDOMEN

Urinary System

The urinary bladder is adequately distended with anechoic contents. No masses, inflammatory changes, echogenic sediment or cystoliths are observed. The urinary bladder, trigone and visible pelvic urethra are normal in thickness with a smooth mucosal surface.

The right kidney is normal is size (6.0 cm), shape and echogenicity. It has smooth peripheral margination. There is a normal 1:3 cortex to medulla ratio with appropriate corticomedullary distinction. There is no evidence of pyelectasia, mineral or infarcts observed.

The left kidney is normal is size (6.0 cm), shape and echogenicity. It has smooth peripheral margination. There is a normal 1:3 cortex to medulla ratio with appropriate corticomedullary distinction. There is no evidence of pyelectasia, mineral or infarcts observed.

Adrenal Glands

The area of the right adrenal gland is examined without evident adrenal gland pathology.

The left adrenal gland is enlarged in size (1.6 cm at cranial pole and 2.7 cm at caudal pole), with mild heterogeneous parenchymal changes diffusely. Swollen capsular expansion is noted at the larger (caudal) pole, which measures 2.8 cm in diameter, without definitive visible capsular escape or vascular invasion noted in these images at this time.

Spleen

The spleen is subjectively large in size with irregular or scalloped margins as a result of multifocal heterogeneous, primarily hypoechoic nodules/masses of varying sizes throughout the parenchyma, and one large, irregular, hypoechoic, expansive, disruptive mass off the caudal aspect measuring approximately 8.2 cm in size. Trace free fluid is noted adjacent to the largest mass.

Liver

Liver is subjectively enlarged with mildly irregular margins. Parenchyma is mildly heterogenous characterized by multiple poorly defined hypoechoic nodules within otherwise hyperechoic liver parenchyma. Visible vasculature and biliary tree appear normal without distension or congestion

The gallbladder is non-distended in size. The wall is smooth without visible thickening. Luminal contents are primarily anechoic. There is no evidence of cystic or common bile duct dilation.

Gastrointestinal

The visible stomach wall is normal in thickness and layering. The lumen of the stomach is empty with no evidence of obstruction, foreign material or infiltrative disease. Pyloric outflow tract appears patent.

PATIENT
Abby Mannix

SPECIES
Canine

BREED
Shepherd x

SEX
Spayed Female

AGE
10 Years 10 Months

WEIGHT
53.4

INTERPRETED BY
Beth Johnson, DVM DACVIM

IMAGING PERFORMED BY
Heather

HOSPITAL NAME
Animal Care Clinic of Flanders

REFERRING VET
Dr. Hallihan

INVOICE
74315

DATE
4/9/26

The visible small intestines are normal in wall thickness and layering. Small intestinal motility appears adequate (1-3 contractions per min). The lumen of the small intestine is empty with no evidence of obstruction, foreign material or infiltrative disease.

The visible colon is normal in wall thickness (< 0.2 cm) and layering. Contents are consistent with normal formed feces and gas.

Pancreas

The pancreas that is observed appears appropriately isoechoic to surrounding omental fat. Visible capsule is smooth and normal in contour. Visible pancreatic parenchyma is homogenous and unremarkable. There is no visible pancreatic duct dilation. There is no evidence of active peripancreatic inflammation.

Free Abdomen

There is a small amount of free fluid adjacent to the spleen.

There is no apparent pathologic lymphadenopathy noted in these images.

ULTRASONOGRAPHIC FINDINGS

- The appearance of the spleen is concerning for infiltrative neoplasia such as sarcoma versus round cell neoplasia versus other, especially in the face of concurrent free fluid. Having said that, a benign extramedullary hematopoiesis, cysts, hematomas, other can't be ruled out without tissue sampling.

- Mildly heterogenous liver – These changes are most consistent with benign processes such as nodular hyperplasia, steroid (vacuolar) hepatopathy, extramedullary hematopoiesis or possibly chronic inflammatory disease and less commonly infiltrative round cell or metastatic neoplasia.

- The left adrenal mass with a suspect flat right adrenal gland is concerning for a primary functioning adrenal tumor such as an adenoma versus adenocarcinoma versus other. Having said that, other differentials for the enlarged left gland/mass include pheochromocytoma or even a metastatic process. This finding is unexpected with the reported recent diagnosis of Addison's disease, but a flat stim can occur with some varieties of adrenal tumors. Therefore, further investigation is warranted.

INTERPRETATION OF THE FINDINGS & FURTHER RECOMMENDATIONS

Three view thoracic radiographs are recommended for further assessment of cardio-pulmonary status as well as to further evaluate for any evidence of metastatic disease, if not recently evaluated.

A blood pressure is recommended if not recently evaluated.

Advanced imaging of the abdomen +/- thorax in the form of a contrast CT scan for further investigation of the unexpected adrenal gland changes, the splenic mass, etc. could be considered.

Additionally, or pending results of that workup, tissue sampling is recommended. Sampling of the free abdominal fluid could be considered if patient's coagulation status is appropriate, and fine needle aspirates of the splenic masses +/- liver are recommended.

PATIENT

Abby Mannix

SPECIES

Canine

BREED

Shepherd x

SEX

Spayed Female

AGE

10 Years 10 Months

WEIGHT

53.4

INTERPRETED BY

Beth Johnson, DVM DACVIM

IMAGING PERFORMED BY

Heather

HOSPITAL NAME

Animal Care Clinic of Flanders

REFERRING VET

Dr. Hallihan

INVOICE

74315

DATE

4/9/26

Other than supportive/symptomatic medical management of clinical signs, further treatment recommendations are largely dependent on results of the above.

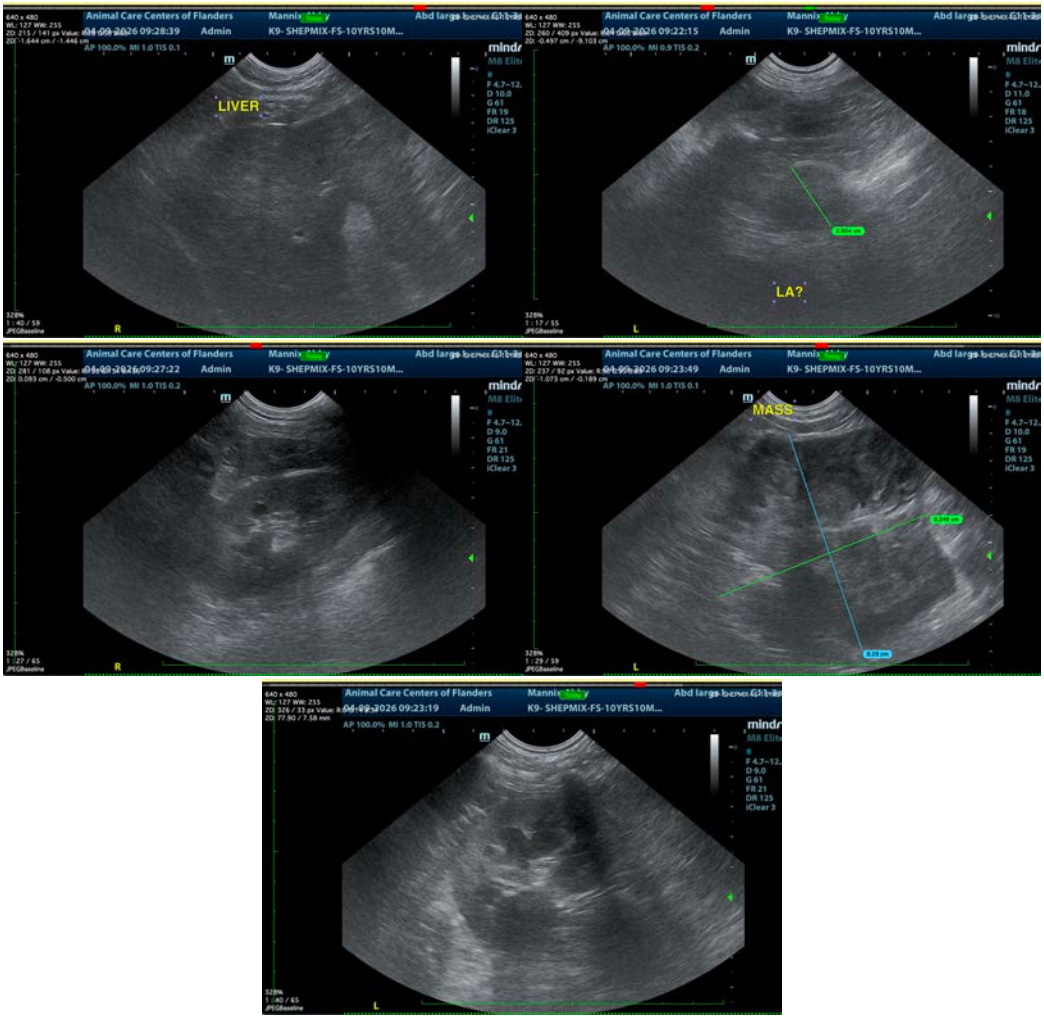

The information and recommendations provided are based on the images presented by the referring veterinarian/sonographer. No evaluation can be communicated regarding pathology that was not visible in the image/video clips provided.

Thank you for this referral. If the clinical or image interpretation does not parallel your findings or if I can be of any further assistance please contact me.

Beth Johnson, DVM, DACVIM
info@sonopath.com