



PATIENT

Walter Richardson

SPECIES

Feline

BREED

DLH

SEX

Neutered Male

AGE

10 Years

WEIGHT

9.8 lbs

INTERPRETED BY

Beth Johnson, DVM
 DACVIM

IMAGING PERFORMED BY

Kelly Reschny

HOSPITAL NAME

Beamsville Animal
 Hospital

REFERRING VET

Dr. Hagar

INVOICE

74287

DATE

4/8/26

PRESENTING CLINICAL SIGNS

Seen in Mid February initially for not eating. Mild icterus at time noticed on ear tips. Mucus membranes at that time seemed slightly "muddy" not fully pink. Opted to do blood panel at the time.

Current Medications: Mirtazipine ear gel to stimulate appetite as of April 6th, tried Aventi liver support chews but would not eat them.

Abnormal PE/Chem/CBC/UA Results: Fecal - Negative, Bloodwork - ALT 641, ALP 273

ULTRASONOGRAPHIC EXAMINATION OF THE ABDOMEN

Urinary System

Urinary bladder is adequately distended. It has a normal uniform wall thickness. Contents include primarily anechoic fluid with a large amount of echogenic non-shadowing debris, most consistent with exfoliated cells, crystals, mucous and/or small blood clots likely combined with incidental suspended lipid. Both sterile inflammation as well as urinary tract infection can present with echogenic debris. No masses or definitive cystoliths are observed. The trigone and visible pelvic urethra are normal in thickness with a smooth mucosal surface.

Kidneys are overall normal in size and shape with smooth peripheral margination. A normal 1:3 cortex to medulla ratio is maintained. The medulla and cortices are uniform in texture with some mild increased cortical echogenicity and mild loss of corticomedullary distinction, expected in this age patient. There is no evidence of pyelectasia, mineral or infarcts observed. Left kidney measures 3.54 cm. Right kidney measures 3.58 cm.

Adrenal Glands

The right adrenal gland is normal in size (0.36 cm), shape and overall architecture, echogenicity and echotexture. Visible surrounding vasculature appears normal.

The left adrenal gland is normal in size (0.43 cm), shape and overall architecture, echogenicity and echotexture. Visible surrounding vasculature appears normal.

Spleen

The spleen measures right at the upper end of normal limits for size at 1.0 cm thick at the hilus, with a mildly swollen but smooth capsule. Parenchyma is normal and homogenous in echogenicity and echotexture. No focal nodules or masses are observed. Splenic vasculature appears normal.

Liver

Liver is subjectively enlarged (swollen contour) with a diffusely mildly coarse architecture and subtly increased portal markings. Mildly mixed echogenic changes are noted diffusely. No focal lesions are observed. Visible vasculature and biliary tree appear normal without distension or congestion.

The gallbladder is non-distended in size. The wall is smooth without visible thickening. Luminal contents are primarily anechoic. There is no evidence of cystic or common bile duct dilation.



PATIENT

Walter Richardson

SPECIES

Feline

BREED

DLH

SEX

Neutered Male

AGE

10 Years

WEIGHT

9.8 lbs

INTERPRETED BY

Beth Johnson, DVM
 DACVIM

IMAGING PERFORMED BY

Kelly Reschny

HOSPITAL NAME

Beamsville Animal
 Hospital

REFERRING VET

Dr. Hagar

INVOICE

74287

DATE

4/8/26

Gastrointestinal

The visible stomach wall is normal in thickness and layering. The lumen of the stomach is empty with no evidence of obstruction, foreign material or infiltrative disease. Pyloric outflow tract appears patent.

The visible small intestines are normal in wall thickness and layering. Small intestinal motility appears adequate (1-3 contractions per min). The lumen of the small intestine is empty with no evidence of obstruction, foreign material or infiltrative disease.

The visible colon is normal in wall thickness (< 0.2 cm) and layering. Contents are consistent with normal formed feces and gas.

Pancreas

The pancreas that is observed appears appropriately isoechoic to surrounding omental fat. Visible capsule is smooth and normal in contour. Visible pancreatic parenchyma is homogenous and unremarkable. There is no visible pancreatic duct dilation. There is no evidence of active peripancreatic inflammation.

Free Abdomen

There is no visible free peritoneal effusion noted in these images.

There is no apparent pathologic lymphadenopathy noted in these images.

PRIMARY FINDINGS

- The liver changes are non-specific but could represent a microscopic hepatopathy such as bacterial or lymphoplasmacytic cholangiohepatitis, hepatic lipidosis, other benign infectious or inflammatory hepatopathy, or infiltrative neoplasia such as round cell neoplasia versus other, which can't be ruled out without tissue sampling.
- Mild splenomegaly- can be associated with congestion caused by sedation (if sedated) but can also be associated with diffuse infiltrative disease. Both benign conditions such as extramedullary hematopoiesis, lymphoid hyperplasia, amyloidosis as well as infiltrative neoplastic diseases such as round cell neoplasia should be considered.

SECONDARY FINDINGS

- Moderate age related kidney changes.
- Moderate amount of echogenic urinary bladder debris.

INTERPRETATION OF THE FINDINGS & FURTHER RECOMMENDATIONS

If not recently evaluated, a urinalysis and, if indicated based on urinalysis results, urine culture is recommended. If protein is present in an otherwise quiet sediment, protein quantification with a urine protein to creatinine ratio is recommended.

Additionally, a T4 +/- free T4 is recommended.

Fine needle aspirates of the liver and spleen could be considered if patient's coagulation status is appropriate.



PATIENT

Walter Richardson

SPECIES

Feline

BREED

DLH

SEX

Neutered Male

AGE

10 Years

WEIGHT

9.8 lbs

INTERPRETED BY

Beth Johnson, DVM
 DACVIM

IMAGING PERFORMED BY

Kelly Reschny

HOSPITAL NAME

Beamsville Animal
 Hospital

REFERRING VET

Dr. Hagar

INVOICE

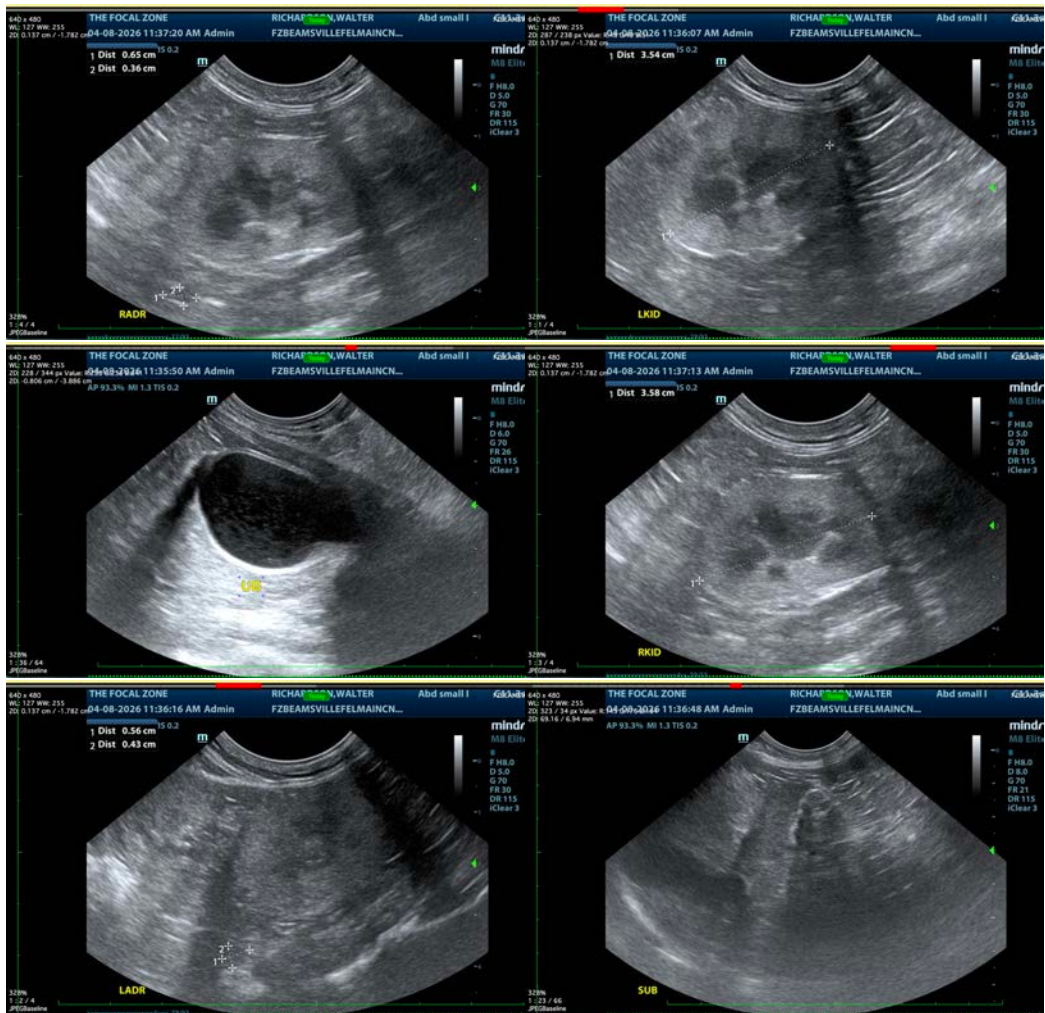74287

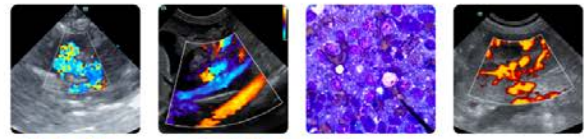
DATE

4/8/26

If patient was believed to be inappetent prior to developing increased liver enzymes, that may further support hepatic lipidosis as a secondary problem, with the underlying cause for decreased appetite being the primary concern. In that case, further evaluation for causes of decreased appetite including other underlying gastrointestinal disease, constipation, pain such as dental, orthopedic, other pain, respiratory disease, oropharyngeal disease, cardiac disease, neurologic disease, etc. in addition to workup for possible primary hepatopathies.

In the meantime, treatment recommendations include fluid therapy, anti-emetics, gastroprotectants, hepatic nutraceuticals such as ursodiol and/or Denamarin, and broad-spectrum antibiotics. Nutritional support is critical to prevent/manage concurrent hepatic lipidosis, so appetite stimulants and/or, if indicated, feeding tube placement is also recommended.





PATIENT

Walter Richardson

SPECIES

Feline

BREED

DLH

SEX

Neutered Male

AGE

10 Years

WEIGHT

9.8 lbs

INTERPRETED BY

Beth Johnson, DVM
DACVIM

IMAGING PERFORMED BY

Kelly Reschny

HOSPITAL NAME

Beamsville Animal
Hospital

REFERRING VET

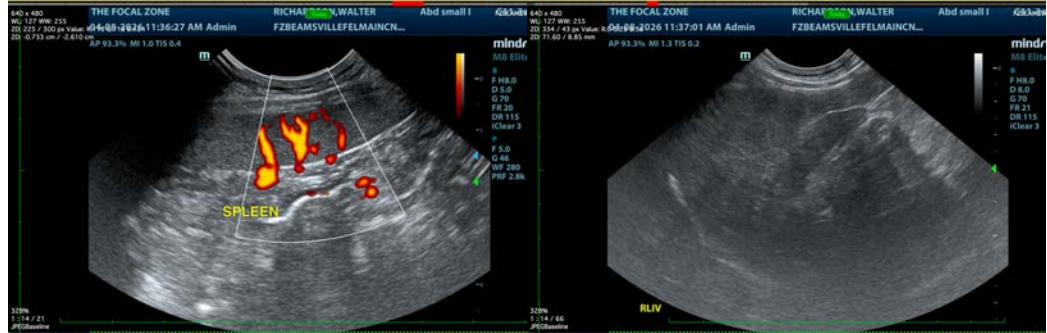
Dr. Hagar

INVOICE

74287

DATE

4/8/26



The information and recommendations provided are based on the images presented by the referring veterinarian/sonographer. No evaluation can be communicated regarding pathology that was not visible in the image/video clips provided.

Thank you for this referral. If the clinical or image interpretation does not parallel your findings or if I can be of any further assistance please contact me.

Beth Johnson, DVM, DACVIM
info@sonopath.com