



PATIENT

Lucas Valyou

SPECIES

Canine

BREED

Schnauzer X

SEX

MN

AGE

8 years

WEIGHT

50 lbs

INTERPRETED BY

Beth Johnson, DVM
DACVIM

IMAGING PERFORMED BY

Sara Hansen

HOSPITAL NAME

RAD Pets

REFERRING VET

Dr. Mills

INVOICE

11640

DATE

4/8/2026

PRESENTING CLINICAL SIGNS

Clinical Exam Findings: left forelimb amp last tuesday, refuses to eat after surgery, has been 8 days, placed feeding tube and receiving low fat GI through tube now, jaundice, bruising along entire ventral abdomen and down both hind legs.

ABNORMAL Labwork Values all normal, including platelets, clotting times not done
Current Medications: cerenia, metoclopramide, buprenorphine.

ULTRASONOGRAPHIC EXAMINATION OF THE ABDOMEN

Urinary System

The urinary bladder is adequately distended with anechoic contents. No masses, inflammatory changes, echogenic sediment or cystoliths are observed. The urinary bladder, trigone and visible pelvic urethra are normal in thickness with a smooth mucosal surface.

Prostate is normal in size, echotexture, and echogenicity for a neutered male.

The right kidney is normal is size (6.79 cm), shape and echogenicity. It has smooth peripheral margination. There is a normal 1:3 cortex to medulla ratio with appropriate corticomedullary distinction. There is no evidence of pyelectasia, mineral or infarcts observed.

The left kidney is normal is size (6.67 cm), shape and echogenicity. It has smooth peripheral margination. There is a normal 1:3 cortex to medulla ratio with appropriate corticomedullary distinction. There is no evidence of pyelectasia, mineral or infarcts observed.

Adrenal Glands

The right adrenal gland is normal in size (1.0 cm at cranial pole and 0.56 cm at caudal pole), shape and overall architecture, echogenicity and echotexture. Visible surrounding vasculature appears normal.

The left adrenal gland is normal in size (0.65 cm at cranial pole and 0.67 cm at caudal pole), shape and overall architecture, echogenicity and echotexture. Visible surrounding vasculature appears normal.

Spleen

Spleen is subjectively normal in size with a normal smooth capsular contour. Parenchyma is appropriately finely textured and homogenous with normal echogenicity relative to surrounding tissue (hyperechoic to liver). Multifocal well-demarcated hyperechoic homogenous nodules are noted.

Splenic vasculature appears normal.

Liver

The liver is subjectively normal in size with normal smooth curvilinear peripheral contour. Parenchyma is appropriately hypoechoic to the spleen in echogenicity and appropriately mildly coarse and homogenous in echotexture. No focal lesions are observed. Visible vasculature and biliary tree appear normal without distension or congestion.

The gallbladder is non-distended in size. The wall is smooth without visible thickening. Luminal contents are primarily anechoic. There is no evidence of cystic or common bile duct dilation.

Gastrointestinal



PATIENT

Lucas Valyou

SPECIES

Canine

BREED

Schnauzer X

SEX

MN

AGE

8 years

WEIGHT

50 lbs

INTERPRETED BY

Beth Johnson, DVM
DACVIM

IMAGING PERFORMED BY

Sara Hansen

HOSPITAL NAME

RAD Pets

REFERRING VET

Dr. Mills

INVOICE

11640

DATE

4/8/2026

The visible stomach wall is normal in thickness and layering. The lumen is mildly distended with primarily fluid as well as some echogenic non-shadowing luminal contents and gas consistent with normal chyme. There is no evidence of obstruction, foreign material, or infiltrative disease. Pyloric outflow tract appears patent.

The visible small intestines are normal in wall thickness and layering. Small intestinal motility appears adequate (1-3 contractions per min). The lumen of the small intestine is empty with no evidence of obstruction, foreign material or infiltrative disease.

The visible colon is normal in wall thickness (< 0.2 cm) and layering. Contents are consistent with normal formed feces and gas.

Pancreas

The pancreas that is observed appears appropriately isoechoic to surrounding omental fat. Visible capsule is smooth and normal in contour. Visible pancreatic parenchyma is homogenous and unremarkable. There is no visible pancreatic duct dilation. There is no evidence of active peripancreatic inflammation.

Free Abdomen

There is subjectively, very subtly, some possibly enhanced hyperechoic tissue in the cranial abdomen adjacent to and caudal too the stomach. However, this change is subtle.

There is no apparent pathologic lymphadenopathy noted in these images.

PRIMARY FINDINGS

- This is a largely unremarkable/normal structural abdomen without a definitive ultrasonographically visible intraabdominal explanation for patient's reported bruising, etc. Having said that, early or emerging low-grade pancreatitis can't be definitively ruled out.

SECONDARY FINDINGS

- Hyperechoic splenic nodules – most consistent with benign myelolipomas. Other differentials such as fibrosis or calcification caused by old hematomas or infarcts, chronic inflammation, granulomatous disease or metastatic disease cannot be ruled out, but are considered less likely.

INTERPRETATION OF THE FINDINGS & FURTHER RECOMMENDATIONS

Full assessment of patient's coagulation status is recommended if not recently evaluated.

A gastrointestinal malabsorption panel (including cobalamin, folate, TLI and PLI) to Texas A&M GI Laboratory is recommended for further evaluation of GI and pancreatic function.

A baseline cortisol is recommended. If baseline cortisol is less than 2, a full ACTH stimulation test is recommended to rule out hypoadrenocorticism.

Additional recommendations given the bruising, are in part dependent on the reason for the amputation i.e. if it was a mast cell tumor or something that could have degranulated or could be contributing to the bruising as a possibility.



PATIENT

Lucas Valyou

SPECIES

Canine

BREED

Schnauzer X

SEX

MN

AGE

8 years

WEIGHT

50 lbs

INTERPRETED BY

Beth Johnson, DVM
 DACVIM

IMAGING PERFORMED BY

Sara Hansen

HOSPITAL NAME

RAD Pets

REFERRING VET

Dr. Mills

INVOICE

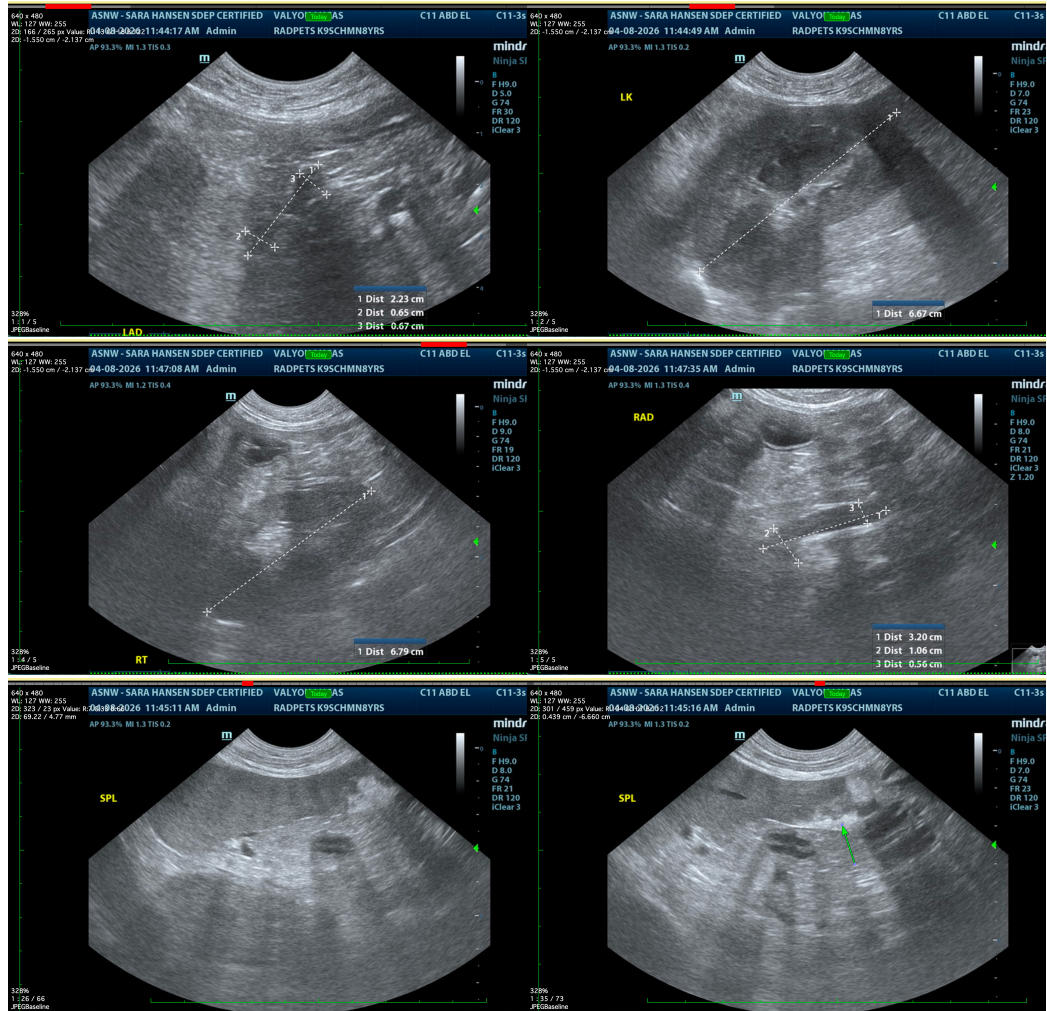
11640

DATE

4/8/2026

Three view thoracic radiographs are recommended for further assessment of cardio-pulmonary status as well as to further evaluate for any evidence of metastatic disease, if not recently evaluated.

Other than supportive/symptomatic medical management of clinical signs, further treatment recommendations are largely dependent on results of the above.



The information and recommendations provided are based on the images presented by the referring veterinarian/sonographer. No evaluation can be communicated regarding pathology that was not visible in the image/video clips provided.

Thank you for this referral. If the clinical or image interpretation does not parallel your findings or if I can be of any further assistance please contact me.

Beth Johnson, DVM, DACVIM
 info@sonopath.com