



PATIENT

Lennox Tanner

SPECIES

Canine

BREED

Labrador

SEX

MN

AGE

1 year

WEIGHT

73 lbs

INTERPRETED BY

Beth Johnson, DVM
DACVIM

IMAGING PERFORMED BY

Dr. Julia Bakker

HOSPITAL NAME

Orange Blossom
Veterinary Imaging

REFERRING VET

Dr. Kylie Marr

INVOICE

11647

DATE

4/8/2026

PRESENTING CLINICAL SIGNS

With the BW + USG being dilute there is concern that the kidneys aren't functioning efficiently as we would expect, abd u/s to look closer at the status of the kidneys.

Abnormal PE/Chem/CBC/UA Results: USG 1.016 BUN 34 Creat 2.5 SDMA 20.5

ULTRASONOGRAPHIC EXAMINATION OF THE ABDOMEN

Urinary System

The urinary bladder is adequately distended with anechoic contents. No masses, inflammatory changes, echogenic sediment or cystoliths are observed. The urinary bladder, trigone and visible pelvic urethra are normal in thickness with a smooth mucosal surface.

Prostate is normal in size, echotexture, and echogenicity for a neutered male.

Kidneys are bilaterally normal in size, irregular and diffusely echogenic with decreased corticomedullary distinction and poor visualization of internal architecture. There is no pyelectasia noted and no mineral is observed. Left kidney measures 5.73 cm, and the right kidney measures 6.15 cm.

Adrenal Glands

The right adrenal gland is normal in size (0.83 cm at cranial pole and 0.62 cm at caudal pole), shape and overall architecture, echogenicity and echotexture. Visible surrounding vasculature appears normal.

The left adrenal gland is normal in size (0.66 cm at cranial pole and 0.65 cm at caudal pole), shape and overall architecture, echogenicity and echotexture. Visible surrounding vasculature appears normal.

Spleen

The spleen is subjectively normal in size with a normal smooth capsular contour. Parenchyma is appropriately finely textured and homogenous with normal echogenicity relative to surrounding tissue (hyperechoic to liver). No focal nodules or masses are observed. Splenic vasculature appears normal.

Liver

The liver is subjectively normal in size with normal smooth curvilinear peripheral contour. Parenchyma is appropriately hypoechoic to the spleen in echogenicity and appropriately mildly coarse and homogenous in echotexture. No focal lesions are observed. Visible vasculature and biliary tree appear normal without distension or congestion.

The gallbladder is non-distended in size. The wall is smooth without visible thickening. Luminal contents are primarily anechoic. There is no evidence of cystic or common bile duct dilation.

Gastrointestinal

The visible stomach wall is normal in thickness and layering. The stomach is moderately distended with echogenic non-shadowing luminal contents and gas consistent with normal ingesta. There is no evidence of obstruction, foreign material or infiltrative disease. If patient was appropriately fasted, delayed gastric emptying could be considered. Non-shadowing foreign material is considered less likely but cannot be definitively ruled out.



PATIENT

Lennox Tanner

SPECIES

Canine

BREED

Labrador

SEX

MN

AGE

1 year

WEIGHT

73 lbs

INTERPRETED BY

Beth Johnson, DVM
DACVIM

IMAGING PERFORMED BY

Dr. Julia Bakker

HOSPITAL NAME

Orange Blossom
Veterinary Imaging

REFERRING VET

Dr. Kylie Marr

INVOICE

11647

DATE

4/8/2026

If clinical signs are consistent (vomiting, etc.), recommendations include supportive medical care, 24 hours fasting and re-image.

The visible small intestines are normal in wall thickness and layering. Small intestinal motility appears adequate (1-3 contractions per min). The lumen of the small intestine is mildly distended with echogenic non-shadowing luminal contents and gas consistent with normal ingesta. There is no evidence of obstruction or foreign material noted.

The visible colon is normal in wall thickness (< 0.2 cm) and layering. Contents are consistent with normal formed feces and gas.

Pancreas

The pancreas that is observed appears appropriately isoechoic to surrounding omental fat. Visible capsule is smooth and normal in contour. Visible pancreatic parenchyma is homogenous and unremarkable. There is no visible pancreatic duct dilation. There is no evidence of active peripancreatic inflammation.

Free Abdomen

There is no visible free peritoneal effusion noted in these images.

There is no apparent pathologic lymphadenopathy noted in these images.

ULTRASONOGRAPHIC FINDINGS

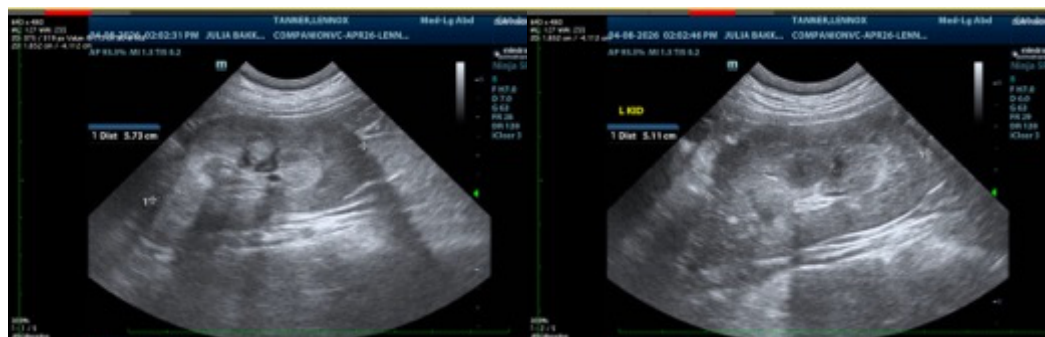
- Mild/subtle bilateral chronic kidney disease changes. Renal dysplasia is a differential, especially given patient's young age.

INTERPRETATION OF THE FINDINGS & FURTHER RECOMMENDATIONS

If not recently evaluated, a blood pressure is recommended.

Further investigation for possible acute on chronic kidney insult is recommended including infections such as urinary tract infections, leptospirosis, toxin exposure, etc.

Ultimately, however, beginning medical management for emerging chronic kidney disease while monitoring azotemia may be indicated. This should include supportive/symptomatic management of clinical signs, management of any concurrent proteinuria or hypertension, electrolyte abnormalities, dehydration, etc. and could include, if tolerated, transition to a kidney friendly diet.





PATIENT

Lennox Tanner

SPECIES

Canine

BREED

Labrador

SEX

MN

AGE

1 year

WEIGHT

73 lbs

INTERPRETED BY

Beth Johnson, DVM
DACVIM

IMAGING PERFORMED BY

Dr. Julia Bakker

HOSPITAL NAME

Orange Blossom
Veterinary Imaging

REFERRING VET

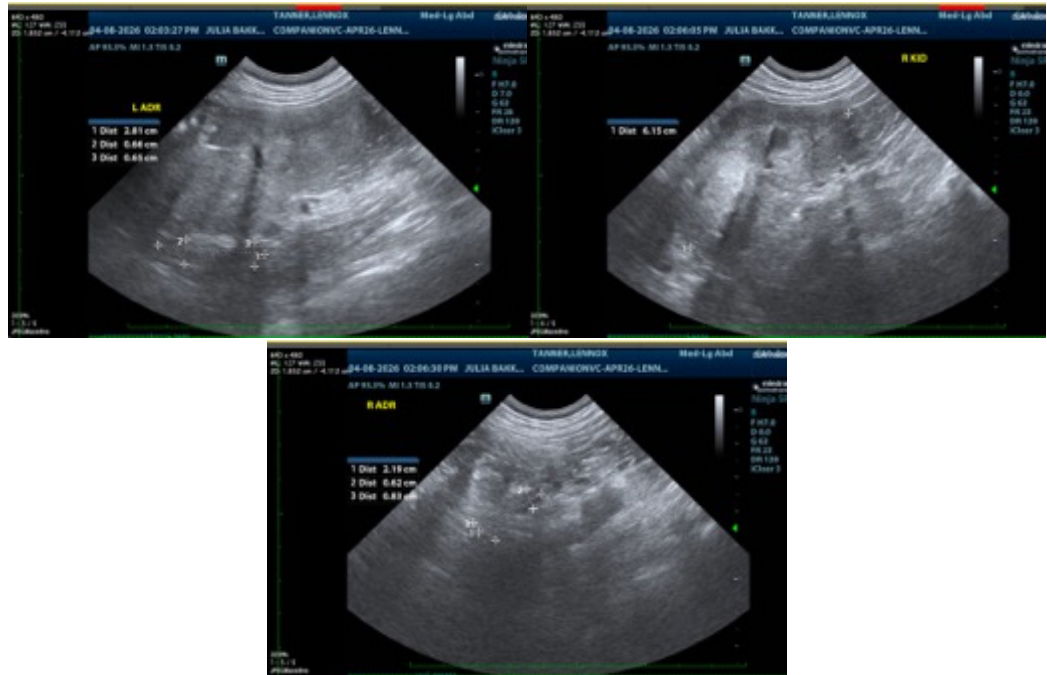Dr. Kylie Marr

INVOICE

11647

DATE

4/8/2026



The information and recommendations provided are based on the images presented by the referring veterinarian/sonographer. No evaluation can be communicated regarding pathology that was not visible in the image/video clips provided.

Thank you for this referral. If the clinical or image interpretation does not parallel your findings or if I can be of any further assistance please contact me.

Beth Johnson, DVM, DACVIM
info@sonopath.com