



PATIENT

Tex Boyer

SPECIES

Canine

BREED

Terrier x

SEX

Neutered Male

AGE

10 Years 4 Months

WEIGHT

18 lbs

INTERPRETED BY

Beth Johnson, DVM
 DACVIM

IMAGING PERFORMED BY

Kathleen Byrnes

HOSPITAL NAME

Animal Hospital of
 Lake Brandt

REFERRING VET

Dr. Smith

INVOICE

74264

DATE

4/7/26

PRESENTING CLINICAL SIGNS

P presented for diarrhea and vomiting. P lives on a farm. Owner reports this is the sickest hes ever been, some blood in diarrhea. BAR for US- some liquid diarrhea during scan.

ULTRASONOGRAPHIC EXAMINATION OF THE ABDOMEN

Urinary System

The urinary bladder is adequately distended with anechoic contents. No masses, inflammatory changes, echogenic sediment or cystoliths are observed. The urinary bladder, trigone and visible pelvic urethra are normal in thickness with a smooth mucosal surface.

Prostate is normal in size, echotexture and echogenicity for a neutered male.

The right kidney is normal is size (4.19 cm), shape and echogenicity. It has smooth peripheral margination. There is a normal 1:3 cortex to medulla ratio with appropriate corticomedullary distinction. There is no evidence of pyelectasia, mineral or infarcts observed.

The left kidney is normal is size (4.33 cm), shape and echogenicity. It has smooth peripheral margination. There is a normal 1:3 cortex to medulla ratio with appropriate corticomedullary distinction. There is no evidence of pyelectasia, mineral or infarcts observed.

Adrenal Glands

The right adrenal gland is normal in size (1.0 cm at cranial pole and 0.60 cm at caudal pole), shape and overall architecture, echogenicity and echotexture. Visible surrounding vasculature appears normal.

The left adrenal gland is normal in size (0.48 cm at cranial pole and 0.56 cm at caudal pole), shape and overall architecture, echogenicity and echotexture. Visible surrounding vasculature appears normal.

Spleen

The spleen is subjectively normal in size with a normal smooth capsular contour. Parenchyma is appropriately finely textured and homogenous with normal echogenicity relative to surrounding tissue (hyperechoic to liver). No focal nodules or masses are observed. Splenic vasculature appears normal.

Liver

The liver is subjectively normal in size with normal smooth curvilinear peripheral contour. Parenchyma is appropriately hypoechoic to the spleen in echogenicity and appropriately mildly coarse and homogenous in echotexture. No focal lesions are observed. Visible vasculature and biliary tree appear normal without distension or congestion.

The gallbladder is non-distended in size. The wall is smooth without visible thickening. Luminal contents are primarily anechoic. There is no evidence of cystic or common bile duct dilation.

Gastrointestinal

Fundic mucosal hypertrophy with hyperechoic mucosa and some mucosal remodeling is noted. There is no loss of mural detail. Layering is normal. There is mild luminal fluid accumulation. No evidence of masses/nodules or foreign material present.



PATIENT

Tex Boyer

The visible small intestines are normal in wall thickness and layering. Small intestinal motility appears adequate (1-3 contractions per min). The lumen of the small intestine is empty with no evidence of obstruction, foreign material or infiltrative disease.

SPECIES

Canine

The visible colon is normal in wall thickness (< 0.2 cm) and layering. Contents are consistent with normal formed feces and gas.

Pancreas

BREED

Terrier x

The observed pancreas is prominent (enlarged) in size, hypoechoic to surrounding tissue and irregular in shape with a swollen undulating contour. This change is very subtle and most visibly suspected in the right cranial abdomen due to some mildly enhanced hyperechoic fat in the area.

SEX

Free Abdomen

Neutered Male

There is no visible free peritoneal effusion noted in these images.

AGE

There is no apparent pathologic lymphadenopathy noted in these images.

10 Years 4 Months

ULTRASONOGRAPHIC FINDINGS

WEIGHT

18 lbs

- Suspect mild potentially emerging acute pancreatitis.
- Concurrent gastritis – Consistent with irritation secondary to dietary indiscretion or intolerance, infection (bacterial, viral, other), parasitic or protozoal disease, toxin, other metabolic disease such as pancreatitis, other. Microulceration cannot be ruled out.

INTERPRETED BY

Beth Johnson, DVM
DACVIM

INTERPRETATION OF THE FINDINGS & FURTHER RECOMMENDATIONS

If not recently evaluated, a general metabolic health screen (CBC, chemistry panel with electrolytes and urinalysis) is recommended.

IMAGING PERFORMED BY

Kathleen Byrnes

A routine fecal/giardia exam is recommended if not recently evaluated.

A gastrointestinal malabsorption panel (including cobalamin, folate, TLI and PLI) to Texas A&M GI Laboratory is recommended for further evaluation of GI and pancreatic function.

HOSPITAL NAME

Animal Hospital of
Lake Brandt

A fecal enteropathogen PCR panel to Texas A&M GI Laboratory could be considered for further evaluation of possible infectious disease. Contact lab for recommendations on how long to discontinue antibiotics (if indicated) prior to obtaining a stool sample for submission.

REFERRING VET

Dr. Smith

A baseline cortisol is recommended. If baseline cortisol is less than 2, a full ACTH stimulation test is recommended to rule out hypoadrenocorticism.

INVOICE

74264

In the meantime, medical management of pancreatitis with anti-emetics, gastroprotectants, appetite stimulants or nutritional support as needed, pain management, broad spectrum antibiotics, and fluid therapy is recommended. Monitoring of the pancreas with power doppler is recommended to identify possible necrosis as well as other potential sequelae such as abscesses, etc.

DATE

4/7/26



PATIENT

Tex Boyer

SPECIES

Canine

BREED

Terrier x

SEX

Neutered Male

AGE

10 Years 4 Months

WEIGHT

18 lbs

INTERPRETED BY

Beth Johnson, DVM
 DACVIM

IMAGING PERFORMED BY

Kathleen Byrnes

HOSPITAL NAME

Animal Hospital of
 Lake Brandt

REFERRING VET

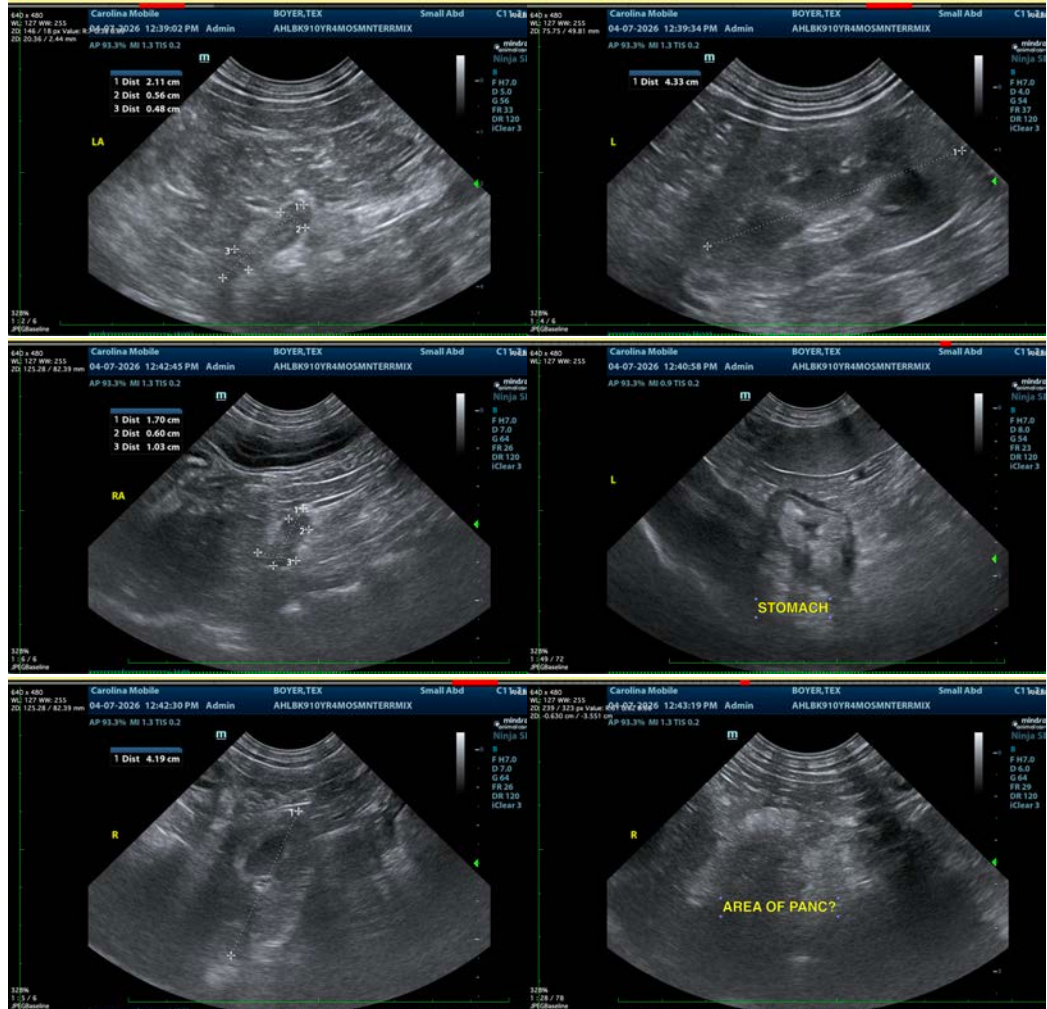
Dr. Smith

INVOICE

74264

DATE

4/7/26



The information and recommendations provided are based on the images presented by the referring veterinarian/sonographer. No evaluation can be communicated regarding pathology that was not visible in the image/video clips provided.

Thank you for this referral. If the clinical or image interpretation does not parallel your findings or if I can be of any further assistance please contact me.

Beth Johnson, DVM, DACVIM
 info@sonopath.com