



## PATIENT

Sasha Elliott

## SPECIES

Canine

## BREED

Mixed

## SEX

Spayed Female

## AGE

9 Years

## WEIGHT

26.3 kg

## INTERPRETED BY

Beth Johnson, DVM  
DACVIM

## IMAGING PERFORMED BY

Dr. Sarah Barthelemy

## HOSPITAL NAME

Bridgeland Vet Clinic

## REFERRING VET

Dr. Elock

## INVOICE

74282

## DATE

4/7/26

## PRESENTING CLINICAL SIGNS

Hematochezia and inappetance which has improved.

Abnormal PE/Chem/CBC/UA Results: Hemoconcentration, low platelets however clumping present to some degree

## ULTRASONOGRAPHIC EXAMINATION OF THE ABDOMEN

### *Urinary System*

The urinary bladder is adequately distended with anechoic contents. No masses, inflammatory changes, echogenic sediment or cystoliths are observed. The urinary bladder, trigone and visible pelvic urethra are normal in thickness with a smooth mucosal surface.

The right kidney is normal is size (6.43 cm), shape and echogenicity. It has smooth peripheral margination. There is a normal 1:3 cortex to medulla ratio with appropriate corticomedullary distinction. There is no evidence of pyelectasia, mineral or infarcts observed.

The left kidney is normal is size (6.59 cm), shape and echogenicity. It has smooth peripheral margination. There is a normal 1:3 cortex to medulla ratio with appropriate corticomedullary distinction. There is no evidence of pyelectasia, mineral or infarcts observed.

### *Adrenal Glands*

The right adrenal gland is normal in size (0.38 cm at cranial pole and 0.50 cm at caudal pole), shape and overall architecture, echogenicity and echotexture. Visible surrounding vasculature appears normal.

The left adrenal gland is normal in size (0.37 cm at cranial pole and 0.44 cm at caudal pole), shape and overall architecture, echogenicity and echotexture. Visible surrounding vasculature appears normal.

### *Spleen*

The spleen is subjectively normal in size with a normal smooth capsular contour. Parenchyma is appropriately finely textured and homogenous with normal echogenicity relative to surrounding tissue (hyperechoic to liver), except for an approximately 0.70 cm in diameter non-capsule disrupting hypoechoic nodule in the mid spleen. Splenic vasculature appears normal.

### *Liver*

The liver is subjectively normal in size with normal smooth curvilinear peripheral contour. Parenchyma is appropriately hypoechoic to the spleen in echogenicity and appropriately mildly coarse and homogenous in echotexture. No focal lesions are observed. Visible vasculature and biliary tree appear normal without distension or congestion.

The gallbladder is non-distended in size. The wall is smooth without visible thickening. Luminal contents are primarily anechoic. There is no evidence of cystic or common bile duct dilation.

### *Gastrointestinal*

The visible stomach wall is normal in thickness and layering. The lumen of the stomach is mildly distended with a small to moderate amount of echogenic non-shadowing luminal contents and gas consistent with normal ingesta. There is no evidence of obstruction, foreign material or infiltrative disease. Pyloric outflow tract appears patent.



## PATIENT

Sasha Elliott

## SPECIES

Canine

## BREED

Mixed

## SEX

Spayed Female

## AGE

9 Years

## WEIGHT

26.3 kg

## INTERPRETED BY

Beth Johnson, DVM  
DACVIM

## IMAGING PERFORMED BY

Dr. Sarah Barthelemy

## HOSPITAL NAME

Bridgeland Vet Clinic

## REFERRING VET

Dr. Elock

## INVOICE

74282

## DATE

4/7/26

The visible small intestine demonstrates areas of moderately thick muscularis layer relative to mucosa (disruption of the normal 1:3 muscularis:mucosa ratio). Small intestinal submucosa is slightly irregular, thick and hyperechoic, without evident loss of layering appreciated. The lumen of the small intestine is empty with no evidence of obstruction or foreign material.

The colon wall is mildly thick, measuring 0.26 cm thick with normal intact layering and is empty.

### ***Pancreas***

The pancreas that is observed appears appropriately isoechoic to surrounding omental fat. Visible capsule is smooth and normal in contour. Visible pancreatic parenchyma is homogenous and unremarkable. There is no visible pancreatic duct dilation. There is no evidence of active peripancreatic inflammation.

### ***Free Abdomen***

There is no visible free peritoneal effusion noted in these images.

Medial iliac lymph nodes are prominent in size with swollen capsular contour. Normal elongated shape (length to width ratio) is maintained. There is no loss of parenchymal detail.

## **ULTRASONOGRAPHIC FINDINGS**

- Moderate inflammatory bowel disease (IBD) pattern – Thick muscularis has been reported with infiltrative bowel disease including both benign inflammatory disease as well as infiltrative neoplasia such as lymphoma. No loss of layering or distinct characteristics of malignancy are present. Therefore, differentials cannot be further ranked without tissue sampling.
- Similarly, the same differentials exist for the mildly thick colon, which largely trends in appearance toward benign.
- Mildly to moderately reactive medial iliac lymph nodes – infiltrative neoplastic disease cannot be ruled out but is considered less likely.
- Hypo to anechoic splenic nodule – likely represents a benign lesion such as a cyst, hematoma, nodular hyperplasia, extramedullary hematopoiesis, etc., however while considered less likely, infiltrative neoplasia can mimic benign lesions, and cannot be ruled out.

## **INTERPRETATION OF THE FINDINGS & FURTHER RECOMMENDATIONS**

A routine fecal/giardia exam is recommended if not recently evaluated.

A gastrointestinal malabsorption panel (including cobalamin, folate, TLI and PLI) to Texas A&M GI Laboratory is recommended for further evaluation of GI and pancreatic function.

A fecal enteropathogen PCR panel to Texas A&M GI Laboratory could be considered for further evaluation of possible infectious disease. Contact lab for recommendations on how long to discontinue antibiotics (if indicated) prior to obtaining a stool sample for submission.

A baseline cortisol is recommended. If baseline cortisol is less than 2, a full ACTH stimulation test is recommended to rule out hypoadrenocorticism.



**PATIENT**

Sasha Elliott

**SPECIES**

Canine

**BREED**

Mixed

**SEX**

Spayed Female

**AGE**

9 Years

**WEIGHT**

26.3 kg

**INTERPRETED BY**

Beth Johnson, DVM  
DACVIM

**IMAGING PERFORMED BY**

Dr. Sarah Barthelemy

**HOSPITAL NAME**

Bridgeland Vet Clinic

**REFERRING VET**

Dr. Elock

**INVOICE**

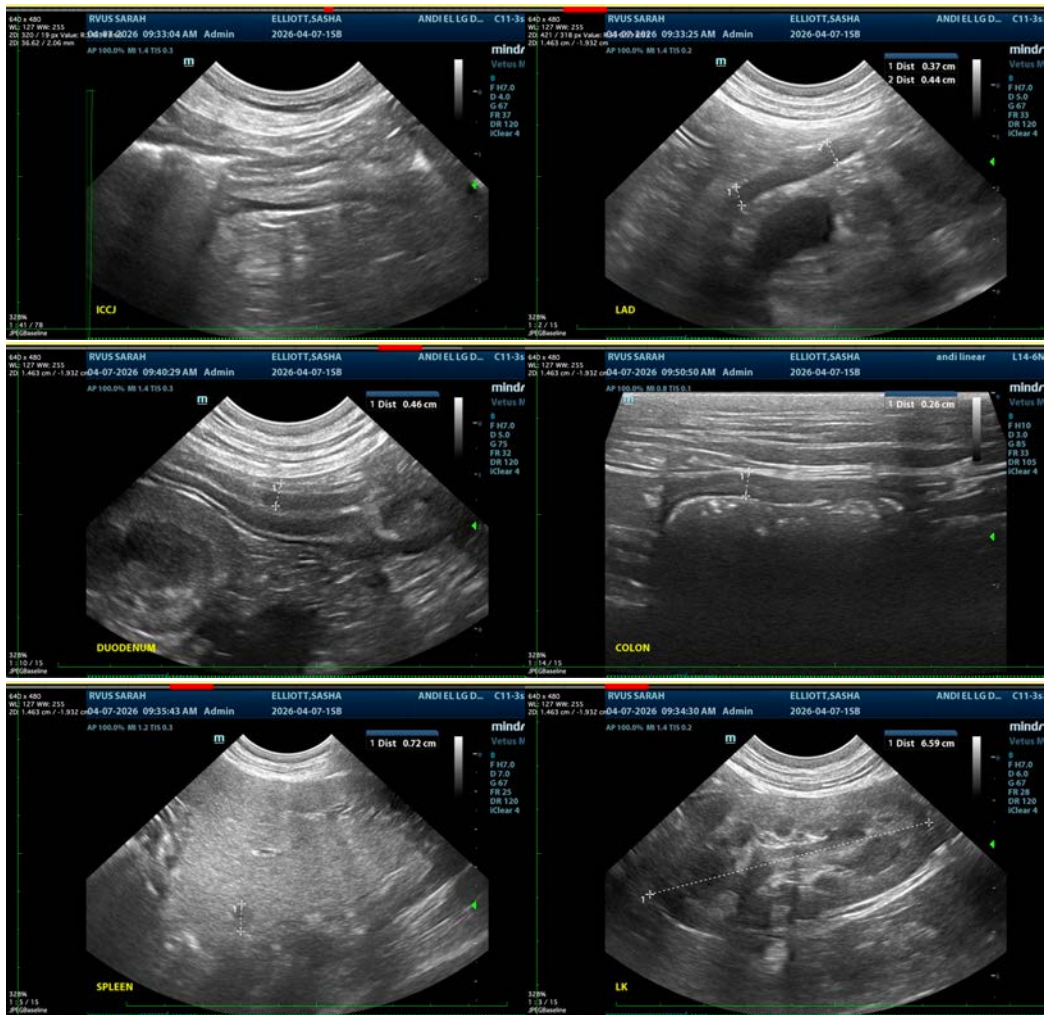
74282

**DATE**

4/7/26

In the meantime, supportive/symptomatic medical management of clinical signs is recommended, including a probiotic (such as visbiome or proviable), empirical deworming with a 5-day course of Panacur and, if tolerated, a transition in diet, based on trial-and-error response, beginning possibly with a gastrointestinal biome diet vs a hydrolyzed protein diet vs other. Some patients respond to one brand/version of a hydrolyzed protein diet better than another brand, so several brand attempts may be required.

It sounds like the patient is clinically improving, but if clinical signs relapse and a diagnosis is not made, ultimately biopsies of the GI tract, being sure to include ileum, if possible, may be necessary for a definitive diagnosis and therefore to further guide medical management.





**PATIENT**

Sasha Elliott

**SPECIES**

Canine

**BREED**

Mixed

**SEX**

Spayed Female

**AGE**

9 Years

**WEIGHT**

26.3 kg

**INTERPRETED BY**

Beth Johnson, DVM  
DACVIM

**IMAGING PERFORMED BY**

Dr. Sarah Barthelemy

**HOSPITAL NAME**

Bridgeland Vet Clinic

**REFERRING VET**

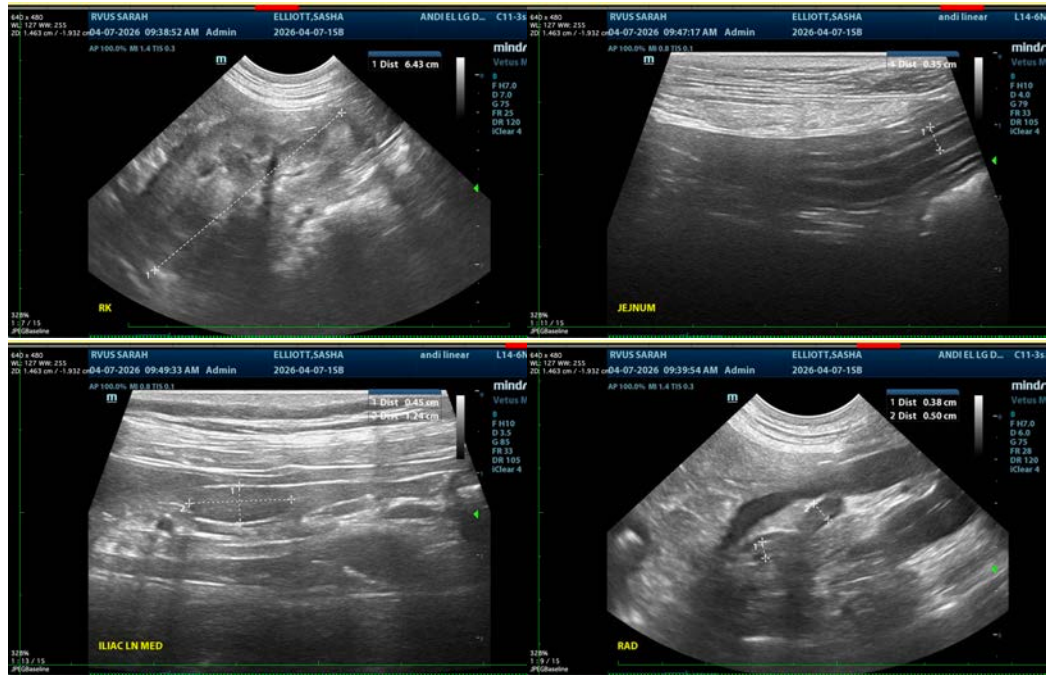
Dr. Elock

**INVOICE**

74282

**DATE**

4/7/26



The information and recommendations provided are based on the images presented by the referring veterinarian/sonographer. No evaluation can be communicated regarding pathology that was not visible in the image/video clips provided.

Thank you for this referral. If the clinical or image interpretation does not parallel your findings or if I can be of any further assistance please contact me.

**Beth Johnson, DVM, DACVIM**  
info@sonopath.com