



PATIENT

Ruthie Fredette

SPECIES

Canine

BREED

Shepherd Mix

SEX

Spayed Female

AGE

9 Months

WEIGHT

40.60 Pounds

INTERPRETED BY

Beth Johnson, DVM
DACVIM

IMAGING PERFORMED BY

Grace Jayne, CVT

HOSPITAL NAME

Ark Animal Homecare

REFERRING VET

Dr. Erika De Beckers

INVOICE

36493

DATE

4/7/26

PRESENTING CLINICAL SIGNS

History: Decreased appetite since Saturday, vomited once the same day (large volume of bile). Diarrhea started Saturday night. Vomiting has resolved, but diarrhea has continued. No history of foreign body ingestion, but she does shred toys sometimes. Reluctant to drink water, and persistent hyporexia.

Abnormal PE/Chem/CBC/UA Results: Pending labs, normal exam.

ULTRASONOGRAPHIC EXAMINATION OF THE ABDOMEN

Urinary System

Urinary bladder is adequately distended with anechoic contents. No masses, inflammatory changes, echogenic sediment or cystoliths are observed. The urinary bladder, trigone and visible pelvic urethra are normal in thickness with a smooth mucosal surface.

Left kidney is normal in size (5.5 cm), shape and echogenicity. It has smooth peripheral margination. There is a normal 1:3 cortex to medulla ratio with appropriate corticomedullary distinction. There is no evidence of pyelectasia, mineral or infarcts observed.

Right kidney is normal in size (6.2 cm), shape and echogenicity. It has smooth peripheral margination. There is a normal 1:3 cortex to medulla ratio with appropriate corticomedullary distinction. There is no evidence of pyelectasia, mineral or infarcts observed.

Adrenal Glands

The adrenal glands are unable to be visualized in these images.

Spleen

Spleen is subjectively normal in size with a normal smooth capsular contour. Parenchyma is appropriately finely textured and homogenous with normal echogenicity relative to surrounding tissue (hyperechoic to liver). No focal nodules or masses are observed. Splenic vasculature appears normal.

Liver

Liver is subjectively normal in size with normal smooth curvilinear peripheral contour. Parenchyma is appropriately hypoechoic to the spleen in echogenicity and appropriately mildly coarse and homogenous in echotexture. No focal lesions are observed. Visible vasculature and biliary tree appear normal without distension or congestion.

Gallbladder is non-distended in size. The wall is smooth without visible thickening. Luminal contents are primarily anechoic. There is no evidence of cystic or common bile duct dilation.

Gastrointestinal

The visible stomach wall is normal in thickness and layering. The stomach is moderately distended with echogenic non-shadowing luminal contents and gas consistent with normal ingesta. There is no evidence of obstruction, foreign material or infiltrative disease. If patient was appropriately fasted, delayed gastric emptying could be considered. Non-shadowing foreign material is considered less likely but cannot be definitively ruled out. If clinical signs are consistent (vomiting, etc.), recommendations include supportive medical care, 24 hours fasting and re-image.



PATIENT

Ruthie Fredette

SPECIES

Canine

BREED

Shepherd Mix

SEX

Spayed Female

AGE

9 Months

WEIGHT

40.60 Pounds

INTERPRETED BY

Beth Johnson, DVM
DACVIM

IMAGING PERFORMED BY

Grace Jayne, CVT

HOSPITAL NAME

Ark Animal Homecare

REFERRING VET

Dr. Erika De Beckers

INVOICE

36493

DATE

4/7/26

The visible small intestines are normal in wall thickness and layering. Small intestinal motility appears adequate (1-3 contractions per min). The lumen of the small intestine is mildly distended with echogenic non-shadowing luminal contents and gas consistent with normal ingesta/chyme. There is no evidence of obstruction, foreign material or infiltrative disease.

The visible colon is normal in wall thickness (< 0.2 cm) and layering. Contents are consistent with normal formed feces and gas.

Pancreas

The pancreas that is observed appears appropriately isoechoic to surrounding omental fat. Visible capsule is smooth and normal in contour. Visible pancreatic parenchyma is homogenous and unremarkable. There is no visible pancreatic duct dilation. There is no evidence of active peripancreatic inflammation.

Free Abdomen

There is no visible free peritoneal effusion noted in these images.

The mesenteric lymph nodes are prominent in size with swollen capsular contour. Normal elongated shape (length to width ratio) is maintained. There is no loss of parenchymal detail.

ULTRASONOGRAPHIC FINDINGS

- This is a largely unremarkable/normal structural abdomen, although it does appear postprandial, and while thought less likely, foreign material versus ingesta in the stomach can't be definitively ruled out. Reassessment following an additional 12 - 24 hours of fasting could be considered.
- Mildly reactive mesenteric lymphadenopathy – infiltrative neoplastic disease cannot be ruled out but is considered less likely. This finding may be in part normal patient variant/juvenile lymphadenopathy given patient's young age.

INTERPRETATION OF THE FINDINGS & FURTHER RECOMMENDATIONS

Given the reported ongoing diarrhea, as is reportedly already pending, a full general metabolic health screen is recommended.

Additionally, routine fecal/Giardia exam is recommended if not recently evaluated.

A gastrointestinal malabsorption panel (including cobalamin, folate, TLI and PLI) to Texas A&M GI Laboratory is recommended for further evaluation of GI and pancreatic function.

A fecal enteropathogen PCR panel to Texas A&M GI Laboratory could be considered for further evaluation of possible infectious disease. Contact lab for recommendations on how long to discontinue antibiotics (if indicated) prior to obtaining a stool sample for submission.

In the meantime, supportive/symptomatic medical management of clinical signs is recommended, including a probiotic (such as visbiome or proviable), empirical deworming with a 5-day course of Panacur and, if tolerated, a transition in diet, based on trial-and-error response, beginning possibly with a gastrointestinal biome diet vs a hydrolyzed protein diet vs other. Some patients respond to one brand/version of a hydrolyzed protein diet better than another brand, so several brand attempts may be required.



PATIENT

Ruthie Fredette

SPECIES

Canine

BREED

Shepherd Mix

SEX

Spayed Female

AGE

9 Months

WEIGHT

40.60 Pounds

INTERPRETED BY

Beth Johnson, DVM
DACVIM

IMAGING PERFORMED BY

Grace Jayne, CVT

HOSPITAL NAME

Ark Animal Homecare

REFERRING VET

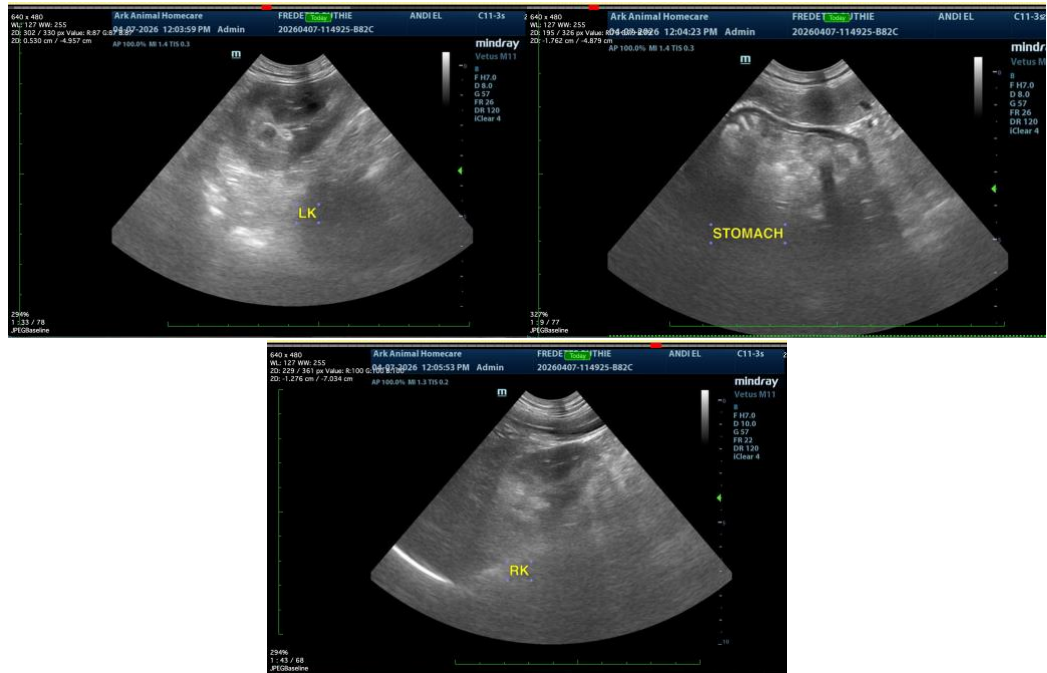
Dr. Erika De Beckers

INVOICE

36493

DATE

4/7/26



The information and recommendations provided are based on the images presented by the referring veterinarian/sonographer. No evaluation can be communicated regarding pathology that was not visible in the image/video clips provided.

Thank you for this referral. If the clinical or image interpretation does not parallel your findings or if I can be of any further assistance please contact me.

Beth Johnson, DVM DACVIM

info@sonopath.com