


**DATE PRESENTING CLINICAL SIGNS**

4/7/26

**Patient History:** Rambo was presented in early March for increased panting. Additionally, there has been significantly increased thirst and urination starting November 2025. He had been having accidents in the house and his water bowl would be empty each morning despite filling it the prior evening. Rambo also developed a comedogenic and mineral deposit lesion on his dorsal cervical region and between the shoulder blades. Normal vitals on exam. Calcinosis cutis suspected for the skin lesions. Pot Belly and multifocal spots of truncal alopecia. Underbite. Since starting on Vetoryl, thirst has significantly

**PATIENT**

 Rambo Everett  
 Buttion

**SPECIES**

Canine

**Current Medications:** Cefpoderm 150 mg PO q 24 hours 3/5/26 to 3/19/26, Veteroyl 20 mg PO q 24 hours in the AM starting 3/7/26, DermaBensS topically to area of calcinosis cutis and secondary infection EOD starting 4/4/26

**BREED**

French Bulldog

**Labwork Results:** Attached. Reported as 11/28/25 - Lepto titers negative. 12/4/25 - Post prandial bile acids 31.2umol/L. 3/6/26 - Low Dose Dex. Suppression test indicative of HAC. 3/19/26 - ACTH Stim. indicative of fair HAC control. electrolytes normal. 4/3/26 - Electrolytes normal. ACTH Stim. test pending

**Date of Previous IntraPet Ultrasound:** 11/25/25

**SEX**

Neutered Male

**Sedation:** Not required to complete full diagnostic ultrasound.

**Stat Report:** Not requested.

**Imaging Performed by:** Andi Parkinson RDMS

**ULTRASONOGRAPHIC EXAMINATION OF THE ABDOMEN**
**AGE**

10/21/18

**Urinary System**
**WEIGHT**

34.6 lbs

Urinary bladder is adequately distended. It has a normal uniform wall thickness. Contents include primarily anechoic fluid with a moderate amount of echogenic non-shadowing debris, most consistent with exfoliated cells, mucous and/or small blood clots. Both sterile inflammation as well as urinary tract infection can present with echogenic debris. No masses or cystoliths are observed. The trigone and visible pelvic urethra are normal in thickness with a smooth mucosal surface

**INTERPRETED BY**

 Beth Johnson, DVM  
 DACVIM

Prostate is normal in size, echotexture and echogenicity for a neutered male.

**HOSPITAL NAME**

 Bel Air Veterinary  
 Hospital

The right kidney is normal is size (5.89 cm), shape and echogenicity. It has smooth peripheral margination. There is a normal 1:3 cortex to medulla ratio with appropriate corticomedullary distinction. There is no evidence of pyelectasia, mineral or infarcts observed.

**REFERRING VET**

Dr. Young

The left kidney is normal is size (5.98 cm), shape and echogenicity. It has smooth peripheral margination. There is a normal 1:3 cortex to medulla ratio with appropriate corticomedullary distinction. There is no evidence of pyelectasia, mineral or infarcts observed.

**INVOICE**

74278

**Adrenal Glands**

Adrenal glands are plump/swollen in size. Normal shape and contour are maintained without evidence of capsular invasion. Corticomedullary structure is unremarkable. A hyperechoic nodule is noted in the cranial pole of the right adrenal gland. Nodule does not disrupt normal shape and/or architecture. The nodule measures 0.50 cm x 0.70 cm. Visible surrounding vasculature appears normal. Left measures 0.91 cm at the cranial pole and 0.98 cm at the caudal pole. Right measures 1.0 cm at the cranial pole and 0.93 cm at the caudal pole.

### ***Spleen***

The spleen is subjectively normal in size with a normal smooth capsular contour. Parenchyma is appropriately finely textured and homogenous with normal echogenicity relative to surrounding tissue (hyperechoic to liver). No focal nodules or masses are observed. Splenic vasculature appears normal.

### ***Liver***

The liver is subjectively normal in size with normal smooth curvilinear peripheral contour. Parenchyma is appropriately hypoechoic to the spleen in echogenicity and appropriately mildly coarse and homogenous in echotexture. No focal lesions are observed. Visible vasculature and biliary tree appear normal without distension or congestion.

Gallbladder is mildly overdistended with a moderate amount of non-dependent, mildly aggregated/inspissated sludge. Hypo to anechoic cystic areas are noted between the gallbladder sludge and luminal wall. The wall is otherwise smooth without visible thickening. There is no evidence of cystic or CBD dilation. There is no evidence of effusion.

### ***Gastrointestinal***

The visible stomach wall is normal in thickness and layering. The stomach is mildly distended and contains an echogenic interface with distal shadowing material consistent with possible non-obstructive foreign material. Having said that, normal ingesta and gas can't be ruled out. This finding should be interpreted in combination with when patient last ate, clinical signs, etc.

The visible small intestines are normal in wall thickness and layering. Small intestinal motility appears adequate (1-3 contractions per min). The lumen is mildly distended with echogenic non-shadowing luminal contents and gas consistent with normal ingesta/chyme. There is no evidence of obstruction, foreign material or infiltrative disease.

The visible colon is normal in wall thickness (< 0.2 cm) and layering. Contents are consistent with normal formed feces and gas.

### ***Pancreas***

The area of the pancreas contains irregular hyperechoic pancreatic remodeling.

### ***Free Abdomen***

There is no visible free peritoneal effusion noted in these images.

There is no apparent pathologic lymphadenopathy noted in these images.

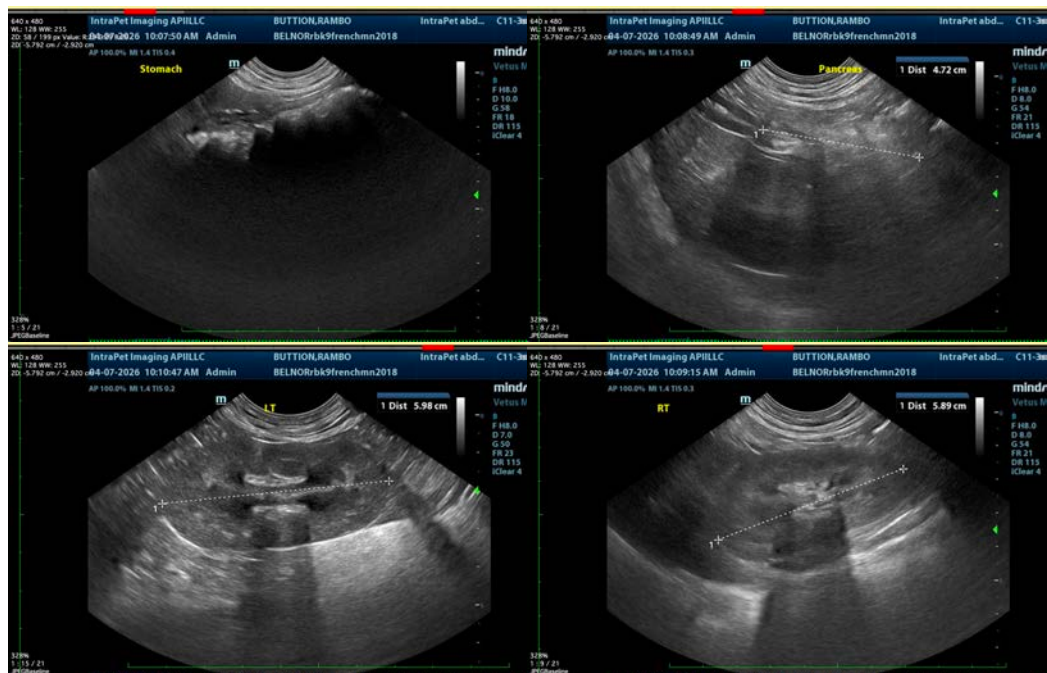
## **ULTRASONOGRAPHIC FINDINGS**

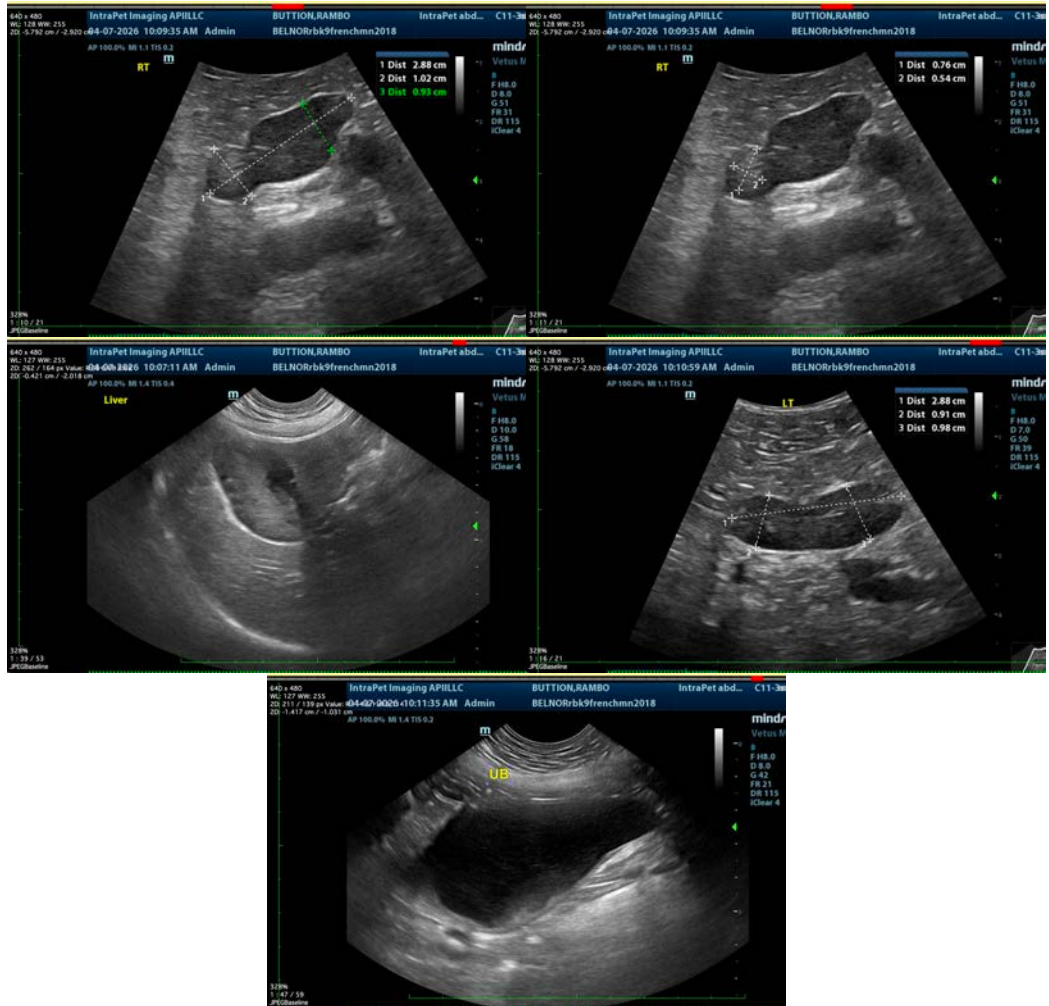
- The bilateral adrenomegaly is consistent with patient's reported history of medically managed hyperadrenocorticism. The appearance of the nodule in the right adrenal gland is static in size and appearance from the previous exam.

- Emerging mucocele – Cholecystic debris is of unknown clinical significance. It can be seen with biliary stasis from fasting or illness. Cholecystic debris is not necessarily related to hepatobiliary disease. The non-dependent nature of this sludge combined with the cystic areas are suggestive, however, of possible emerging cystic mucosal hyperplasia or early gallbladder mucocele.
- Hyperechoic pancreas – This finding is suggestive of pancreatic fibrosis, possibly secondary to chronic pancreatitis. A TLI is recommended to rule out exocrine pancreatic insufficiency (EPI), especially if clinical signs (weight loss, diarrhea, etc.) are present.
- Gastric foreign material can't be ruled out, but again this finding should be interpreted in combination with when patient last ate. Recheck imaging following an additional 12-24 hours of fasting could be considered.
- Moderate amount of echogenic urinary bladder debris.

### INTERPRETATION OF THE FINDINGS & FURTHER RECOMMENDATIONS

This is a largely static/unchanged ultrasound except for mild progression and size of the adrenal glands, which is relatively common when beginning medical management i.e., Vetoryl. If patient is clinically well controlled, additional intervention may not be indicated. However, if patient's clinical signs are not as controlled as desired, most patients do respond better to twice daily dosing with Vetoryl while maintaining the same or sometimes even reduced total daily dose. So, for example, instead of 20mg once a day, 10mg or even less twice a day in theory may offer more adequate control.





The information and recommendations provided are based on the images presented by the referring veterinarian/sonographer. No evaluation can be communicated regarding pathology that was not visible in the image/video clips provided.

Thank you for this referral. If the clinical or image interpretation does not parallel your findings or if I can be of any further assistance please contact me.

**Beth Johnson, DVM, DACVIM**  
 info@sonopath.com