



## PATIENT

Bella Xenophontos

## SPECIES

Canine

## BREED

Maltese

## SEX

FS

## AGE

11 years

## WEIGHT

11.3 lbs

## INTERPRETED BY

Beth Johnson, DVM  
DACVIM

## IMAGING PERFORMED BY

Jessy Butcher

## HOSPITAL NAME

Healing Paws

## REFERRING VET

Dr. Preston

## INVOICE

11637

## DATE

4/7/2026

## PRESENTING CLINICAL SIGNS

Seen on emergency 3/31 for diarrhea and abdominal distention. Repeat EM exam on 4/1 for the same problems. History of Cushing's, currently not treated due to stomach upset with any treatment tried. More Pu/Pd recently. Also, some lethargy, sneezing, and nasal discharge. Decreased appetite. Recent history of skin allergies with ear infection and nail bed infection.

Abnormal PE/Chem/CBC/UA Results: EM bloodwork showed hemoconcentration, likely due to dehydration, T. Protein 9.2 (5.2-8.2), ALT 170 (10-125), ALP 1838 (23-212). UA showed some RBCs in the urine and poor concentration (reported as >1,000).

## ULTRASONOGRAPHIC EXAMINATION OF THE ABDOMEN

### Urinary System

The urinary bladder is adequately distended with anechoic contents. No masses, inflammatory changes, echogenic sediment or cystoliths are observed. The urinary bladder, trigone and visible pelvic urethra are normal in thickness with a smooth mucosal surface.

Kidneys are overall normal in size and shape with smooth peripheral margination. A normal 1:3 cortex to medulla ratio is maintained. The medulla and cortices are uniform in texture with some mild increased cortical echogenicity and mild loss of corticomedullary distinction, expected in this age patient. Multiple small cortical cysts are noted bilaterally. There is no evidence of pyelectasia, mineral or infarcts observed. Left kidney measures 4.5 cm and the right kidney measures 4.4 cm.

### Adrenal Glands

Adrenal glands are subjectively mildly plump in size. Normal shape and contour are maintained without evidence of capsular invasion. Corticomedullary structure is unremarkable. Visible surrounding vasculature appears normal. Left adrenal measures 0.52 cm at the cranial pole and 0.65 cm at the caudal pole. Right adrenal measures 0.79 cm at the caudal pole, and the cranial pole is difficult to fully visualize/isolate for measurement.

### Spleen

Spleen is subjectively normal in size with a normal smooth capsular contour. Parenchyma is appropriately finely textured and homogenous with normal echogenicity relative to surrounding tissue (hyperechoic to liver). No focal nodules or masses are observed. Multifocal mineral foci are noted. Splenic vasculature appears normal.

### Liver

Liver is subjectively enlarged with mildly irregular margins. Parenchyma is mildly heterogenous characterized by multiple poorly defined hypoechoic nodules within otherwise hyperechoic liver parenchyma. Visible vasculature and biliary tree appear normal without distension or congestion.

Gallbladder is moderately distended with anechoic bile as well as suspended and gravity dependent echogenic debris. The wall is smooth without visible thickening. There is no evidence of cystic or CBD dilation. There is no evidence of effusion or inflammation.

### Gastrointestinal



## PATIENT

Bella Xenophontos

## SPECIES

Canine

## BREED

Maltese

## SEX

FS

## AGE

11 years

## WEIGHT

11.3 lbs

## INTERPRETED BY

Beth Johnson, DVM  
DACVIM

## IMAGING PERFORMED BY

Jessy Butcher

## HOSPITAL NAME

Healing Paws

## REFERRING VET

Dr. Preston

## INVOICE

11637

## DATE

4/7/2026

The visible stomach wall is normal in thickness and layering. The lumen of the stomach is mildly distended with echogenic non-shadowing luminal contents and gas consistent with normal ingesta. There is no evidence of obstruction or foreign material noted. Pyloric outflow tract appears patent.

The visible small intestines are normal in wall thickness and layering. Hyperechoic mucosal fogging or speckling is noted. Small intestinal motility appears adequate (1-3 contractions per min). The lumen of the small intestine is mildly distended with echogenic non-shadowing luminal contents and gas consistent with normal ingesta. There is no evidence of obstruction or foreign material noted.

The visible colon is normal in wall thickness (< 0.2 cm) and layering. Contents are consistent with normal formed feces and gas.

### *Pancreas*

The pancreas that is observed appears appropriately isoechoic to surrounding omental fat. Visible capsule is smooth and normal in contour. Visible pancreatic parenchyma is homogenous and unremarkable. There is no visible pancreatic duct dilation. There is no evidence of active peripancreatic inflammation.

### *Free Abdomen*

There is no visible free peritoneal effusion noted in these images.

There is no apparent pathologic lymphadenopathy noted in these images.

## PRIMARY FINDINGS

- Mild to moderate mucosal speckling – Mucosal speckling is often present with inflammatory bowel disease (IBD). It is not specific for type or severity of disease. Mild speckling change can occur as a normal patient variant in the post-prandial state.
- Mildly heterogenous liver – These changes are most consistent with benign processes such as nodular hyperplasia, steroid (vacuolar) hepatopathy, extramedullary hematopoiesis or possibly chronic inflammatory disease and less commonly infiltrative round cell or metastatic neoplasia.
- Mild gallbladder debris - Cholecystic debris is of unknown clinical significance. It can be seen with biliary stasis from fasting or illness. Cholecystic debris is not necessarily related to hepatobiliary disease. Echogenic bile is most commonly an incidental finding in dogs and should be interpreted in combination with clinical signs such as nausea, inappetence, cranial abdominal discomfort and/or laboratory changes such as increased ALP and/or increased Tbili.
- Spleen mineralization – This is a benign change but can be associated with endocrinopathies, especially hyperadrenocorticism.
- Bilateral adrenomegaly – In a patient diagnosed with hyperadrenocorticism, this finding is most consistent with adrenal hyperplasia secondary to pituitary dependent hyperadrenocorticism. This finding can also be seen with stress and/or normal patient variant. Interpret in combination with clinical signs of hyperadrenocorticism and/or other adrenal disease.

## SECONDARY FINDINGS



**PATIENT**

Bella Xenophontos

**SPECIES**

Canine

**BREED**

Maltese

**SEX**

FS

**AGE**

11 years

**WEIGHT**

11.3 lbs

**INTERPRETED BY**

Beth Johnson, DVM  
DACVIM

**IMAGING PERFORMED BY**

Jessy Butcher

**HOSPITAL NAME**

Healing Paws

**REFERRING VET**

Dr. Preston

**INVOICE**

11637

**DATE**

4/7/2026

- Moderate age-related kidney changes.

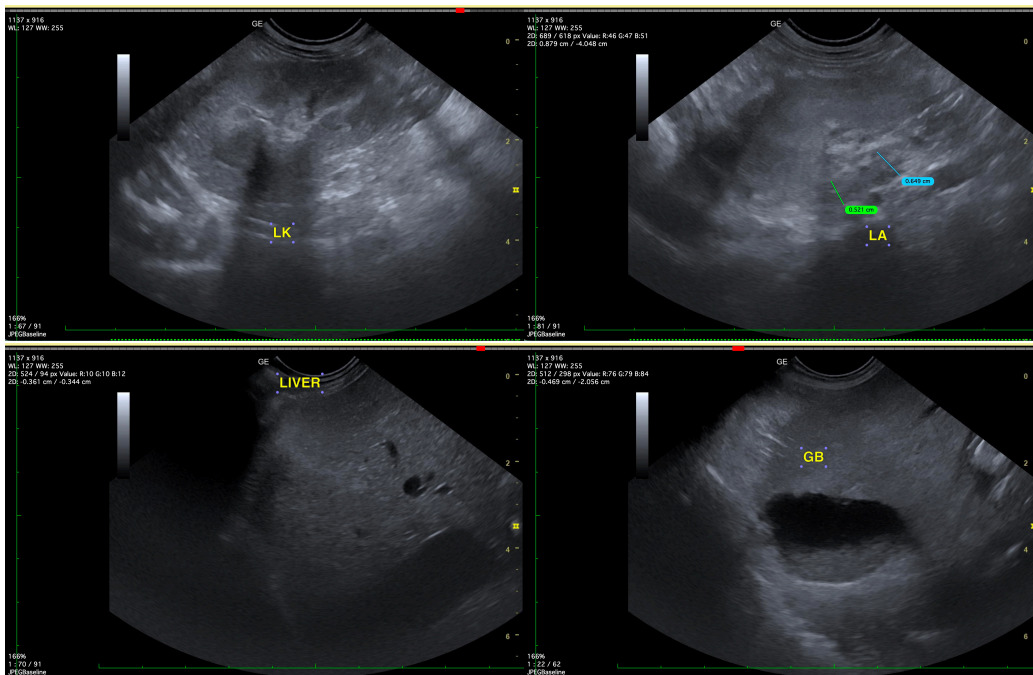
**INTERPRETATION OF THE FINDINGS & FURTHER RECOMMENDATIONS**

The appearance of the adrenal glands is consistent with patient's reported previous diagnosis of hyperadrenocorticism. Some of the subtle hepatobiliary and spleen changes could also be related to that underlying endocrinopathy. Given patients reported gastrointestinal signs, however, which are likely unrelated to hyperadrenocorticism, further gastrointestinal workup recommendations include:

- A routine fecal/giardia exam is recommended if not recently evaluated.
- A gastrointestinal malabsorption panel (including cobalamin, folate, TLI and PLI) to Texas A&M GI Laboratory is recommended for further evaluation of GI and pancreatic function.
- A fecal enteropathogen PCR panel to Texas A&M GI Laboratory could be considered for further evaluation of possible infectious disease. Contact lab for recommendations on how long to discontinue antibiotics (if indicated) prior to obtaining a stool sample for submission.

Additionally, if not recently evaluated a urine culture could be considered.

In the meantime, supportive/symptomatic medical management of clinical signs is recommended, including a probiotic (such as visbiome or proviable), empirical deworming with a 5-day course of Panacur and, if tolerated, a transition in diet, based on trial-and-error response, beginning possibly with a gastrointestinal biome diet vs a hydrolyzed protein diet vs other. Some patients respond to one brand/version of a hydrolyzed protein diet better than another brand, so several brand attempts may be required.





## PATIENT

Bella Xenophontos

## SPECIES

Canine

## BREED

Maltese

## SEX

FS

## AGE

11 years

## WEIGHT

11.3 lbs

## INTERPRETED BY

Beth Johnson, DVM  
DACVIM

## IMAGING PERFORMED BY

Jessy Butcher

## HOSPITAL NAME

Healing Paws

## REFERRING VET

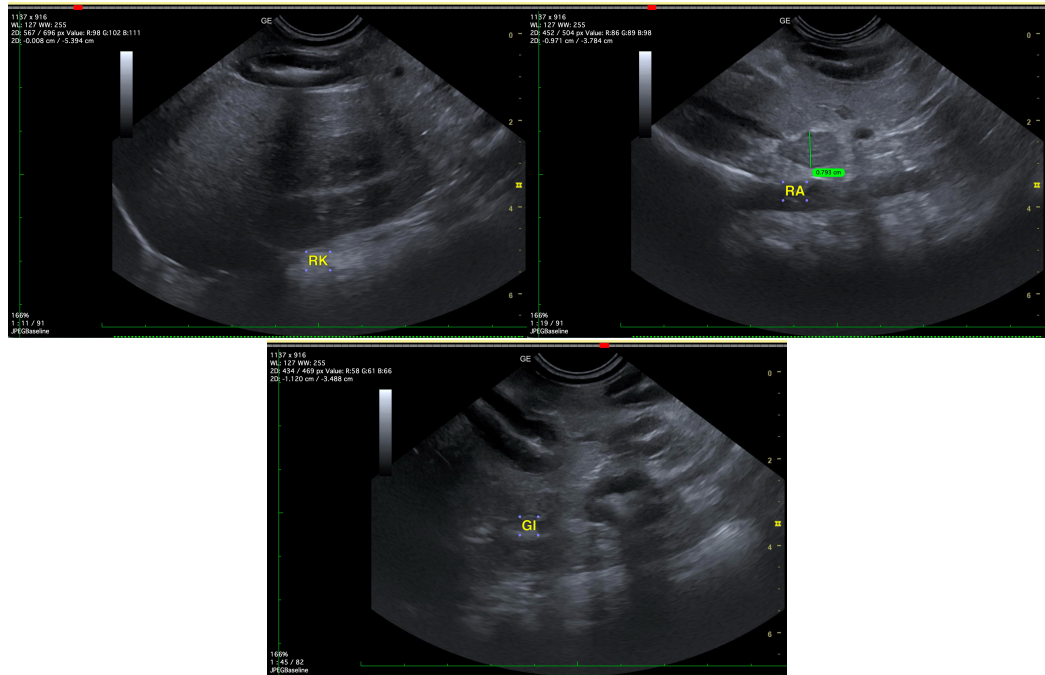
Dr. Preston

## INVOICE

11637

## DATE

4/7/2026



The information and recommendations provided are based on the images presented by the referring veterinarian/sonographer. No evaluation can be communicated regarding pathology that was not visible in the image/video clips provided.

Thank you for this referral. If the clinical or image interpretation does not parallel your findings or if I can be of any further assistance please contact me.

Beth Johnson, DVM, DACVIM  
info@sonopath.com