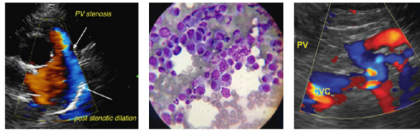


**IMAGING PERFORMED BY**

SVS Mobile Imaging 262-366-5970  
fredgromalak@gmail.com



EDUCATIONAL TELECONSULTATION SERVICES™  
1-800-838-4268 info@sonopath.com SonoPath.com

**PATIENT**

Thomas Snow

**SPECIES**

Feline

**BREED**

DLH

**SEX**

Neutered Male

**AGE**

3 Years

**WEIGHT**

12 Pounds

**INTERPRETED BY**

Beth Johnson, DVM  
DACVIM

**IMAGING PERFORMED BY**

Kim Liedberg

**HOSPITAL NAME**

SVS Imaging WI

**REFERRING VET**

Dr. Sherrod

**INVOICE**

36757

**DATE**

4/7/22

**PRESENTING CLINICAL SIGNS**

History of urinating outside of the litter box. Hospitalized and put on fluids for supportive care for 24 hours.

Abnormal PE/Chem/CBC/UA Results: ALT 2264 T Bili 1.4 CBC WNL

**ULTRASONOGRAPHIC EXAMINATION OF THE ABDOMEN****Urinary System**

The urinary bladder is moderately distended with anechoic contents. No masses, inflammatory changes, echogenic sediment or cystoliths are observed. The urinary bladder, trigone and visible pelvic urethra are normal in thickness with a smooth mucosal surface.

Both kidneys are normal in size with smooth peripheral margination. The left kidney measures 4.58 cm and the right kidney measures 4.16 cm. Both kidneys are diffusely echogenic with slightly decreased corticomedullary distinction. On the medial side of the cranial pole of the right kidney, there is a 0.5 cm anechoic center that appears most consistent with a possible strictured proximal ureter. This can be a congenital defect, or associated with migrating nephroliths. No mineral is present in either kidney.

**Adrenal Glands**

The right adrenal gland is normal in size (0.34 cm thick), shape and contour. Corticomedullary structure is unremarkable. Visible surrounding vasculature appears normal.

The left adrenal gland is normal in size (0.40 cm thick), shape and contour. Corticomedullary structure is unremarkable. Visible surrounding vasculature appears normal.

**Spleen**

The spleen is subjectively normal in size with a normal smooth capsular contour. Parenchyma is appropriately finely textured and homogenous with normal echogenicity relative to surrounding tissue (hyperechoic to liver). No focal nodules or masses are observed. Splenic vasculature appears normal.

**Liver**

Liver is subjectively enlarged. Margins are smooth but round. It has a normal homogenous echotexture. Parenchyma is diffusely hyperechoic characterized by less prominent than normal portal vein walls and increased echogenicity relative to the spleen. No focal lesions are observed. Visible vasculature and biliary tree appear normal without distension or congestion.

The gallbladder is moderately distended with anechoic bile and some gravity dependent echogenic sediment and sludge. The wall is smooth without visible thickening. The proximal cystic duct and common bile duct are tortuous, but not overly dilated. There is no evidence of effusion or inflammation.

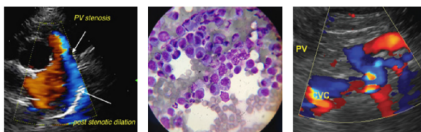
**Gastrointestinal**

The stomach wall is normal in thickness (canine < 0.5 cm and feline < 0.4 cm) and layering. The lumen of the stomach is empty with no evidence of obstruction, foreign material or infiltrative disease. Pyloric outflow tract appears patent.

The visible small intestines are normal in wall thickness and layering (canine duodenum < 0.5 cm and feline duodenum < 0.4 cm; other < 0.3 cm). Small intestinal motility appears adequate (1-3 contractions per min). The lumen of the small intestine is empty with no evidence of obstruction, foreign material or infiltrative disease.

**IMAGING PERFORMED BY**

SVS Mobile Imaging 262-366-5970  
fredgromalak@gmail.com



**Clinical Sonography & Telecytology**

EDUCATIONAL TELECONSULTATION SERVICES™

1-800-838-4268 info@sonopath.com SonoPath.com

**PATIENT**

Thomas Snow

The visible colon is normal in wall thickness (< 0.2 cm) and layering. Contents are consistent with normal formed feces and gas.

**Pancreas****SPECIES**

Feline

The pancreatic parenchyma is appropriately isoechoic to surrounding tissue. Visible capsule is smooth and normal in contour. There is no visible pancreatic duct dilation. There is no evidence of active peripancreatic inflammation.

**BREED**

DLH

**Free Abdomen**

There is no evidence of peritoneal effusion. There is no apparent lymphadenopathy.

**SEX**

Neutered Male

- Hyperechoic hepatomegaly – consistent with benign hepatic lipidosis. Infiltrative disease such as amyloidosis or neoplasia, such as mast cell tumor or less likely, lymphoma, is also possible.
- Cholecystic debris and a tortuous, mildly but not overly dilated cystic and common bile duct – consistent with possible cholangiohepatitis versus an early partial obstruction not visible in these images.
- Bilaterally hyperechoic kidneys with loss of corticomedullary distinction – rule out normal patient variant with fat deposition, given the lack of azotemia, versus juvenile nephropathy, glomerular or interstitial nephritis, chronic pyelonephritis, etc.

**AGE**

3 Years

**WEIGHT**

12 Pounds

**SECONDARY FINDINGS**

- Suspected right proximal ureter stricture – This can be a congenital anomaly or associated with migrating nephrolithiasis.

**INTERPRETED BY**

Beth Johnson, DVM  
DACVIM

**INTERPRETATION OF THE FINDINGS & FURTHER RECOMMENDATIONS**

The kidney changes and suspected ureteral stricture are of unknown clinical significance to this patient's hepatopathy. However, given the inappropriate urination as a presenting complaint, recommendations include a urinalysis and urine culture if indicated based on urinalysis results, as well as close monitoring of lab work for azotemia or SDMA changes, given the appearance of the kidneys. Recommendations are to reassess the right kidney with ultrasound in 4-6 weeks to monitor for progression of ureteral dilation. The finding reported in these images is often of no clinical significance. However, monitoring is necessary to determine long-term effect.

**IMAGING PERFORMED BY**

Kim Liedberg

Recommendations for the increased ALT include infectious disease testing including toxo as well as fine needle aspirate of the liver if patient's coagulation status is appropriate. In the meantime, management of cholangiohepatitis/Triaditis with broad-spectrum antibiotics, liver protectants, ursodiol, +/- gastrointestinal supportive care, if gastrointestinal signs are present, is recommended.

**HOSPITAL NAME**

SVS Imaging WI

**REFERRING VET**

Dr. Sherrod

**INVOICE**

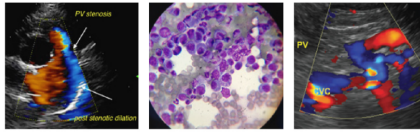

36757

**DATE**

4/7/22

IMAGING PERFORMED BY

SVS Mobile Imaging 262-366-5970  
fredgromalak@gmail.com



Clinical Sonography & Telectology

EDUCATIONAL TELECONSULTATION SERVICES™

1-800-838-4268 info@sonopath.com SonoPath.com

PATIENT

Thomas Snow

SPECIES

Feline

BREED

DLH

SEX

Neutered Male

AGE

3 Years

WEIGHT

12 Pounds

INTERPRETED BY

Beth Johnson, DVM  
DACVIM

IMAGING PERFORMED BY

Kim Liedberg

HOSPITAL NAME

SVS Imaging WI

REFERRING VET

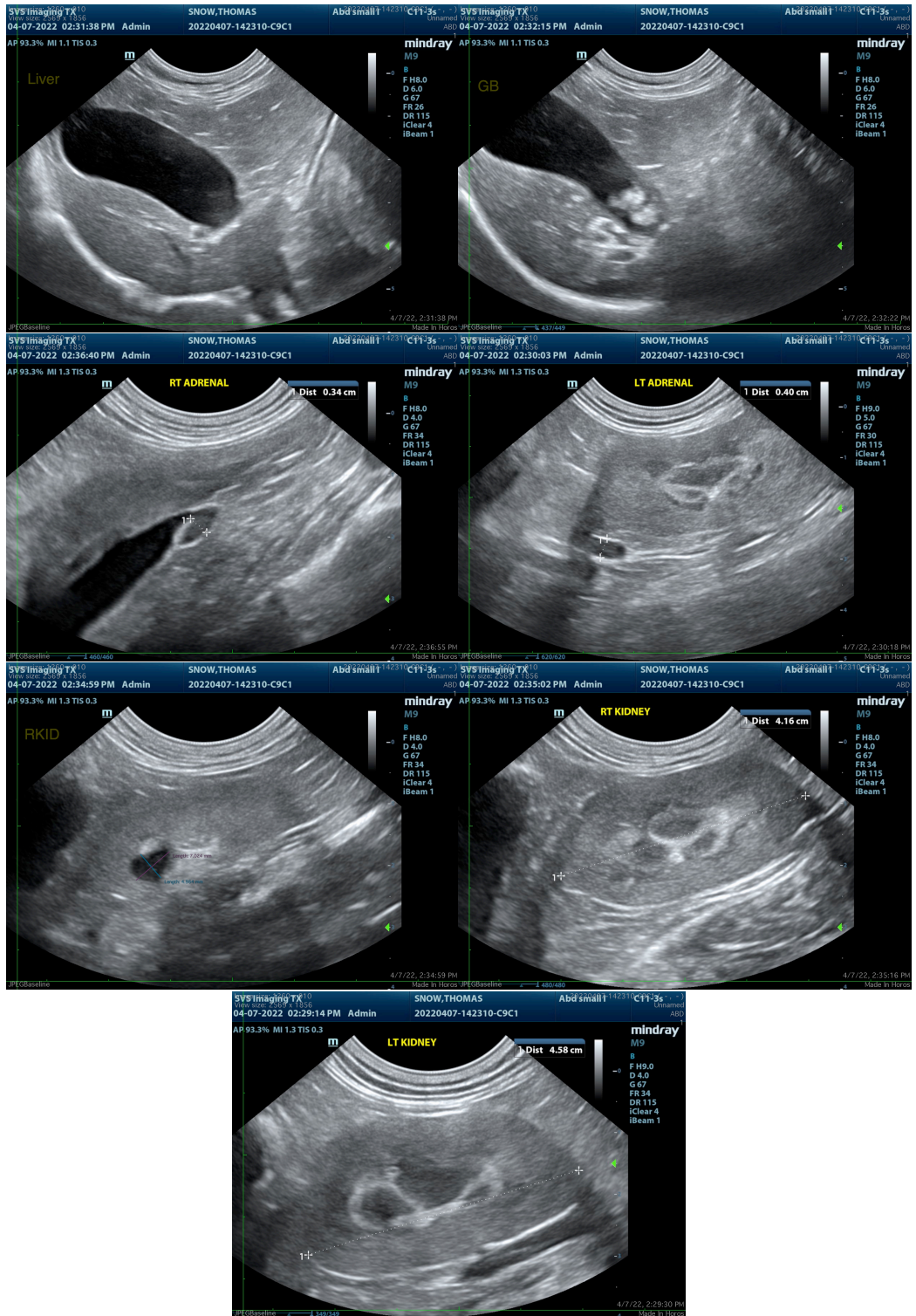
Dr. Sherrod

INVOICE

36757

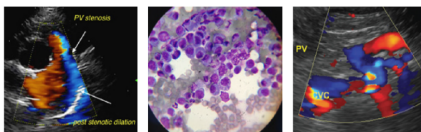
DATE

4/7/22



**IMAGING PERFORMED BY**

SVS Mobile Imaging 262-366-5970  
fredgromalak@gmail.com



*Clinical Sonography & Telectology*

EDUCATIONAL TELECONSULTATION SERVICES™

1-800-838-4268 info@sonopath.com SonoPath.com

**PATIENT**

Thomas Snow

The information and recommendations provided are based on the images presented by the referring veterinarian/sonographer. No evaluation can be communicated regarding pathology that was not visible in the image/video clips provided.

**SPECIES**

Feline

Thank you for this referral. If the clinical or image interpretation does not parallel your findings or if I can be of any further assistance please contact me.

**Beth Johnson, DVM, DACVIM**

Beth.Johnson@sonopath.com

**BREED**

DLH

**SEX**

Neutered Male

**AGE**

3 Years

**WEIGHT**

12 Pounds

**INTERPRETED BY**

Beth Johnson, DVM  
DACVIM

**IMAGING PERFORMED BY**

Kim Liedberg

**HOSPITAL NAME**

SVS Imaging WI

**REFERRING VET**

Dr. Sherrod

**INVOICE**

36757

**DATE**

4/7/22