

**DATE PRESENTING CLINICAL SIGNS**

4/7/22 Increasing ALT over time.

**PATIENT** Current Medications: Denamarin medium sized dog ½ SID since August 2021.

Milka Mangold

Lab Results: Blood (CBC, IOF) all WNL except ALT. Today- 290, 8/21- 209, 6/25- 219, 12/20- 180, 6/20- 166 (10-125).

Date of Previous IntraPet Ultrasound: No previous.

**SPECIES** Sedation: Not required to complete full diagnostic ultrasound.

Canine

Stat Report: Not requested.

**ULTRASONOGRAPHIC EXAMINATION OF THE ABDOMEN****BREED** *Urinary System*

Basenji

The urinary bladder is moderately distended with anechoic contents. No masses, inflammatory changes, echogenic sediment or cystoliths are observed. The urinary bladder, trigone and visible pelvic urethra are normal in thickness with a smooth mucosal surface.

**SEX**

Spayed Female

The right kidney is normal in size (5.24 cm), shape and echogenicity. It has smooth peripheral margination. There is a normal 1:3 cortex to medulla ratio with appropriate corticomedullary distinction. There is no evidence of pyelectasia, mineral or infarcts observed.

**AGE**

1/23/12

The left kidney is normal in size (4.52 cm), shape and echogenicity. It has smooth peripheral margination. There is a normal 1:3 cortex to medulla ratio with appropriate corticomedullary distinction. There is no evidence of pyelectasia, mineral or infarcts observed.

**WEIGHT**

22.8 Pounds

**Adrenal Glands****INTERPRETED BY**Beth Johnson, DVM  
DACVIM

The right adrenal gland is normal in size (2.27 cm long x 0.47 cm at the cranial pole and 0.48 cm at the caudal pole), shape and contour. Corticomedullary structure is unremarkable. Visible surrounding vasculature appears normal.

The left adrenal gland is normal in size (1.95 cm long x 0.52 cm at the cranial pole and 0.65 cm at the caudal pole), shape and contour. Corticomedullary structure is unremarkable. Visible surrounding vasculature appears normal.

**IMAGING PERFORMED BY**Stephanie Pearce  
RDMS, RVT**Spleen**

Spleen is subjectively normal in size with a normal smooth capsular contour. Parenchyma is appropriately finely textured and homogenous with normal echogenicity relative to surrounding tissue (hyperechoic to liver). Multifocal well-demarcated hyperechoic homogenous nodules are present. Splenic vasculature appears normal.

**HOSPITAL NAME**

Banfield Columbia

**Liver**

The liver is subjectively enlarged in size with rounded/scalloped margins. Parenchyma is heterogeneous, characterized by multifocal well-defined, hypoechoic nodules of varying sizes, with the largest, most discrete nodule measuring 3.0 cm x 2.0 cm and lying just caudal to the gallbladder. Visible vasculature and biliary tree appear normal without distention or congestion.

**REFERRING VET**

Dr. Landon

**INVOICE**

36745

GB contains a moderate amount of non-dependent, mildly aggregated/inspissated sludge. Hypo to anechoic cystic areas are noted between the gallbladder sludge and luminal wall. The wall is otherwise smooth without visible thickening. There is no evidence of cystic or CBD dilation. There is no evidence of effusion.

### ***Gastrointestinal***

The stomach wall is normal in thickness (canine < 0.5 cm and feline < 0.4 cm) and layering. The lumen of the stomach is empty with no evidence of obstruction, foreign material or infiltrative disease. Pyloric outflow tract appears patent.

The visible small intestines are normal in wall thickness and layering (canine duodenum < 0.5 cm and feline duodenum < 0.4 cm; other < 0.3 cm). Small intestinal motility appears adequate (1-3 contractions per min). The lumen of the small intestine is empty with no evidence of obstruction, foreign material or infiltrative disease.

The visible colon is normal in wall thickness (< 0.2 cm) and layering. Contents are consistent with normal formed feces and gas.

### ***Pancreas***

The pancreatic parenchyma is appropriately isoechoic to surrounding tissue. Visible capsule is smooth and normal in contour. There is no visible pancreatic duct dilation. There is no evidence of active peripancreatic inflammation.

### ***Free Abdomen***

There is no evidence of peritoneal effusion. There is a 0.73 cm thick hypoechoic medial iliac lymph node visible in these images. No other lymphadenopathy noted.

## **PRIMARY FINDINGS**

- Nodular hepatopathy – Differentials include both benign disease such as nodular hyperplasia as well as infiltrative round cell or metastatic neoplasia.

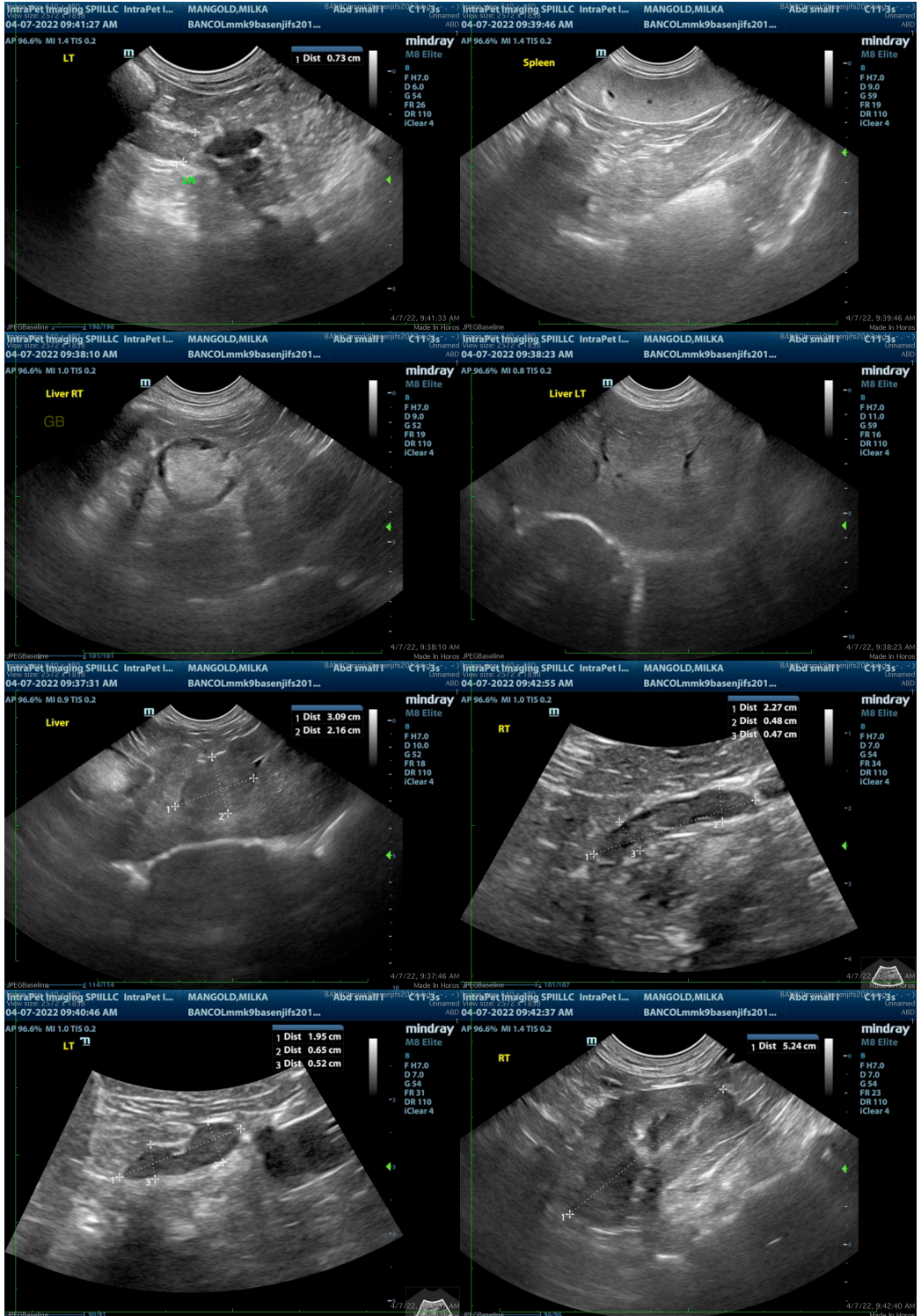
## **SECONDARY FINDINGS**

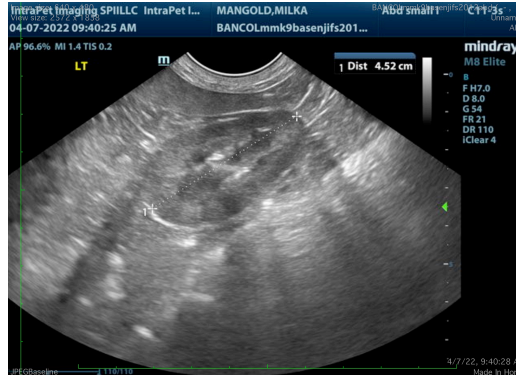- Hyperechoic splenic nodules – most consistent with benign myelolipomas. Other differentials such as fibrosis or calcification caused by old hematomas or infarcts, chronic inflammation, granulomatous disease or metastatic disease cannot be ruled out, but are less likely.
- Early mucocele – Cholecystic debris is of unknown clinical significance. It can be seen with biliary stasis from fasting or illness. Cholecystic debris is not necessarily related to hepatobiliary disease. The non-dependent nature of this sludge combined with the cystic areas are suggestive, however, of possible emerging cystic mucosal hyperplasia or early gallbladder mucocele.
- Medial iliac lymphadenopathy – rule out normal variant versus reactive node most likely.

## **INTERPRETATION OF THE FINDINGS & FURTHER RECOMMENDATIONS**

Given the concern for possible infiltrative round cell neoplasia, a fine needle aspirate of the liver is recommended if patient's coagulation status is appropriate. Testing for Leptospirosis could be considered if not recently evaluated. However, the appearance of the liver is less consistent with Leptospirosis. If a diagnosis is not obtained cytologically, liver biopsy/nodule/mass removal may be necessary to definitively determine the underlying cause of the increased ALT, at which time the gallbladder could be assessed for patency and removed, if necessary.

The medial iliac lymph node is considered likely reactive. However, a rectal exam is recommended to rule out colorectal pathology, if not recently evaluated.





The information and recommendations provided are based on the images presented by the referring veterinarian/sonographer. No evaluation can be communicated regarding pathology that was not visible in the image/video clips provided.

Thank you for this referral. If the clinical or image interpretation does not parallel your findings or if I can be of any further assistance please contact me.

**Beth Johnson, DVM, DACVIM**  
Beth.Johnson@sonopath.com