



**PATIENT**

Aoife Greb

**SPECIES**

Canine

**BREED**

Lhasa Apso

**SEX**

Spayed Female

**AGE**

12.5 Years

**WEIGHT**

17 Pounds

**INTERPRETED BY**

Beth Johnson, DVM  
DACVIM

**IMAGING PERFORMED BY**

Dr. Porter

**HOSPITAL NAME**

Willamette VH

**REFERRING VET**

Dr. Porter

**INVOICE**

36748

**DATE**

4/7/22

**PRESENTING CLINICAL SIGNS**

Thin coat, LDSST normal about a year ago Hx of elevated liver values Labwork before starting NSAIDs, Abnormal PE/Chem/CBC/UA Results: ALT 337 IU/L ALP 2063 IU/L (1,002 in Jan 21) GGT 57 IU/L (31 in Jan 21) Cholesterol 362 mg/dL Triglyceride 747 mg/dL

**ULTRASONOGRAPHIC EXAMINATION OF THE ABDOMEN**

**Urinary System**

The urinary bladder is moderately distended with anechoic contents. No masses, inflammatory changes, echogenic sediment or cystoliths are observed. The urinary bladder, trigone and visible pelvic urethra are normal in thickness with a smooth mucosal surface.

The right kidney is normal in size (4.62 cm), shape and echogenicity. It has smooth peripheral margination. There is a normal 1:3 cortex to medulla ratio with appropriate corticomedullary distinction. There is no evidence of pyelectasia, mineral or infarcts observed.

The left kidney is normal in size (3.74 cm), shape and echogenicity. It has smooth peripheral margination. There is a normal 1:3 cortex to medulla ratio with appropriate corticomedullary distinction. There is no evidence of pyelectasia, mineral or infarcts observed.

**Adrenal Glands**

The right adrenal gland is normal in size (0.48 cm at the cranial pole and 0.61 cm at the caudal pole), shape and contour. Corticomedullary structure is unremarkable. Visible surrounding vasculature appears normal.

The left adrenal gland is normal in size (1.32 cm long x 0.35 cm at the cranial pole and 0.42 cm at the caudal pole), shape and contour. Corticomedullary structure is unremarkable. Visible surrounding vasculature appears normal.

**Spleen**

The spleen is subjectively normal in size with a normal smooth capsular contour. Parenchyma is appropriately finely textured and homogenous with normal echogenicity relative to surrounding tissue (hyperechoic to liver). No focal nodules or masses are observed. Splenic vasculature appears normal.

**Liver**

The liver is subjectively normal in size, and echogenicity with smooth peripheral margins. The parenchyma is heterogenous in echotexture with subtle, indistinct focal mottling. The visible portions of the vasculature and biliary tract appear normal. No focal nodules or cystic lesions are observed.

The gall bladder lumen is moderately distended. The wall of the gall bladder is not thickened and has a smooth mucosal surface. There is a moderate amount of non-organized echogenic debris. The cystic and common bile ducts are normal/not visible.

**Gastrointestinal**

The stomach wall is normal in thickness (canine < 0.5 cm and feline < 0.4 cm) and layering. The lumen of the stomach is empty with no evidence of obstruction, foreign material or infiltrative disease. Pyloric outflow tract appears patent.

The visible small intestines are normal in wall thickness and layering (canine duodenum < 0.5 cm and feline duodenum < 0.4 cm; other < 0.3 cm). Small intestinal motility appears adequate (1-3 contractions



**PATIENT**

Aoife Greb

per min). The lumen of the small intestine is empty with no evidence of obstruction, foreign material or infiltrative disease.

The visible colon is normal in wall thickness (< 0.2 cm) and layering. Contents are consistent with normal formed feces and gas.

**SPECIES**

Canine

***Pancreas***

The pancreatic parenchyma is appropriately isoechoic to surrounding tissue. Visible capsule is smooth and normal in contour. There is no visible pancreatic duct dilation. There is no evidence of active peripancreatic inflammation.

**BREED**

Lhasa Apso

***Free Abdomen***

There is no evidence of peritoneal effusion. There is no apparent lymphadenopathy.

**SEX**

Spayed Female

**ULTRASONOGRAPHIC FINDINGS**

**AGE**

12.5 Years

- Heterogenous liver – Differentials for hepatic changes include both benign steroid (vacuolar) hepatopathy or extramedullary hematopoiesis as well as infiltrative round cell or metastatic neoplasia.
- Gallbladder debris - Cholecystic debris is of unknown clinical significance. It can be seen with biliary stasis from fasting or illness. Cholecystic debris is not necessarily related to hepatobiliary disease. Echogenic bile is most commonly an incidental finding in dogs and should be interpreted in combination with clinical signs such as nausea, inappetence, cranial abdominal discomfort and/or laboratory changes such as increased ALP and/or increased Tbili.

**WEIGHT**

17 Pounds

**INTERPRETATION OF THE FINDINGS & FURTHER RECOMMENDATIONS**

**INTERPRETED BY**

Beth Johnson, DVM  
DACVIM

Differentials for this patient's liver enzyme changes do include hyperadrenocorticism with concurrent gallbladder sludge and a steroid hepatopathy, which can be present despite normal appearing adrenal glands. Therefore, if clinical signs of hyperadrenocorticism are present such as polyuria, polydipsia, polyphagia, etc., a recheck low-dose Dexamethasone suppression test could be considered, and, if negative, a full adrenal panel to the University of Tennessee could be considered to rule out atypical hyperadrenocorticism.

**IMAGING PERFORMED BY**

Dr. Porter

Otherwise, empirical therapy with broad-spectrum antibiotics and Ursodiol could be tried empirically with monitoring of liver values for improvement in case cholangitis is contributing to the laboratory changes. Given the liver enzyme changes, other pain management options such as Galliprant or Gabapentin could be considered versus a non-steroidal. However, pain management ultimately is a quality of life decision, and if nonsteroidals are necessary to maintain quality of life, close monitoring of liver values for progression while on nonsteroidals, is recommended .

**HOSPITAL NAME**

Willamette VH

**REFERRING VET**

Dr. Porter

**INVOICE**

36748

**DATE**

4/7/22



**PATIENT**

Aoife Greb

**SPECIES**

Canine

**BREED**

Lhasa Apso

**SEX**

Spayed Female

**AGE**

12.5 Years

**WEIGHT**

17 Pounds

**INTERPRETED BY**

Beth Johnson, DVM  
DACVIM

**IMAGING PERFORMED BY**

Dr. Porter

**HOSPITAL NAME**

Willamette VH

**REFERRING VET**

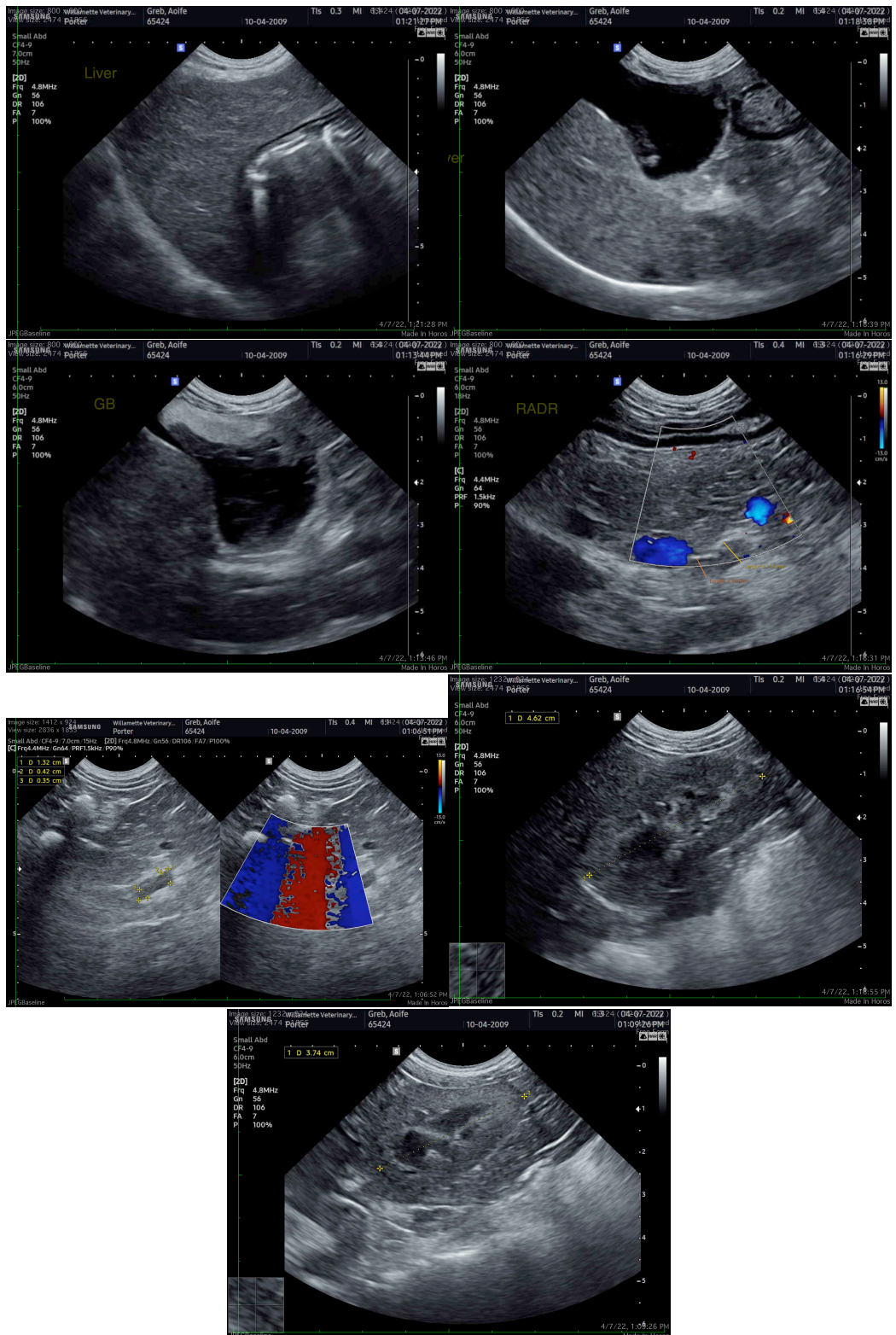
Dr. Porter

**INVOICE**

36748

**DATE**

4/7/22





**PATIENT**

Aoife Greb

The information and recommendations provided are based on the images presented by the referring veterinarian/sonographer. No evaluation can be communicated regarding pathology that was not visible in the image/video clips provided.

**SPECIES**

Canine

Thank you for this referral. If the clinical or image interpretation does not parallel your findings or if I can be of any further assistance please contact me.

**Beth Johnson, DVM, DACVIM**

Beth.Johnson@sonopath.com

**BREED**

Lhasa Apso

**SEX**

Spayed Female

**AGE**

12.5 Years

**WEIGHT**

17 Pounds

**INTERPRETED BY**

Beth Johnson, DVM  
DACVIM

**IMAGING  
PERFORMED BY**

Dr. Porter

**HOSPITAL NAME**

Willamette VH

**REFERRING VET**

Dr. Porter

**INVOICE**

36748

**DATE**

4/7/22