



PATIENT

Molly Peiffer

SPECIES

Canine

BREED

Chihuahua/Mix

SEX

Spayed Female

AGE

11 Years

WEIGHT

24

INTERPRETED BY

Beth Johnson, DVM,
DACVIM (SAIM)

IMAGING PERFORMED BY

Robert Mason, DVM

HOSPITAL NAME

Straley VA

REFERRING VET

Sadie Hubler, DVM

INVOICE

36490

DATE

4/6/26

PRESENTING CLINICAL SIGNS

- Elevated liver values on wellness blood work. Treated with Ursodiol, Values have increased more.
- No clinical signs.
- Abnormal PE/Chem/CBC/UA Results: 3/24/26 ALT 212 (10-125) ALP 1,876 (23-212) GGT 19 (0-11) Cholesterol 341 (110-320) 7/3/25 ALP 1,354 ALT 89

ULTRASONOGRAPHIC EXAMINATION OF THE ABDOMEN

Urinary System

Urinary bladder is adequately distended. It has a normal uniform wall thickness. Contents include primarily anechoic fluid with a large amount of echogenic non-shadowing debris, most consistent with exfoliated cells, mucous and/or small blood clots. Both sterile inflammation as well as urinary tract infection can present with echogenic debris. No masses or cystoliths are observed. The trigone and visible pelvic urethra are normal in thickness with a smooth mucosal surface.

Left kidney is normal in size (5.2 cm), shape and echogenicity. It has smooth peripheral margination. There is a normal 1:3 cortex to medulla ratio with appropriate corticomedullary distinction. There is no evidence of pyelectasia, mineral or infarcts observed.

Right kidney is normal in size (5.6 cm), shape and echogenicity. It has smooth peripheral margination. There is a normal 1:3 cortex to medulla ratio with appropriate corticomedullary distinction. There is no evidence of pyelectasia, mineral or infarcts observed.

Adrenal Glands

Left adrenal gland is normal in size (0.55 cm at cranial pole and 0.66 cm at caudal pole), shape and overall architecture, echogenicity and echotexture. Visible surrounding vasculature appears normal.

Right adrenal gland is normal in size (0.9 cm at cranial pole and 0.73 cm at caudal pole), shape and overall architecture, echogenicity and echotexture. Visible surrounding vasculature appears normal.

Spleen

Spleen is subjectively normal in size with a normal smooth capsular contour. Parenchyma is appropriately finely textured and homogenous with normal echogenicity relative to surrounding tissue (hyperechoic to liver). No focal nodules or masses are observed. Splenic vasculature appears normal.

Liver

Liver is subjectively enlarged with mildly irregular margins. Parenchyma is moderately heterogenous characterized by multiple poorly defined hypoechoic nodules within otherwise hyperechoic liver parenchyma. Visible vasculature and biliary tree appear normal without distension or congestion.

Gallbladder is mildly overdistended with a moderate amount of non-dependent, mildly aggregated/inspissated sludge. Hypo to anechoic cystic areas are noted between the gallbladder sludge and luminal wall. The wall is otherwise smooth without visible thickening. There is no evidence of cystic or CBD dilation. There is no evidence of effusion.



PATIENT

Molly Peiffer

SPECIES

Canine

BREED

Chihuahua/Mix

SEX

Spayed Female

AGE

11 Years

WEIGHT

24

INTERPRETED BY

Beth Johnson, DVM,
DACVIM (SAIM)

IMAGING PERFORMED BY

Robert Mason, DVM

HOSPITAL NAME

Straley VA

REFERRING VET

Sadie Hubler, DVM

INVOICE

36490

DATE

4/6/26

Gastrointestinal

The visible stomach wall is normal in thickness and layering. The lumen of the stomach is empty with no evidence of obstruction, foreign material or infiltrative disease. Pyloric outflow tract appears patent.

The visible small intestines are normal in wall thickness and layering. Small intestinal motility appears adequate (1-3 contractions per min). The lumen of the small intestine is empty with no evidence of obstruction, foreign material or infiltrative disease.

The visible colon is normal in wall thickness (< 0.2 cm) and layering. Contents are consistent with normal formed feces and gas.

Pancreas

The pancreas that is observed appears appropriately isoechoic to surrounding omental fat. Visible capsule is smooth and normal in contour. Visible pancreatic parenchyma is homogenous and unremarkable. There is no visible pancreatic duct dilation. There is no evidence of active peripancreatic inflammation.

Free Abdomen

There is no visible free peritoneal effusion noted in these images.

There is no apparent pathologic lymphadenopathy noted in these images.

ULTRASONOGRAPHIC FINDINGS

- Emerging gallbladder mucocele- Cholecystic debris is of unknown clinical significance. It can be seen with biliary stasis from fasting or illness. Cholecystic debris is not necessarily related to hepatobiliary disease. The non-dependent nature of this sludge combined with the cystic areas are suggestive, however, of possible emerging cystic mucosal hyperplasia or early gallbladder mucocele.
- Moderately heterogenous liver- These changes are most consistent with benign processes such as nodular hyperplasia, steroid (vacuolar) hepatopathy, extramedullary hematopoiesis or possibly chronic inflammatory disease and less commonly infiltrative round cell or metastatic neoplasia.
- A large amount of echogenic urinary bladder debris.

INTERPRETATION OF THE FINDINGS & FURTHER RECOMMENDATIONS

If not recently evaluated, urinalysis, and if indicated based on urinalysis results, urine culture is recommended. If protein is present in an otherwise quiet sediment, protein quantification with a urine protein to creatinine ration is recommended.

Differentials for a primary cholestatic liver enzyme pattern (increased ALP) are vast and non-specific. Differentials include, but are not limited to, benign nodular hyperplasia which occurs in 70% of older dogs and often does not result in an abnormal ultrasound, reactive or idiopathic/vacuolar hepatopathy, cholestasis and/or hyperadrenocorticism as well as many chronic non-hepatobiliary diseases such as chronic infections/inflammation from dental disease, IBD, neoplasia, hyperlipidemia, hypothyroidism, chronic pancreatitis, chronic stress, etc.



PATIENT

Molly Peiffer

SPECIES

Canine

BREED

Chihuahua/Mix

SEX

Spayed Female

AGE

11 Years

WEIGHT

24

INTERPRETED BY

Beth Johnson, DVM,
DACVIM (SAIM)

IMAGING PERFORMED BY

Robert Mason, DVM

HOSPITAL NAME

Straley VA

REFERRING VET

Sadie Hubler, DVM

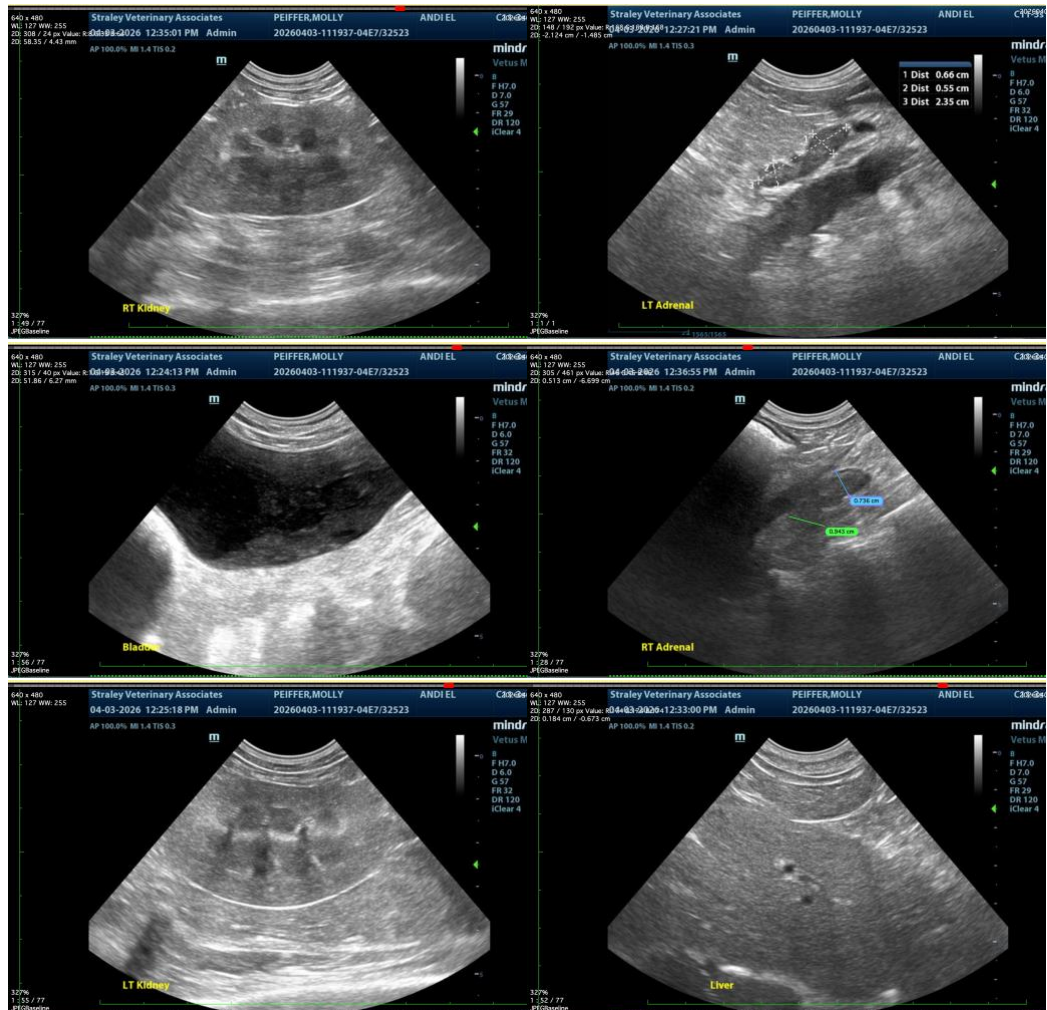
INVOICE

36490

DATE

4/6/26

- Adrenocortical testing such as a low dose dexamethasone suppression test could be considered if clinical signs of hyperadrenocorticism are present.
- In an asymptomatic patient, further intervention for the emerging mucocele may not be necessary or elected. If patient is and/or becomes symptomatic, however, and/or a preemptive more aggressive intervention is elected, an exploratory laparotomy for planned cholecystectomy and liver biopsy could be considered.
- A fine needle aspirate of the liver could be considered if patient's coagulation status is appropriate.
- Otherwise, recommendations include addressing any other concurrent disease and monitoring. If values are progressive, recheck imaging is recommended.





PATIENT

Molly Peiffer

SPECIES

Canine

BREED

Chihuahua/Mix

SEX

Spayed Female

AGE

11 Years

WEIGHT

24

INTERPRETED BY

Beth Johnson, DVM,
DACVIM (SAIM)

IMAGING PERFORMED BY

Robert Mason, DVM

HOSPITAL NAME

Straley VA

REFERRING VET

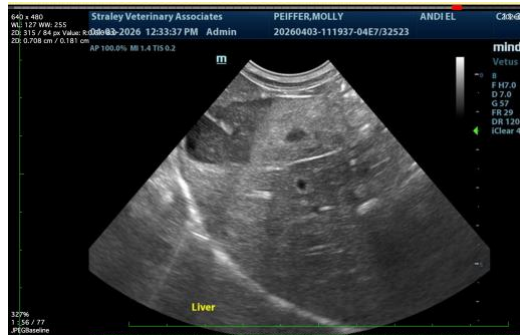Sadie Hubler, DVM

INVOICE

36490

DATE

4/6/26



The information and recommendations provided are based on the images presented by the referring veterinarian/sonographer. No evaluation can be communicated regarding pathology that was not visible in the image/video clips provided.

Thank you for this referral. If the clinical or image interpretation does not parallel your findings or if I can be of any further assistance please contact me.

Beth Johnson, DVM DACVIM

info@sonopath.com