



PATIENT

Bella Rodgers

PRESENTING CLINICAL SIGNS

patient had abdominal ultrasound and revealed had mass within the bladder about 6 months ago. This ultrasound is a follow up to assess the mass within the bladder but also check the other organs.

SPECIES

Canine

ULTRASONOGRAPHIC EXAMINATION OF THE ABDOMEN

Urinary System

BREED

Yorkie

The urinary bladder is moderately distended with anechoic contents. There is a solitary, broad-based mass lesion along the dorsal wall of the trigone measuring 1.0 cm x 2.0 cm. The mass is hyperechoic in echogenicity and heterogenous in echotexture. It does not appear to extend into the proximal urethra.

SEX

Spayed Female

The right kidney is normal in size (5.3 cm), shape and echogenicity. It has smooth peripheral margination. There is a normal 1:3 cortex to medulla ratio with appropriate corticomedullary distinction. There is no evidence of pyelectasia, mineral or infarcts observed.

AGE

9 Years

The left kidney is normal in size (4.7 cm), shape and echogenicity. It has smooth peripheral margination. There is a normal 1:3 cortex to medulla ratio with appropriate corticomedullary distinction. There is no evidence of pyelectasia, mineral or infarcts observed.

Adrenal Glands

WEIGHT

16 Pounds

The left adrenal gland is enlarged in size (1.7 cm at the cranial pole, 0.74 cm at the caudal pole) Normal shape and contour are maintained. Corticomedullary structure is unremarkable. Visible surrounding vasculature appears normal.

The right adrenal gland is enlarged in size (0.75 cm at the cranial pole, 0.8 cm at the caudal pole). Normal shape and contour are maintained. Corticomedullary structure is unremarkable. Visible surrounding vasculature appears normal.

INTERPRETED BY

Beth Johnson, DVM
DACVIM

Spleen

The spleen is subjectively normal in size with a normal smooth capsular contour. Parenchyma is appropriately finely textured and homogenous with normal echogenicity relative to surrounding tissue (hyperechoic to liver). No focal nodules or masses are observed. Splenic vasculature appears normal.

IMAGING PERFORMED BY

Dr. Anthony Smatt

Liver

HOSPITAL NAME

The Pets I Love

The liver is subjectively normal in size with normal smooth curvilinear peripheral contour. Parenchyma is appropriately hypoechoic to the spleen in echogenicity and appropriately mildly coarse and homogenous in echotexture. No focal lesions are observed. Visible vasculature and biliary tree appear normal without distension or congestion.

REFERRING VET

Dr. Anthony Smatt

GB is moderately distended with anechoic bile and gravity dependent echogenic sediment. The wall is smooth without visible thickening. There is no evidence of cystic or CBD dilation. There is no evidence of effusion or inflammation.

INVOICE

36786

Gastrointestinal

The stomach wall is normal in thickness (canine < 0.5 cm and feline < 0.4 cm) and layering. The lumen of the stomach is empty with no evidence of obstruction, foreign material or infiltrative disease. Pyloric outflow tract appears patent.

DATE

4/6/22

The visible small intestines are normal in wall thickness and layering (canine duodenum < 0.5 cm and feline duodenum < 0.4 cm; other < 0.3 cm). Small intestinal motility appears adequate (1-3 contractions



PATIENT

Bella Rodgers

per min). The lumen of the small intestine is empty with no evidence of obstruction, foreign material or infiltrative disease.

The visible colon is normal in wall thickness (< 0.2 cm) and layering. Contents are consistent with normal formed feces and gas.

SPECIES

Canine

Pancreas

The pancreatic parenchyma is appropriately isoechoic to surrounding tissue. Visible capsule is smooth and normal in contour. There is no visible pancreatic duct dilation. There is no evidence of active peripancreatic inflammation.

BREED

Yorkie

Free Abdomen

There is no evidence of peritoneal effusion. There is no apparent lymphadenopathy.

SEX

Spayed Female

PRIMARY FINDINGS

AGE

9 Years

- Urinary bladder wall mass – most concerning for infiltrative neoplasia such as transitional cell carcinoma. Chronic cystitis cannot be ruled out, but is considered less likely given the location and appearance of the mass.
- Bilateral adrenomegaly – consistent with adrenal hyperplasia secondary to pituitary depending hyperadrenocorticism vs normal variant.

WEIGHT

16 Pounds

SECONDARY FINDINGS

- Gallbladder debris - Cholecystic debris is of unknown clinical significance. It can be seen with biliary stasis from fasting or illness. Cholecystic debris is not necessarily related to hepatobiliary disease. Echogenic bile is most commonly an incidental finding in dogs and should be interpreted in combination with clinical signs such as nausea, inappetence, cranial abdominal discomfort and/or laboratory changes such as increased ALP and/or increased Tbili.

INTERPRETED BY

Beth Johnson, DVM
DACVIM

INTERPRETATION OF THE FINDINGS & FURTHER RECOMMENDATIONS

IMAGING PERFORMED BY

Dr. Anthony Smatt

Recommendations include a urinalysis and urine culture as well as submission of urine to look for BRAF gene mutation, which is associated with urinary bladder cancer. Other diagnostic options could include a fine needle aspirate of the mass with small risk of tumor seeding/trailing.

HOSPITAL NAME

The Pets I Love

If clinical signs of hyperadrenocorticism such as polyuria, polydipsia, polyphagia, etc. are present, testing for hyperadrenocorticism in the form of a low-dose Dexamethasone suppression test could be considered. However, hyperadrenocorticism is considered a secondary problem, given the concern for bladder cancer. Other recommendations include 3-view thoracic radiographs for further evaluation of possible metastatic disease.

REFERRING VET

Dr. Anthony Smatt

INVOICE

36786

DATE

4/6/22



PATIENT

Bella Rodgers

SPECIES

Canine

BREED

Yorkie

SEX

Spayed Female

AGE

9 Years

WEIGHT

16 Pounds

INTERPRETED BY

Beth Johnson, DVM
DACVIM

IMAGING PERFORMED BY

Dr. Anthony Smatt

HOSPITAL NAME

The Pets I Love

REFERRING VET

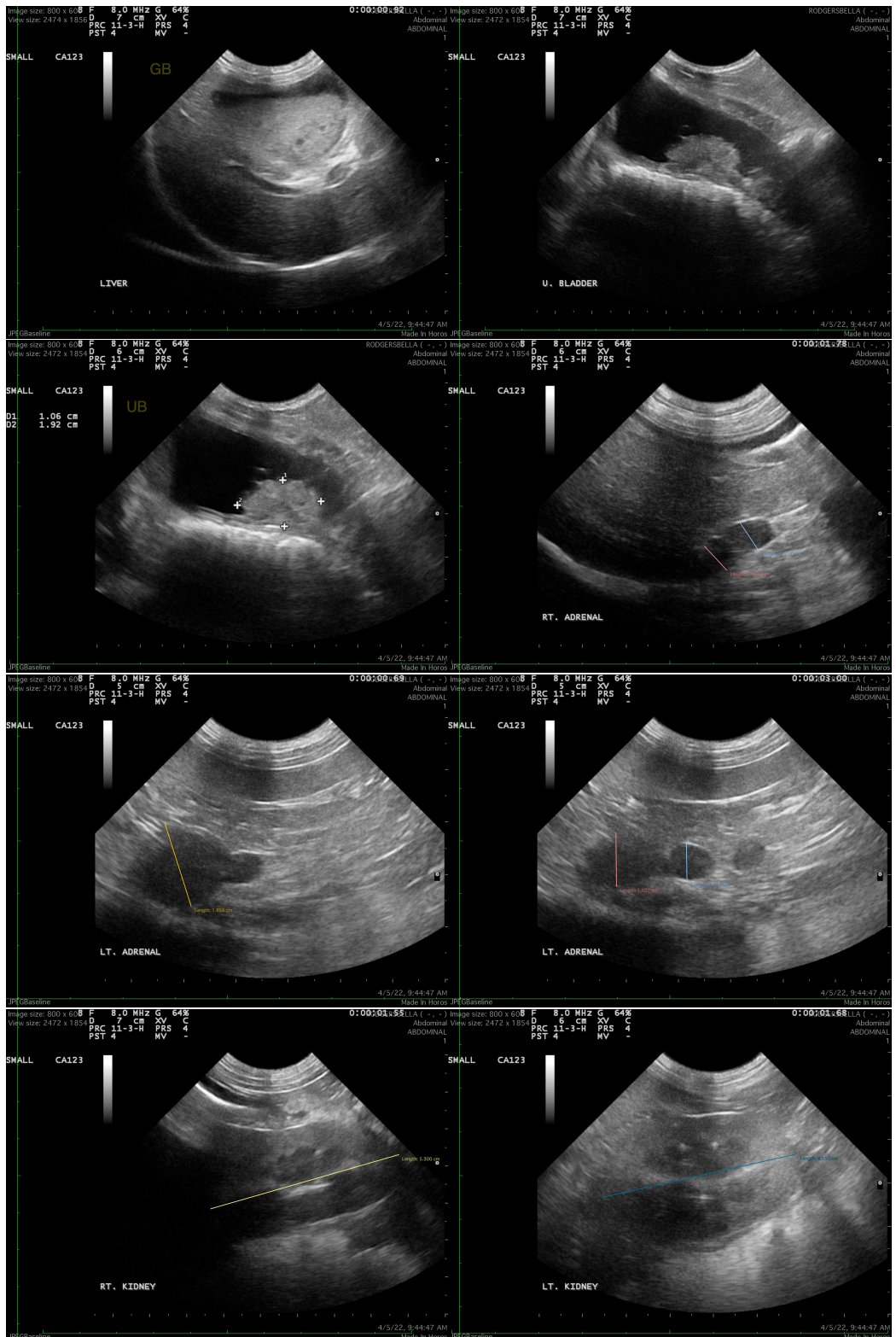
Dr. Anthony Smatt

INVOICE

36786

DATE

4/6/22





PATIENT

Bella Rodgers

The information and recommendations provided are based on the images presented by the referring veterinarian/sonographer. No evaluation can be communicated regarding pathology that was not visible in the image/video clips provided.

SPECIES

Canine

Thank you for this referral. If the clinical or image interpretation does not parallel your findings or if I can be of any further assistance please contact me.

Beth Johnson, DVM, DACVIM

Beth.Johnson@sonopath.com

BREED

Yorkie

SEX

Spayed Female

AGE

9 Years

WEIGHT

16 Pounds

INTERPRETED BY

Beth Johnson, DVM
DACVIM

**IMAGING
PERFORMED BY**

Dr. Anthony Smatt

HOSPITAL NAME

The Pets I Love

REFERRING VET

Dr. Anthony Smatt

INVOICE

36786

DATE

4/6/22