



PATIENT

Rafi Davidson

SPECIES

Canine

BREED

Yorkshire Terrier

SEX

Neutered Male

AGE

11 Years

WEIGHT

16.8 Pounds

PRESENTING CLINICAL SIGNS

Recheck liver "mass effect" area - had U/S 2/22/23 with FNA done on 3/8/23 (vacuolar hepatopathy. No current meds.

Abnormal PE/Chem/CBC/UA Results: ALT 133, AP 159. (2/16/23).

ULTRASONOGRAPHIC EXAMINATION OF THE ABDOMEN

Urinary System

The urinary bladder is moderately distended with anechoic contents. No masses, inflammatory changes, echogenic sediment or cystoliths are observed. The urinary bladder, trigone and visible pelvic urethra are normal in thickness with a smooth mucosal surface.

Prostate is normal in size, echotexture and echogenicity for a neutered male.

The right kidney is normal in size (4.36 cm), shape and echogenicity. It has smooth peripheral margination. There is a normal 1:3 cortex to medulla ratio with appropriate corticomedullary distinction. There is no evidence of pyelectasia, mineral or infarcts observed.

The left kidney is normal in size (4.22 cm), shape and echogenicity. It has smooth peripheral margination. There is a normal 1:3 cortex to medulla ratio with appropriate corticomedullary distinction. There is no evidence of pyelectasia, mineral or infarcts observed.

INTERPRETED BY

Beth Johnson, DVM
DACVIM

Adrenal Glands

The right adrenal gland is normal in size (1.7 cm long x 0.95 cm at the cranial pole and 0.72 cm at the caudal pole), shape and contour. Corticomedullary structure is unremarkable. Visible surrounding vasculature appears normal.

The left adrenal gland is normal in size (1.76 cm long x 0.48 cm at the cranial pole and 0.48 cm at the caudal pole), shape and contour. Corticomedullary structure is unremarkable. Visible surrounding vasculature appears normal.

IMAGING PERFORMED BY

Kelly Vazquez

Spleen

The spleen is subjectively normal in size with a normal smooth capsular contour. Parenchyma is appropriately finely textured and homogenous with normal echogenicity relative to surrounding tissue (hyperechoic to liver). No focal nodules or masses are observed. Splenic vasculature appears normal.

HOSPITAL NAME

Animal General
on the Hudson

Liver

Liver is subjectively enlarged with mildly irregular margins. Parenchyma is heterogenous characterized by multiple poorly defined hypoechoic nodules within otherwise hyperechoic liver parenchyma. The discrete homogeneous nodule/mass described previously is similar in appearance, measuring 1.5 cm x 2.0 cm in today's study. Visible vasculature and biliary tree appear normal without distension or congestion.

REFERRING VET

Dr. Karen Zelinski

INVOICE

46431

DATE

4/5/23

The gallbladder is non-distended in size. The wall is smooth without visible thickening. Luminal contents are primarily anechoic. There is no evidence of cystic or common bile duct dilation.

Gastrointestinal

The stomach wall is normal in thickness (canine < 0.5 cm and feline < 0.4 cm) and layering. The lumen of the stomach is empty with no evidence of obstruction, foreign material or infiltrative disease. Pyloric outflow tract appears patent.



PATIENT

Rafi Davidson

The visible small intestines are normal in wall thickness and layering (canine duodenum < 0.5 cm and feline duodenum < 0.4 cm; other < 0.3 cm). Small intestinal motility appears adequate (1-3 contractions per min). The lumen of the small intestine is empty with no evidence of obstruction, foreign material or infiltrative disease.

SPECIES

Canine

The visible colon is normal in wall thickness (< 0.2 cm) and layering. Contents are consistent with normal formed feces and gas.

BREED

Pancreas

Yorkshire Terrier

The pancreatic parenchyma is appropriately isoechoic to surrounding tissue. Visible capsule is smooth and normal in contour. There is no visible pancreatic duct dilation. There is no evidence of active peripancreatic inflammation.

SEX

Neutered Male

Free Abdomen

AGE

11 Years

There is no evidence of free peritoneal effusion noted in these images.

There is no apparent lymphadenopathy noted in these images.

WEIGHT

16.8 Pounds

ULTRASONOGRAPHIC FINDINGS

- **Heterogenous Liver** – These changes are most consistent with benign processes such as nodular hyperplasia, steroid (vacuolar) hepatopathy, extramedullary hematopoiesis or possibly chronic inflammatory disease and less commonly infiltrative round cell or metastatic neoplasia. The appearance is static to the previous ultrasound.

INTERPRETED BY

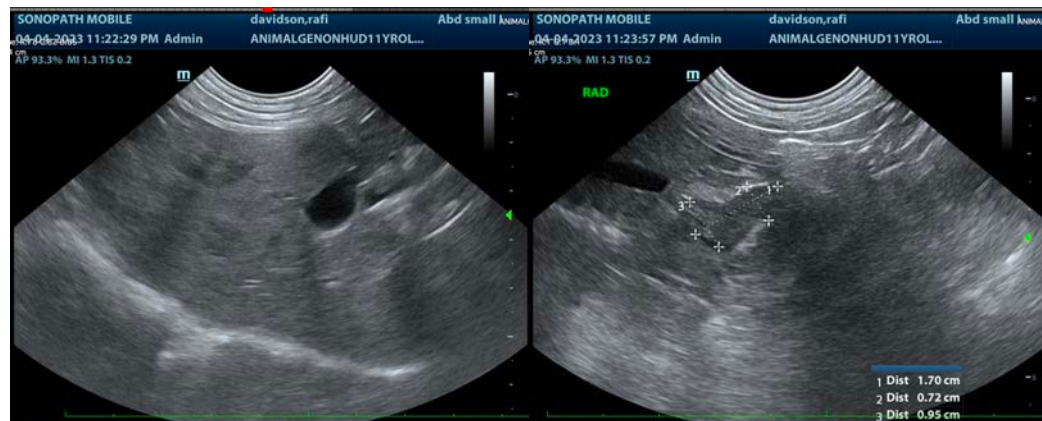
Beth Johnson, DVM
DACVIM

INTERPRETATION OF THE FINDINGS & FURTHER RECOMMENDATIONS

Given this patient's reported benign fine needle aspirate results, follow up recommendations at this time include monitoring. Recheck imaging should be considered if liver enzymes continue to increase and/or clinical signs develop. Ultimately, if this happens, a liver biopsy may be warranted.

IMAGING PERFORMED BY

Kelly Vazquez



HOSPITAL NAME

Animal General
on the Hudson

REFERRING VET

Dr. Karen Zelinski

INVOICE

46431

DATE

4/5/23



PATIENT

Rafi Davidson

SPECIES

Canine

BREED

Yorkshire Terrier

SEX

Neutered Male

AGE

11 Years

WEIGHT

16.8 Pounds

INTERPRETED BY

Beth Johnson, DVM
DACVIM

IMAGING PERFORMED BY

Kelly Vazquez

HOSPITAL NAME

Animal General
on the Hudson

REFERRING VET

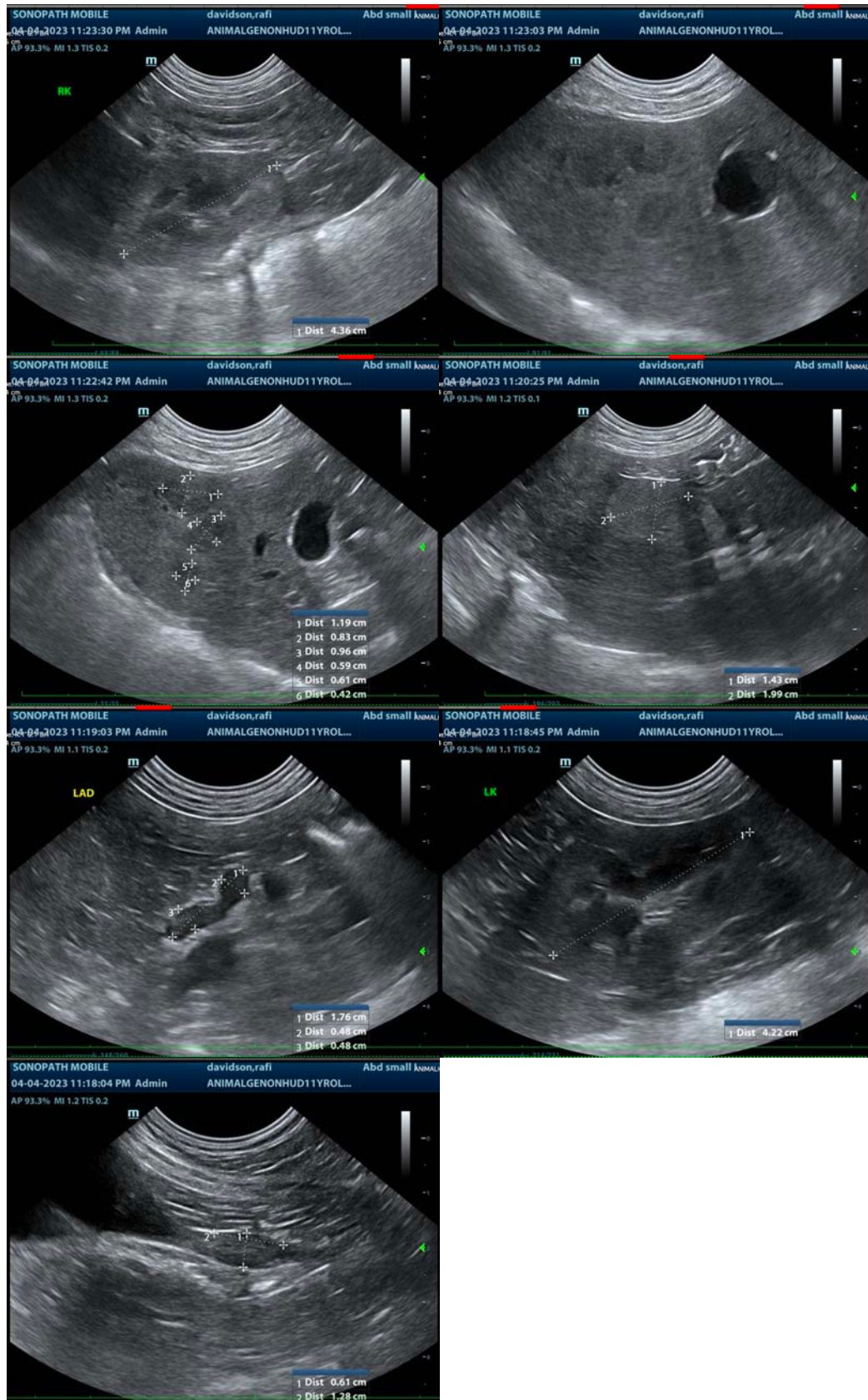
Dr. Karen Zelinski

INVOICE

46431

DATE

4/5/23





PATIENT

Rafi Davidson

SPECIES

Canine

BREED

Yorkshire Terrier

SEX

Neutered Male

AGE

11 Years

WEIGHT

16.8 Pounds

INTERPRETED BY

Beth Johnson, DVM
DACVIM

**IMAGING
PERFORMED BY**

Kelly Vazquez

HOSPITAL NAME

Animal General
on the Hudson

REFERRING VET

Dr. Karen Zelinski

INVOICE

46431

DATE

4/5/23

The information and recommendations provided are based on the images presented by the referring veterinarian/sonographer. No evaluation can be communicated regarding pathology that was not visible in the image/video clips provided.

Thank you for this referral. If the clinical or image interpretation does not parallel your findings or if I can be of any further assistance please contact me.

Beth Johnson, DVM, DACVIM
Beth.Johnson@sonopath.com