

**DATE PRESENTING CLINICAL SIGNS**

4/4/23 Referral for AUS - vomiting, rads concerning for something in the stomach.

PATIENT

Homer Sanders

Current Medications: None listed.
 Date of Previous IntraPet Ultrasound: No previous.
 Sedation: Not required to complete full diagnostic ultrasound.
 Stat Report: Not requested.
 Imaging Performed By: Rachel Brillhart, RDMS.

SPECIES

Feline

ULTRASONOGRAPHIC EXAMINATION OF THE ABDOMEN**BREED**

DLH

Urinary System

The urinary bladder is moderately distended with anechoic contents. No masses, inflammatory changes, echogenic sediment or cystoliths are observed. The urinary bladder, trigone and visible pelvic urethra are normal in thickness with a smooth mucosal surface.

SEX

Neutered Male

The right kidney is normal in size (4.22 cm), shape and echogenicity. It has smooth peripheral margination. There is a normal 1:3 cortex to medulla ratio with appropriate corticomedullary distinction. There is no evidence of pyelectasia, mineral or infarcts observed.

AGE

4/3/15

The left kidney is normal in size (3.93 cm), shape and echogenicity. It has smooth peripheral margination. There is a normal 1:3 cortex to medulla ratio with appropriate corticomedullary distinction. There is no evidence of pyelectasia, mineral or infarcts observed.

WEIGHT

15 Pounds

Adrenal Glands

The right adrenal gland is normal in size (0.52 cm), shape and contour. Corticomedullary structure is unremarkable. Visible surrounding vasculature appears normal.

INTERPRETED BYBeth Johnson, DVM
DACVIM

The left adrenal gland is normal in size (0.33 cm), shape and contour. Corticomedullary structure is unremarkable. Visible surrounding vasculature appears normal.

Spleen

The spleen is subjectively normal in size with a normal smooth capsular contour. Parenchyma is appropriately finely textured and homogenous with normal echogenicity relative to surrounding tissue (hyperechoic to liver). No focal nodules or masses are observed. Splenic vasculature appears normal.

HOSPITAL NAMEAnimal Emergency
Hospital**Liver**

The liver is subjectively normal in size with normal smooth curvilinear peripheral contour. Parenchyma is appropriately hypoechoic to the spleen in echogenicity and appropriately mildly coarse and homogenous in echotexture. No focal lesions are observed. Visible vasculature and biliary tree appear normal without distension or congestion.

REFERRING VET

Dr. Nacke-Horney

INVOICE

46382

The gallbladder is non-distended in size. The wall is smooth without visible thickening. Luminal contents are primarily anechoic. There is no evidence of cystic or common bile duct dilation.

Gastrointestinal

The stomach wall has a focal thickening along the lesser curvature approaching the pylorus that is approximately 5.0 cm long and 2.2 cm thick with an overall heterogeneous hypoechoic appearance and complete loss of mural detail. The lumen of the stomach is mildly distended with echogenic non-shadowing luminal contents and gas consistent with normal ingesta. There is no evidence of obstruction, foreign material or infiltrative disease.

The visible small intestines are normal in wall thickness and layering (canine duodenum < 0.5 cm and feline duodenum < 0.4 cm; other < 0.3 cm). Small intestinal motility appears adequate (1-3 contractions per min). The lumen of the small intestine is empty with no evidence of obstruction, foreign material or infiltrative disease.

The visible colon is normal in wall thickness (< 0.2 cm) and layering. Contents are consistent with normal formed feces and gas.

Pancreas

The pancreatic parenchyma is appropriately isoechoic to surrounding tissue. Visible capsule is smooth and normal in contour. There is no visible pancreatic duct dilation. There is no evidence of active peripancreatic inflammation.

Free Abdomen

There is no evidence of free peritoneal effusion noted in these images.

Gastric lymphadenopathy is present adjacent to the mass described above.

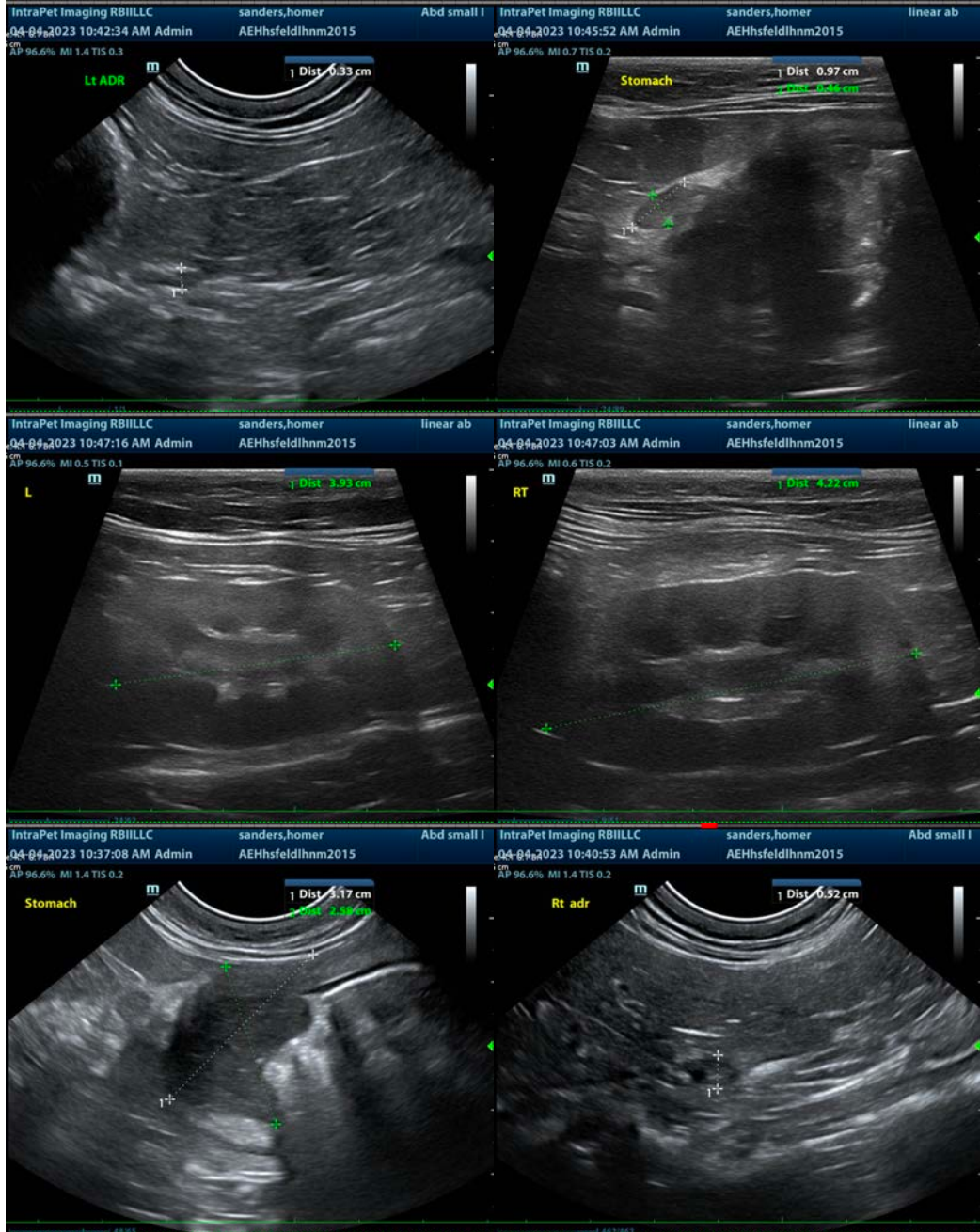
ULTRASONOGRAPHIC FINDINGS

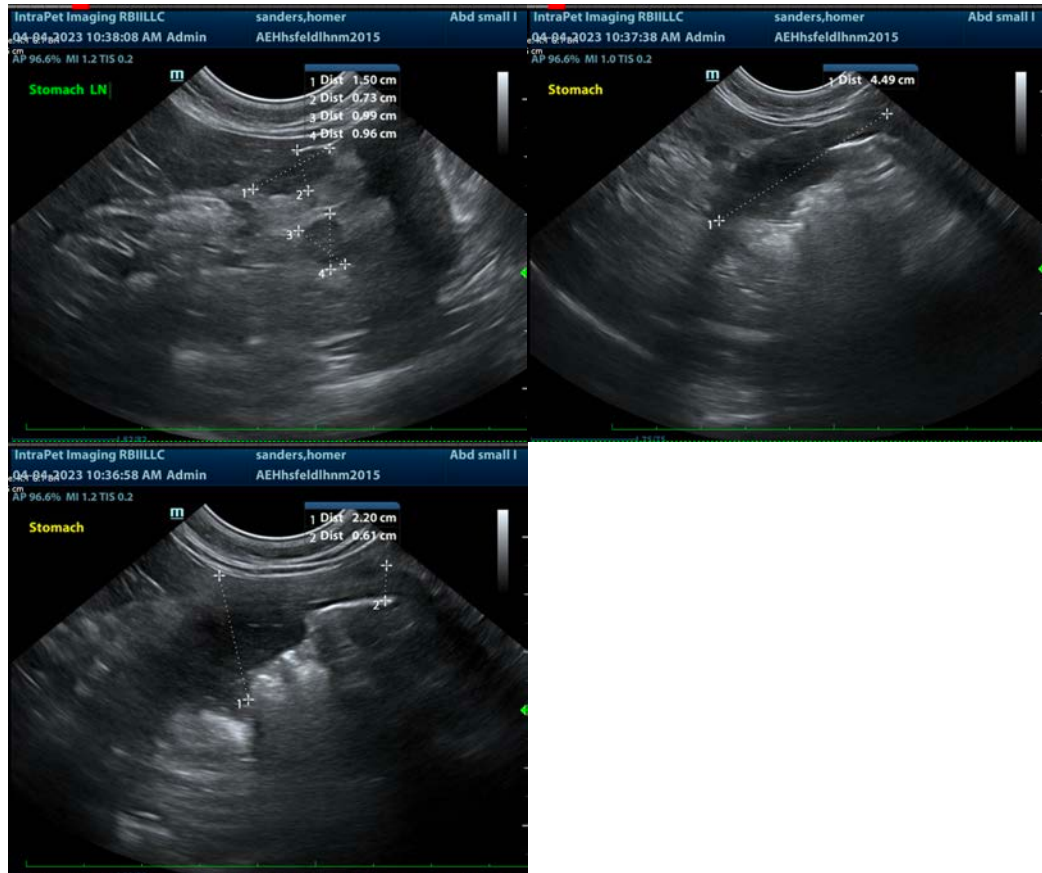
- Gastric mass – This appears to be at least partially obstructive, given the mild distention and gastric contents present in these images. Differentials include primarily infiltrative neoplasia such as round cell neoplasia (i.e., lymphoma). A benign inflammatory process is possible but considered much less likely.
- Surrounding lymphadenopathy – This may be reactive lymphadenopathy. However, infiltrative neoplasia is also possible (i.e., lymphoma) and cannot be differentiated without tissue sampling.

INTERPRETATION OF THE FINDINGS & FURTHER RECOMMENDATIONS

Three view thoracic radiographs are recommended for further assessment of cardio-pulmonary status as well as to further evaluate for any evidence of metastatic disease, if not recently evaluated.

A fine needle aspirate of the gastric mass is recommended if patient's coagulation status is appropriate. Alternatively, and/or if a diagnosis cannot be made cytologically, upper GI gastroscopy for further visualization and biopsies could be considered, or an exploratory laparotomy for excisional biopsy could be planned. The mass is focal in nature and may be fully resectable. However, given the proximity to the pylorus, full resectability is questionable. Therefore, trying to obtain a diagnosis ahead of time, as recommended above, is advised.





The information and recommendations provided are based on the images presented by the referring veterinarian/sonographer. No evaluation can be communicated regarding pathology that was not visible in the image/video clips provided.

Thank you for this referral. If the clinical or image interpretation does not parallel your findings or if I can be of any further assistance please contact me.

Beth Johnson, DVM, DACVIM
Beth.Johnson@sonopath.com