

**DATE PRESENTING CLINICAL SIGNS**

4/3/23

Presented for wellness exam. New patient. History of intermittent vomiting and diarrhea every 2-3 months. She is drinking and urinating a lot. History of joint disease, djd. BCS 3.5/9 MM pale pink. Decreased muscle mass. Enlarged carpal and elbow joints.

PATIENT

Jada Toretti

Current Medications: None listed.

Lab Results: HCT 25%, ALT 388, SDMA 17.7, ALB 2.8, GLOB 2.6, Retics 5.2%, Retics 176800, Hypochromacia, Polychromacia. Urine SG 1.015 prot 2+ amorphous urates

Date of Previous IntraPet Ultrasound: No previous.

SPECIES

Canine

Sedation: Not required to complete full diagnostic ultrasound.

BREED

Pitbull

Stat Report: Not requested.

Imaging Performed By: Rachel Brillhart, RDMS.

ULTRASONOGRAPHIC EXAMINATION OF THE ABDOMEN**SEX**

Spayed Female

Urinary System

Urinary bladder is adequately distended with anechoic contents. No masses, inflammatory changes, echogenic sediment or cystoliths are observed. The urinary bladder, trigone and visible pelvic urethra are normal in thickness with a smooth mucosal surface.

AGE

11/24/2009

Kidneys are overall normal in size and shape with smooth peripheral margination. A normal 1:3 cortex to medulla ratio is maintained. The medulla and cortices are uniform in texture with some mild increased cortical echogenicity and mild loss of corticomedullary distinction, expected in this age patient. There is no evidence of mineral or infarcts observed. The left kidney measures 7.34 cm. The right kidney measures 6.46 cm. Pyelectasia was noted bilaterally. Left kidney pyelectasia measured 0.24 cm in the sagittal view. Right kidney pyelectasia measured 0.69 cm in the sagittal view.

WEIGHT

46.4 Pounds

INTERPRETED BY

Beth Johnson, DVM
DACVIM

Adrenal Glands

Adrenal glands are small (flattened contour). Corticomedullary structure is unremarkable. Visible surrounding vasculature appears normal. The left adrenal gland measured 2.79 cm long x 0.65 cm at cranial pole and 0.65 cm at caudal pole. The right adrenal gland measured 3.36 cm long x 0.69 cm at cranial pole and 0.75 cm at caudal pole.

HOSPITAL NAME

Jacksonville VH

Spleen

Spleen is subjectively normal in size with a normal smooth capsular contour. Parenchyma is appropriately finely textured and homogenous with normal echogenicity relative to surrounding tissue (hyperechoic to liver). Splenic vasculature appears normal. A 1.4 cm x 1.1 cm hypo- to anechoic non-capsule-disrupting nodule was noted in the mid body, as well as multifocal, well demarcated hyperechoic homogenous nodules throughout the parenchyma.

REFERRING VET

Dr. Burk

Liver

Liver is subjectively enlarged with mildly irregular margins. Parenchyma is heterogenous characterized by multiple poorly defined hypoechoic nodules within otherwise hyperechoic liver parenchyma. Additionally, there are multifocal 1-2 cm in diameter hyperechoic nodules noted. Visible vasculature and biliary tree appear normal without distension or congestion.

INVOICE

21841

Gallbladder is moderately distended with anechoic bile as well as mild suspended and gravity dependent echogenic debris. The wall is smooth without visible thickening. There is no evidence of cystic or CBD dilation. There is no evidence of effusion or inflammation.

Gastrointestinal

The visible stomach wall is normal in thickness and layering. The lumen of the stomach is mildly distended with very echogenic reverberation artifact from intraluminal gas. There is no evidence of obstruction, foreign material or infiltrative disease; however, complete visualization of far wall is partially inhibited by gas. Pyloric outflow tract appears patent.

The visible small intestines are normal in wall thickness and layering. Small intestinal motility appears adequate (1-3 contractions per min). The lumen of the small intestine is empty with no evidence of obstruction, foreign material or infiltrative disease.

The visible colon is normal in wall thickness and layering. Contents are consistent with normal formed feces and gas.

Pancreas

The observed pancreas appears appropriately isoechoic to surrounding omental fat. Visible capsule is smooth and normal in contour. Visible pancreatic parenchyma is homogenous and unremarkable. There is no visible pancreatic duct dilation. There is no evidence of active peripancreatic inflammation.

Free Abdomen

There is no evidence of peritoneal effusion. There is no apparent lymphadenopathy.

Other

There is no evidence of heart base or pericardial pathology noted in these images at this time. If cardiac function evaluation is desired a full echocardiogram is recommended.

ULTRASONOGRAPHIC FINDINGS

Primary Findings

- Flat adrenal glands – This can be a normal patient variant and/or a sign of exogenous cortisol administration. If exogenous steroids are not being administered, hypoadrenocorticism (either relative or absolute) should be considered.
- Heterogenous liver with liver nodules– These changes are most consistent with benign processes such as nodular hyperplasia, steroid (vacuolar) hepatopathy, extramedullary hematopoiesis or possibly chronic inflammatory disease and less commonly infiltrative round cell or metastatic neoplasia. Differentials for the discrete liver nodules include primarily benign changes such as nodular hyperplasia, fibrosis of an old hematoma, granulomas, myelolipomas, etc.; however, while considered less likely, primary hepatic neoplasia, infiltrative round cell neoplasia and metastatic disease can mimic benign lesions and cannot be definitively ruled out.
- Hypo to anechoic splenic nodule with hyperechoic splenic nodules– The hypo- to anechoic splenic nodule likely represents a benign lesion such as a cyst, hematoma, nodular hyperplasia, extramedullary hematopoiesis, etc., however while considered less likely, infiltrative neoplasia can mimic benign lesions, and cannot be ruled out. The hyperechoic splenic nodules are most consistent with benign myelolipomas. Other differentials such as fibrosis or calcification caused by old hematomas or infarcts, chronic inflammation, granulomatous disease or metastatic disease cannot be ruled out, but are considered less likely.

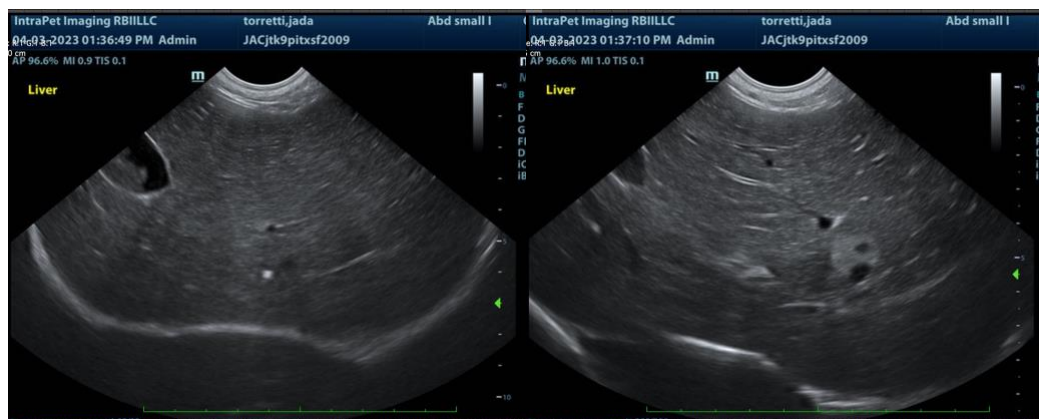
Secondary Findings

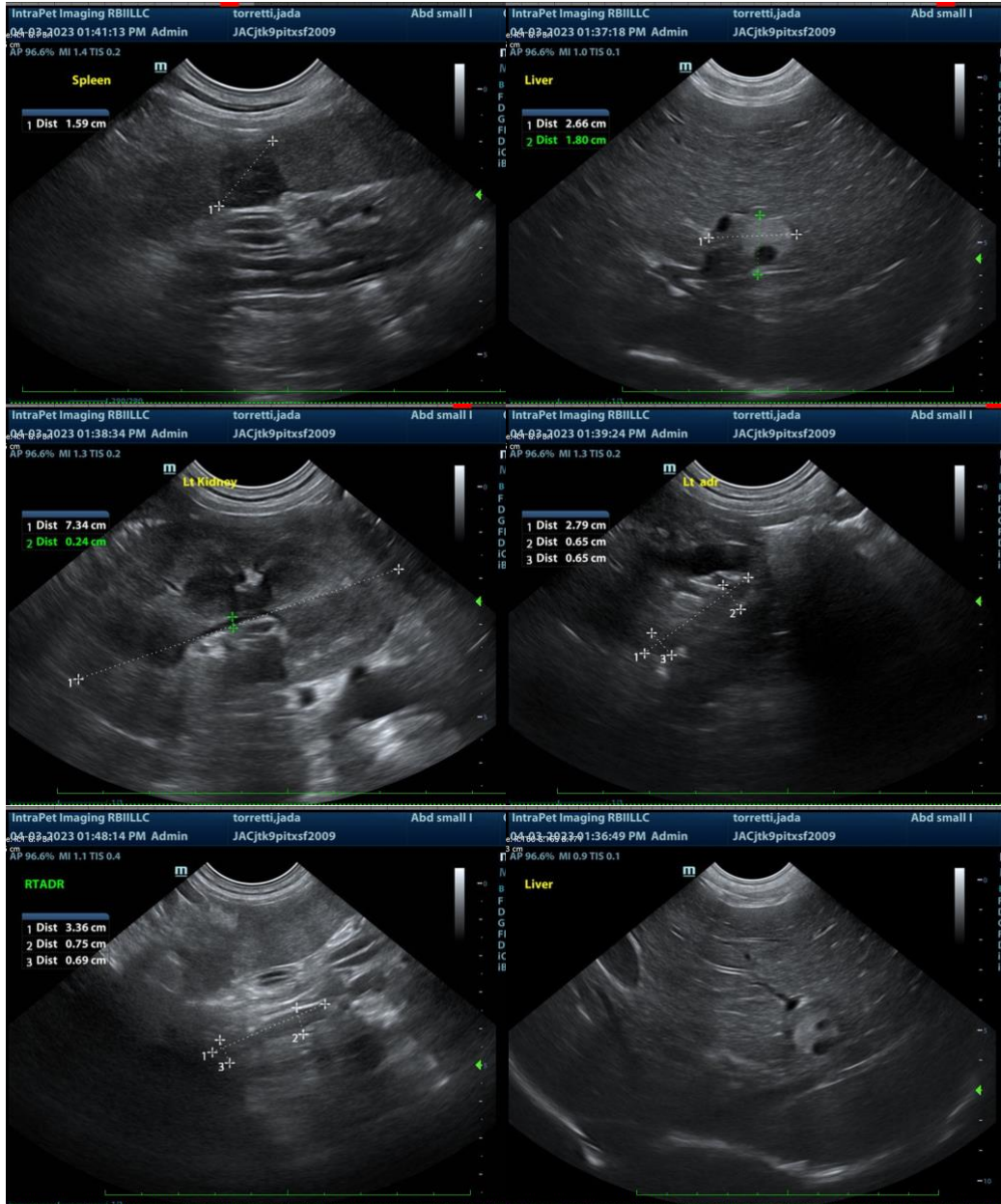
- Age-related kidney changes with bilateral pyelectasia- Differentials for pyelectasia include pyelonephritis, diuresis, congenital malformation or ureteral or lower urinary tract obstruction.
- Gallbladder debris - Cholecystic debris is of unknown clinical significance. It can be seen with biliary stasis from fasting or illness. Cholecystic debris is not necessarily related to hepatobiliary disease. Echogenic bile is most commonly an incidental finding in dogs and should be interpreted in combination with clinical signs such as nausea, inappetence, cranial abdominal discomfort and/or laboratory changes such as increased ALP and/or increased Tbili.

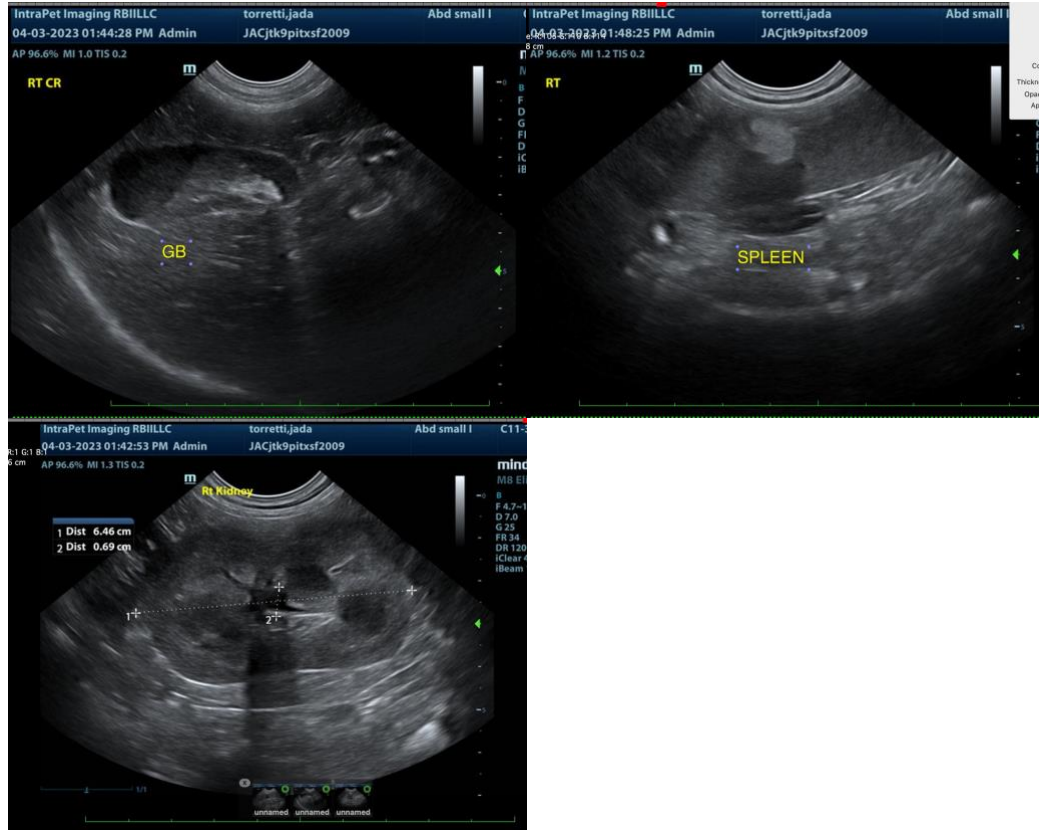
INTERPRETATION OF THE FINDINGS & FURTHER RECOMMENDATIONS

The appearance of the stomach and liver changes described above trend in appearance toward benign, however, infiltrative neoplasia cannot be definitively ruled out without tissue sampling. Therefore, fine needle aspirates of both organs could be considered if patients coagulation status is appropriate. Given this patients reported anemia, hypoproteinemia, and chronic intermittent gastrointestinal signs, however, other further diagnostic recommendations include:

- A baseline cortisol. If baseline cortisol is less than 2, a full ACTH stimulation test is recommended to rule out hypoadrenocorticism.
- A gastrointestinal malabsorption panel (including cobalamin, folate, TLI and PLI) to Texas A&M GI Laboratory, for further evaluation of GI and pancreatic function.
- A urine protein to creatinine ratio, to further quantify the reported proteinuria.
- Additionally, testing for Leptospirosis, given the mildly increased ALT, and reported PU/PD, etc., should be considered.







The information and recommendations provided are based on the images presented by the referring veterinarian. No evaluation can be communicated regarding pathology that was not visible in the image/video clips provided.

Thank you for this referral. If the clinical or image interpretation does not parallel your findings or if I can be of any further assistance please contact me.

Beth Johnson, DVM DACVIM
Beth.Johnson@SonoPath.com