



PATIENT PRESENTING CLINICAL SIGNS

PATIENT Bugsy Robbins
 Very tender abdomen. Lethargic. Large mass found in caudal abdomen on rads today.

SPECIES Canine
 Current Medications: comfortan, cerenia.

BREED Pug
 Abnormal PE/Chem/CBC/UA Results: Chemistries all NAF CBC - neutrophilia and monocytosis
 Primary Question to Be Answered in This Exam Where is the mass originating from Can you do an FNA to help diagnose this (may not be advised if this is splenic in origin) any other areas of concern causing such severe pain/tenderness.

SEX ULTRASONOGRAPHIC EXAMINATION OF THE ABDOMEN

MN *Urinary System*

AGE 9 year
 Urinary bladder is adequately distended. It has a normal uniform wall thickness. Contents include primarily anechoic fluid with a moderate to large of echogenic non-shadowing debris, most consistent with exfoliated cells, mucous and/or small blood clots. Both sterile inflammation as well as urinary tract infection can present with echogenic debris. No masses or cystoliths are observed. The trigone and visible pelvic urethra are normal in thickness with a smooth mucosal surface.

WEIGHT 8.8 kg
 Prostate is normal in size, echotexture, and echogenicity for a neutered male.

INTERPRETED BY Beth Johnson, DVM DACVIM
 The right kidney is normal is size (4.12 cm), shape and echogenicity. It has smooth peripheral margination. There is a normal 1:3 cortex to medulla ratio with appropriate corticomedullary distinction. A hyperechoic band parallel to the corticomedullary border is present. There is no evidence of pyelectasia, mineral or infarcts observed.

The left kidney is normal is size (4.28 cm), shape and echogenicity. It has smooth peripheral margination. There is a normal 1:3 cortex to medulla ratio with appropriate corticomedullary distinction. A hyperechoic band parallel to the corticomedullary border is present. There is no evidence of pyelectasia, mineral or infarcts observed.

IMAGING PERFORMED BY Amanda Stewart
Adrenal Glands

HOSPITAL NAME Snelgrove VS
 The right adrenal gland is unable to be well visualized in these images.

The left adrenal gland is normal in size (0.56 cm at cranial pole and 0.84 cm at caudal pole), shape and overall architecture, echogenicity and echotexture. Visible surrounding vasculature appears normal.

REFERRING VET Dr. Scorgie
Spleen

The spleen is subjectively normal in size with a normal smooth capsular contour. Parenchyma is appropriately finely textured and homogenous with normal echogenicity relative to surrounding tissue (hyperechoic to liver). No focal nodules or masses are observed. Splenic vasculature appears normal.

INVOICE 11819
Liver

DATE 4/29/2026
 The liver is subjectively normal in size with normal smooth curvilinear peripheral contour. Parenchyma is appropriately hypoechoic to the spleen in echogenicity and appropriately mildly coarse and homogenous in echotexture. No focal lesions are observed. Visible vasculature and biliary tree appear normal without distension or congestion.



PATIENT

Bugsy Robbins

The gallbladder is non-distended in size. The wall is smooth without visible thickening. Luminal contents are primarily anechoic. There is no evidence of cystic or common bile duct dilation.

SPECIES

Canine

Gastrointestinal

The visible stomach wall is normal in thickness and layering. The lumen of the stomach is empty with no evidence of obstruction, foreign material or infiltrative disease. Pyloric outflow tract appears patent.

BREED

Pug

The visible small intestines are normal in wall thickness and layering. Small intestinal motility appears adequate (1-3 contractions per min). The lumen of the small intestine is empty with no evidence of obstruction, foreign material or infiltrative disease.

SEX

MN

The visible colon is normal in wall thickness (< 0.2 cm) and layering. Contents are consistent with normal formed feces and gas. *See Free Abdomen*

AGE

9 year

Pancreas

The pancreas that is observed appears appropriately isoechoic to surrounding omental fat. Visible capsule is smooth and normal in contour. Visible pancreatic parenchyma is homogenous and unremarkable. There is no visible pancreatic duct dilation. There is no evidence of active peripancreatic inflammation.

WEIGHT

8.8 kg

Free Abdomen

INTERPRETED BY

Beth Johnson, DVM
 DACVIM

There is a trace amount of anechoic free fluid.

There is no apparent pathologic lymphadenopathy noted in these images.

In the right mid to caudal abdomen, is an approximately 4.5 cm x 5.8 cm irregular, coarse, hypoechoic mass that appears to be a bowel mass, and given location, ileocecal colic junction can't be ruled out.

IMAGING PERFORMED BY

Amanda Stewart

PRIMARY FINDINGS

- Suspect bowel, possibly ileocecal colic junction mass. Although, definitive origination is difficult to fully say, and while bowel is the top differential, other differentials include lymph node, free abdomen, etc.
- Mild free fluid is of unknown origin. Differentials (unless already ruled out) could include increased hydrostatic pressure (cardiac disease and/or vascular or lymph blockage), decreased oncotic pressure (low albumin), vasculitis, paraneoplastic fluid, rupture/leakage of/from an organ (GI, GB, UB, other), blood (hemoabdomen), other.

HOSPITAL NAME

Snelgrove VS

REFERRING VET

Dr. Scorgie

SECONDARY FINDINGS

INVOICE

11819

DATE

4/29/2026

- Bilateral medullary rim sign - This finding is of unknown clinical significance and can be a normal variant, often idiopathic. Medullary rim sign can be present with renal disease including lymphoma, hypercalcemic nephropathy, Leptospirosis, tubular disease, other and should be interpreted in combination with other more specific indications of kidney disease such as isosthenuria, proteinuria, azotemia, etc. This is a common incidental finding in patients with diabetes mellitus.
- A moderate to large amount of echogenic urinary bladder debris.



PATIENT

Bugsy Robbins

SPECIES

Canine

BREED

Pug

SEX

MIN

AGE

9 year

WEIGHT

8.8 kg

INTERPRETED BY

Beth Johnson, DVM
 DACVIM

IMAGING PERFORMED BY

Amanda Stewart

HOSPITAL NAME

Snelgrove VS

REFERRING VET

Dr. Scorgie

INVOICE

11819

DATE

4/29/2026

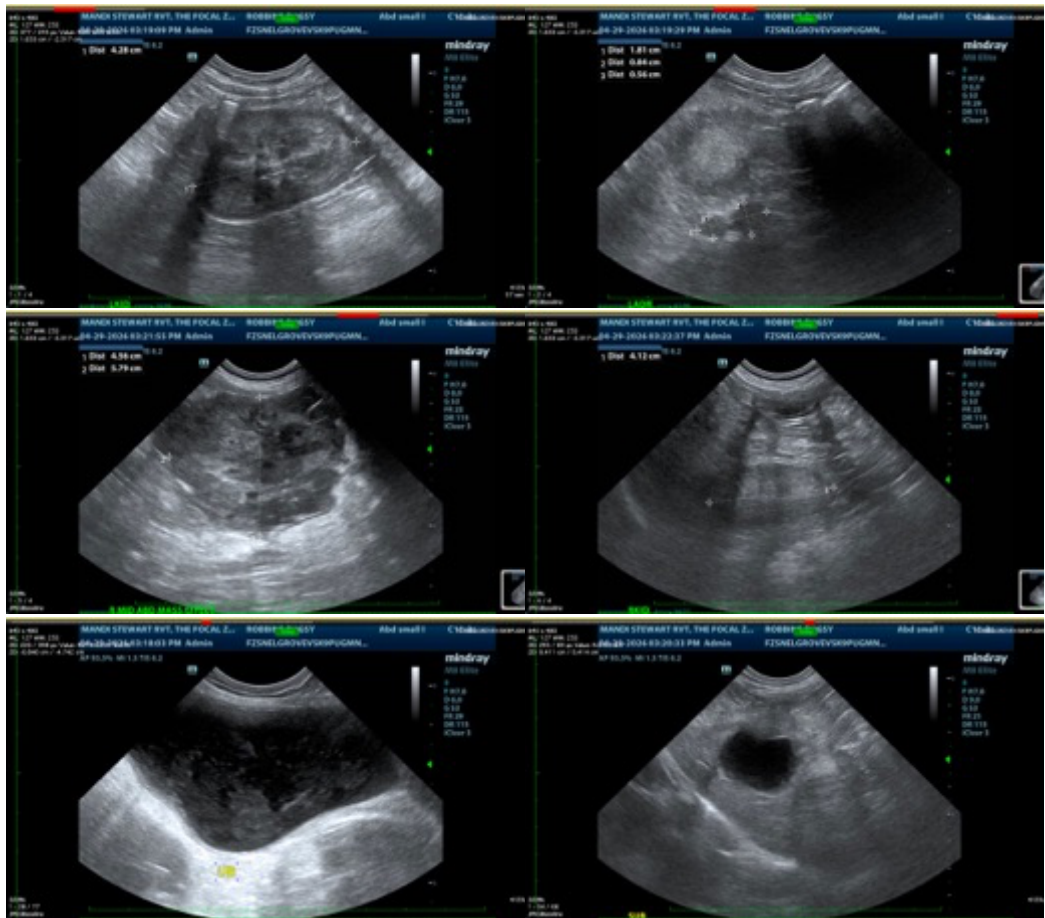
INTERPRETATION OF THE FINDINGS & FURTHER RECOMMENDATIONS

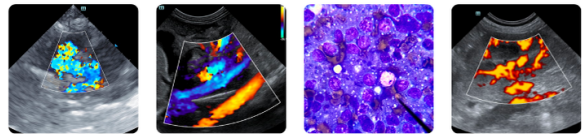
Urinalysis and, if indicated based on urinalysis results, urine culture is recommended. If protein is present in an otherwise quiet sediment, protein quantification with a urine protein to creatinine ration is recommended.

Three view thoracic radiographs are recommended for further assessment of cardio-pulmonary status as well as to further evaluate for any evidence of metastatic disease, if not recently evaluated.

Fine needle aspirates of the mass are recommended if patient's coagulation status is appropriate.

Alternatively, or if a cytologic diagnosis is unable to be obtained, however, an exploratory laparotomy for planned resection and anastomosis, and histopathology could be considered. If surgery is pursued, given the possible difficult location, consultation with a veterinary surgeon is recommended.





PATIENT

Bugsy Robbins

SPECIES

Canine

BREED

Pug

SEX

MN

AGE

9 year

WEIGHT

8.8 kg

INTERPRETED BY

Beth Johnson, DVM
DACVIM

IMAGING PERFORMED BY

Amanda Stewart

HOSPITAL NAME

Snelgrove VS

REFERRING VET

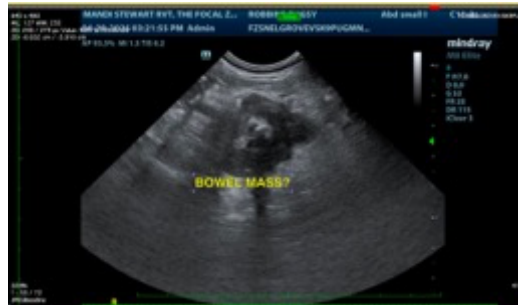Dr. Scorgie

INVOICE

11819

DATE

4/29/2026



The information and recommendations provided are based on the images presented by the referring veterinarian/sonographer. No evaluation can be communicated regarding pathology that was not visible in the image/video clips provided.

Thank you for this referral. If the clinical or image interpretation does not parallel your findings or if I can be of any further assistance please contact me.

Beth Johnson, DVM, DACVIM
info@sonopath.com