



PATIENT

Blue Jimenez

SPECIES

Canine

BREED

Yorkshire Terrier x

SEX

Neutered Male

AGE

7 Years 6 Months

WEIGHT

4.5 kg

INTERPRETED BY

Beth Johnson, DVM
DACVIM

IMAGING PERFORMED BY

Vincent Ravancho, CVT

HOSPITAL NAME

Bond Vet Union

REFERRING VET

Dr. Hinds

INVOICE

74803

DATE

4/29/26

PRESENTING CLINICAL SIGNS

Chronic V/D. Intermittent D+ roughly every other week. Ongoing since Feb 2026
Abnormal PE/Chem/CBC/UA Results: BW WNL 2/19/26, Cortisol WNL 3/7/26, Neg fecal 3/7/26

ULTRASONOGRAPHIC EXAMINATION OF THE ABDOMEN

Urinary System

The urinary bladder is adequately distended with anechoic contents. No masses, inflammatory changes, echogenic sediment or cystoliths are observed. The urinary bladder, trigone and visible pelvic urethra are normal in thickness with a smooth mucosal surface.

Prostate is normal in size, echotexture and echogenicity for a neutered male.

The right kidney is normal is size (3.73 cm), shape and echogenicity. It has smooth peripheral margination. There is a normal 1:3 cortex to medulla ratio with appropriate corticomedullary distinction. There is no evidence of pyelectasia, mineral or infarcts observed. A hyperechoic band parallel to the corticomedullary border is present.

The left kidney is normal is size (3.77 cm), shape and echogenicity. It has smooth peripheral margination. There is a normal 1:3 cortex to medulla ratio with appropriate corticomedullary distinction. There is no evidence of pyelectasia, mineral or infarcts observed. A hyperechoic band parallel to the corticomedullary border is present.

Adrenal Glands

The right adrenal gland is normal in size (0.80 cm at cranial pole and 0.50 cm at caudal pole), shape and overall architecture, echogenicity and echotexture. Visible surrounding vasculature appears normal.

The left adrenal gland is unable to be well visualized in these images.

Spleen

The spleen is subjectively normal in size with a normal smooth capsular contour. Parenchyma is appropriately finely textured and homogenous with normal echogenicity relative to surrounding tissue (hyperechoic to liver). No focal nodules or masses are observed. Splenic vasculature appears normal.

Liver

The liver is subjectively normal in size with normal smooth curvilinear peripheral contour. Parenchyma is appropriately hypoechoic to the spleen in echogenicity and appropriately mildly coarse and homogenous in echotexture. No focal lesions are observed. Visible vasculature and biliary tree appear normal without distension or congestion.

The gallbladder is non-distended in size. The wall is smooth without visible thickening. Luminal contents are primarily anechoic. There is no evidence of cystic or common bile duct dilation.

Gastrointestinal

The visible stomach wall is normal in thickness and layering. The lumen of the stomach is mildly distended with very echogenic reverberation artifact from intraluminal gas. There is no evidence of obstruction, foreign material, or infiltrative disease; however, visualization is partially inhibited by gas.



PATIENT

Blue Jimenez

The visible small intestines are normal in wall thickness and layering. Small intestinal motility appears adequate (1-3 contractions per min). The lumen is mildly distended with echogenic non-shadowing luminal contents and gas consistent with normal ingesta/chyme. There is no evidence of obstruction, foreign material or infiltrative disease.

SPECIES

Canine

The visible colon is normal in wall thickness (< 0.2 cm) and layering. Contents are consistent with normal formed feces and gas.

BREED

Yorkshire Terrier x

Pancreas

The pancreas that is observed appears appropriately isoechoic to surrounding omental fat. Visible capsule is smooth and normal in contour. Visible pancreatic parenchyma is homogenous and unremarkable. There is no visible pancreatic duct dilation. There is no evidence of active peripancreatic inflammation.

SEX

Neutered Male

Free Abdomen

There is no visible free peritoneal effusion noted in these images.

AGE

7 Years 6 Months

There is no apparent pathologic lymphadenopathy noted in these images.

WEIGHT

4.5 kg

ULTRASONOGRAPHIC FINDINGS

- Subtle bilateral medullary rim sign - This finding is of unknown clinical significance and can be a normal variant, often idiopathic. Medullary rim sign can be present with renal disease including lymphoma, hypercalcemic nephropathy, Leptospirosis, tubular disease, other and should be interpreted in combination with other more specific indications of kidney disease such as isosthenuria, proteinuria, azotemia, etc. This is a common incidental finding in patients with diabetes mellitus.
- Otherwise, this is a largely unremarkable/structurally normal abdomen without a definitive ultrasonographically visible intraabdominal explanation for patient's reported gastrointestinal signs.

INTERPRETED BY

Beth Johnson, DVM
DACVIM

IMAGING PERFORMED BY

Vincent Ravancho, CVT

INTERPRETATION OF THE FINDINGS & FURTHER RECOMMENDATIONS

HOSPITAL NAME

Bond Vet Union

Given the reported workup so far, next diagnostic recommendations include:

A gastrointestinal malabsorption panel (including cobalamin, folate, TLI and PLI) to Texas A&M GI Laboratory is recommended for further evaluation of GI and pancreatic function.

REFERRING VET

Dr. Hinds

A fecal enteropathogen PCR panel to Texas A&M GI Laboratory could be considered for further evaluation of possible infectious disease. Contact lab for recommendations on how long to discontinue antibiotics (if indicated) prior to obtaining a stool sample for submission.

INVOICE

74803

Supportive/symptomatic medical management of clinical signs is recommended, including anti-emetics, gastroprotectants (+/- sucralfate, especially with any history of hematemesis), an appetite stimulant and fluid therapy if indicated, etc.

DATE

4/29/26

Additionally, empirical deworming with a 5-day course of Panacur is recommended.



PATIENT

A full course of empirical Helicobacter triple therapy could be considered.

Blue Jimenez

A probiotic, such as visbiome or proviable, may be helpful.

SPECIES

Canine

Finally, if tolerated, a transition in diet could be considered, based on trial-and-error response with some options to consider including a gastrointestinal biome diet vs a hydrolyzed protein diet (sometimes several trials with different brands are necessary) vs an easy to digest, bland or low-fat diet vs other.

BREED

Yorkshire Terrier x

Given the intermittent chronicity of the diarrhea, fecal microbe transplant therapy could also be considered.

SEX

Neutered Male

AGE

7 Years 6 Months

WEIGHT

4.5 kg

INTERPRETED BY

Beth Johnson, DVM
DACVIM

IMAGING PERFORMED BY

Vincent Ravancho, CVT

HOSPITAL NAME

Bond Vet Union

REFERRING VET

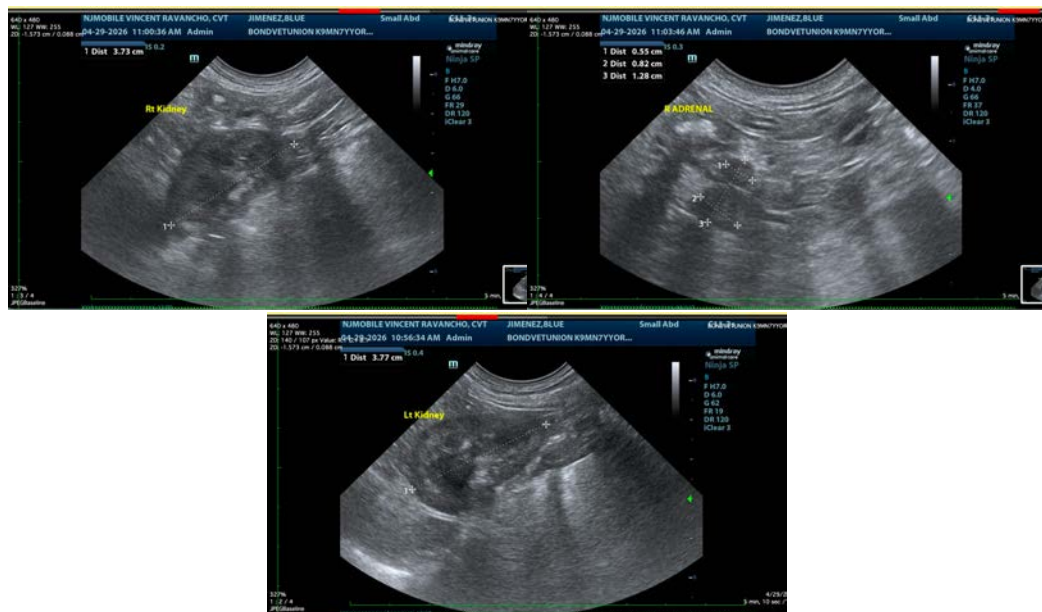
Dr. Hinds

INVOICE

74803

DATE

4/29/26



The information and recommendations provided are based on the images presented by the referring veterinarian/sonographer. No evaluation can be communicated regarding pathology that was not visible in the image/video clips provided.

Thank you for this referral. If the clinical or image interpretation does not parallel your findings or if I can be of any further assistance please contact me.

Beth Johnson, DVM, DACVIM
info@sonopath.com