



PATIENT PRESENTING CLINICAL SIGNS

Billy Knechtel No teeth (extracted October 2025). Heart murmur grade III systolic - diagnosed 1 year ago

SPECIES Abnormal PE/Chem/CBC/UA Results: ABNORMAL Labwork Values Inc ALP (487 U/L) first observed in June 2025, has continued to increase since regardless of addition of liver supplement. Radiographic Findings N/A Primary Question to Be Answered in This Exam Reason for elevated liver enzymes

Canine

BREED ULTRASONOGRAPHIC EXAMINATION OF THE ABDOMEN

Maltese Urinary System

SEX The urinary bladder is adequately distended with anechoic contents. No masses, inflammatory changes, echogenic sediment or cystoliths are observed. The urinary bladder, trigone and visible pelvic urethra are normal in thickness with a smooth mucosal surface.

Neutered Male

AGE Prostate is mildly enlarged (1.0 cm wide in the sagittal view). Parenchyma is diffusely homogenous and relatively hyperechoic. Normal distinct margins and symmetrical bilobed shape are maintained. This finding is likely normal patient variant, especially if patient was neutered as an adult; however, if patient was neutered as a puppy, prostatitis or, less likely, infiltrative neoplasia cannot be ruled out. This finding should be interpreted in combination with clinical signs, urinalysis results, etc. and either further investigated or monitored, as indicated.

WEIGHT

8.5 kg

Kidneys are overall normal in size and shape with smooth peripheral margination. A normal 1:3 cortex to medulla ratio is maintained. The medulla and cortices are uniform in texture with some mild increased cortical echogenicity and mild loss of corticomedullary distinction, expected in this age patient. There is no evidence of pyelectasia, mineral or infarcts observed. Left kidney measures 4.5 cm. Right kidney measures 4.4 cm. A hyperechoic band parallel to the corticomedullary border is present in both kidneys.

INTERPRETED BY

Beth Johnson, DVM
 DACVIM

Adrenal Glands

IMAGING PERFORMED BY

Amanda Stewart

Adrenal glands are plump/swollen in size. Normal shape and contour are maintained without evidence of capsular invasion. Corticomedullary structure is unremarkable. Visible surrounding vasculature appears normal. The left adrenal gland is difficult to visualize due to a full colon in the area, but this provided interpretation is for what I believe is the left adrenal gland. Left measures 1.0 cm at the cranial pole and 1.1 cm at the caudal pole. Right measures 0.85 cm at the cranial pole and 0.55 cm at the caudal pole.

HOSPITAL NAME

New Hamburg VC

REFERRING VET Spleen

Dr. Bellion

The spleen is subjectively normal in size with a normal smooth capsular contour. Parenchyma is appropriately finely textured and homogenous with normal echogenicity relative to surrounding tissue (hyperechoic to liver). No focal nodules or masses are observed. Splenic vasculature appears normal.

INVOICE

74801

Liver

DATE

4/29/26

The liver is subjectively normal in size with normal smooth curvilinear peripheral contour. Parenchyma is appropriately hypoechoic to the spleen in echogenicity and appropriately mildly coarse and homogenous in echotexture. No focal lesions are observed. Visible vasculature and biliary tree appear normal without distension or congestion.



PATIENT

Billy Knechtel

Gallbladder is moderately distended with anechoic bile as well as suspended and gravity dependent echogenic debris. The wall is smooth without visible thickening. There is no evidence of cystic or CBD dilation. There is no evidence of effusion or inflammation.

SPECIES

Canine

Gastrointestinal

The visible stomach wall is normal in thickness and layering. The lumen of the stomach is empty with no evidence of obstruction, foreign material or infiltrative disease. Pyloric outflow tract appears patent.

BREED

Maltese

The visible small intestines are normal in wall thickness and layering. Small intestinal motility appears adequate (1-3 contractions per min). The lumen of the small intestine is empty with no evidence of obstruction, foreign material or infiltrative disease.

SEX

Neutered Male

The visible colon is normal in wall thickness (< 0.2 cm) and layering. Contents are consistent with normal formed feces and gas.

AGE

9 Years

Pancreas

The pancreas that is observed appears appropriately isoechoic to surrounding omental fat. Visible capsule is smooth and normal in contour. Visible pancreatic parenchyma is homogenous and unremarkable. There is no visible pancreatic duct dilation. There is no evidence of active peripancreatic inflammation.

WEIGHT

8.5 kg

Free Abdomen

INTERPRETED BY

Beth Johnson, DVM
 DACVIM

There is no visible free peritoneal effusion noted in these images.

There is no apparent pathologic lymphadenopathy noted in these images.

IMAGING PERFORMED BY

Amanda Stewart

PRIMARY FINDINGS

- Suspect mild bilateral adrenomegaly – In a patient diagnosed with hyperadrenocorticism, this finding is most consistent with adrenal hyperplasia secondary to pituitary dependent hyperadrenocorticism. This finding can also be seen with stress and/or normal patient variant. Interpret in combination with clinical signs of hyperadrenocorticism and/or other adrenal disease.
- Mild gallbladder debris - Cholecystic debris is of unknown clinical significance. It can be seen with biliary stasis from fasting or illness. Cholecystic debris is not necessarily related to hepatobiliary disease. Echogenic bile is most commonly an incidental finding in dogs and should be interpreted in combination with clinical signs such as nausea, inappetence, cranial abdominal discomfort and/or laboratory changes such as increased ALP and/or increased Tbili.

HOSPITAL NAME

New Hamburg VC

SECONDARY FINDINGS

- Mild age related kidney changes with bilateral medullary rim sign - This finding is of unknown clinical significance and can be a normal variant, often idiopathic. Medullary rim sign can be present with renal disease including lymphoma, hypercalcemic nephropathy, Leptospirosis, tubular disease, other and should be interpreted in combination with other more specific indications of kidney disease such as isosthenuria, proteinuria, azotemia, etc. This is a common incidental finding in patients with diabetes mellitus.
- Subjective prostatomegaly.

REFERRING VET

Dr. Bellion

INVOICE

74801

DATE

4/29/26



PATIENT

Billy Knechtel

SPECIES

Canine

BREED

Maltese

SEX

Neutered Male

AGE

9 Years

WEIGHT

8.5 kg

INTERPRETED BY

Beth Johnson, DVM
 DACVIM

IMAGING PERFORMED BY

Amanda Stewart

HOSPITAL NAME

New Hamburg VC

REFERRING VET

Dr. Bellion

INVOICE

74801

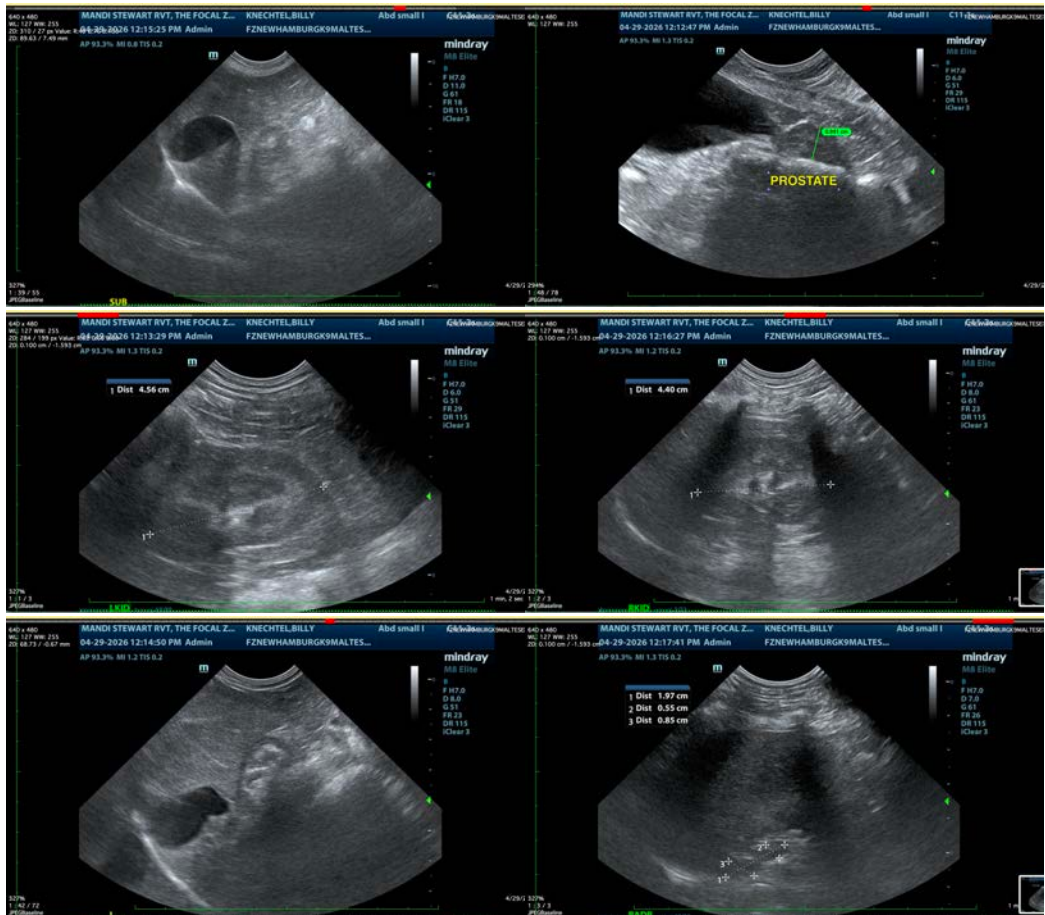
DATE

4/29/26

INTERPRETATION OF THE FINDINGS & FURTHER RECOMMENDATIONS

Differentials for a primary cholestatic liver enzyme pattern (increased ALP) are vast and non-specific. Differentials include, but are not limited to, benign nodular hyperplasia which occurs in 70% of older dogs and often does not result in an abnormal ultrasound, reactive or idiopathic/vacuolar hepatopathy, cholestasis and/or hyperadrenocorticism as well as many chronic non-hepatobiliary diseases such as chronic infections/inflammation from dental disease, IBD, neoplasia, hyperlipidemia, hypothyroidism, chronic pancreatitis, chronic stress, etc.

- Adrenocortical testing such as a low dose dexamethasone suppression test could be considered if clinical signs of hyperadrenocorticism are present.
- Given the gallbladder debris, empirical hepatic nutraceuticals including Ursodiol could be considered while monitoring for improvement.
- A fine needle aspirate of the liver could be considered if patient's coagulation status is appropriate.
- Otherwise, recommendations include addressing any other concurrent disease and monitoring. If values are progressive, recheck imaging is recommended.





PATIENT

Billy Knechtel

SPECIES

Canine

BREED

Maltese

SEX

Neutered Male

AGE

9 Years

WEIGHT

8.5 kg

INTERPRETED BY

Beth Johnson, DVM
DACVIM

IMAGING PERFORMED BY

Amanda Stewart

HOSPITAL NAME

New Hamburg VC

REFERRING VET

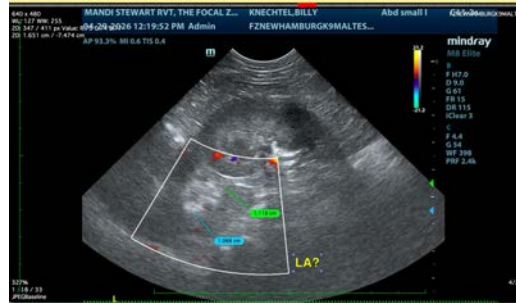Dr. Bellion

INVOICE

74801

DATE

4/29/26



The information and recommendations provided are based on the images presented by the referring veterinarian/sonographer. No evaluation can be communicated regarding pathology that was not visible in the image/video clips provided.

Thank you for this referral. If the clinical or image interpretation does not parallel your findings or if I can be of any further assistance please contact me.

Beth Johnson, DVM, DACVIM
info@sonopath.com