



PATIENT

Ruby Patterson

SPECIES

Canine

BREED

Smooth Fox Terrier

SEX

Spayed Female

AGE

9.4 Years

WEIGHT

16 lbs

INTERPRETED BY

Beth Johnson, DVM
DACVIM

IMAGING PERFORMED BY

Dr. Kristen Carpenter

HOSPITAL NAME

Pennridge Animal
Hospital

REFERRING VET

Dr. Jen Makem

INVOICE

74771

DATE

4/28/26

PRESENTING CLINICAL SIGNS

Hx: Patient was not sedated.

Patient presented for wellness exam and bloodwork showed low albumin and proteinuria. Patient has hx of a ligament injury LF and an oral growth that is scheduled to be removed in the next 2 weeks. Here for AUS to complete workup for suspected PLN. Current medications - Doxycycline x 1month for Anaplasma + (chronic but re-treatment elected to r/o tick borne disease), Benazepril 5 mg PO SID

Abnormal PE/Chem/CBC/UA Results: 3/31/26 Full Bloodwork: CBC WNL. Chem - Creat 0.9, Total protein 6.0, Albumin 2.3 (L), glob 3.7, Chol 408 (H). UA: USG 1.026, 4+ protein, quiet sediment. 4dx-Anaplasma + (chronic), fecal NOS, T4 WNL - 4/16/26 UPC - > 3.97 - 4/17/26 Total Protein Panel: Total protein 6.4, Albumin 2.4 (L), glob 4.0 - 4/22/26 CPL 57 (normal), resting cortisol 2.13 - 4/22/26 UPC - > 4.57 - 4/28/26 Blood Pressure 171, 174, 189 systolic

ULTRASONOGRAPHIC EXAMINATION OF THE ABDOMEN

Urinary System

The urinary bladder is adequately distended with anechoic contents. No masses, inflammatory changes, echogenic sediment or cystoliths are observed. The urinary bladder, trigone and visible pelvic urethra are normal in thickness with a smooth mucosal surface.

The right kidney is normal is size (4.76 cm), shape and echogenicity. It has smooth peripheral margination. There is a normal 1:3 cortex to medulla ratio with appropriate corticomedullary distinction. There is no evidence of pyelectasia, mineral or infarcts observed.

The left kidney is normal is size (4.61 cm), shape and echogenicity. It has smooth peripheral margination. There is a normal 1:3 cortex to medulla ratio with appropriate corticomedullary distinction. There is no evidence of pyelectasia, mineral or infarcts observed.

Adrenal Glands

The right adrenal gland is normal in size (0.80 cm at cranial pole and 0.79 cm at caudal pole), shape and overall architecture, echogenicity and echotexture. Visible surrounding vasculature appears normal.

The left adrenal gland is normal in size (0.62 cm at cranial pole and 0.47 cm at caudal pole), shape and overall architecture, echogenicity and echotexture. Visible surrounding vasculature appears normal.

Spleen

The spleen is subjectively normal in size with a normal smooth capsular contour. Parenchyma is appropriately finely textured and homogenous with normal echogenicity relative to surrounding tissue (hyperechoic to liver). No focal nodules or masses are observed. Splenic vasculature appears normal.

Liver

The liver is subjectively normal in size with normal smooth curvilinear peripheral contour. Parenchyma is appropriately hypoechoic to the spleen in echogenicity and appropriately mildly coarse and homogenous in echotexture. No focal lesions are observed. Visible vasculature and biliary tree appear normal without distension or congestion.



PATIENT

Ruby Patterson

SPECIES

Canine

BREED

Smooth Fox Terrier

SEX

Spayed Female

AGE

9.4 Years

WEIGHT

16 lbs

INTERPRETED BY

Beth Johnson, DVM
DACVIM

IMAGING PERFORMED BY

Dr. Kristen Carpenter

HOSPITAL NAME

Pennridge Animal
Hospital

REFERRING VET

Dr. Jen Makem

INVOICE

74771

DATE

4/28/26

Gallbladder is moderately distended with anechoic bile as well as suspended and gravity dependent echogenic debris. The wall is smooth without visible thickening. There is no evidence of cystic or CBD dilation. There is no evidence of effusion or inflammation.

Gastrointestinal

The visible stomach wall is normal in thickness and layering. The lumen of the stomach is empty with no evidence of obstruction, foreign material or infiltrative disease. Pyloric outflow tract appears patent.

The visible small intestines are normal in wall thickness and layering. Small intestinal motility appears adequate (1-3 contractions per min). The lumen of the small intestine is empty with no evidence of obstruction, foreign material or infiltrative disease.

The visible colon is normal in wall thickness (< 0.2 cm) and layering. Contents are consistent with normal formed feces and gas.

Pancreas

The pancreas that is observed appears appropriately isoechoic to surrounding omental fat. Visible capsule is smooth and normal in contour. Visible pancreatic parenchyma is homogenous and unremarkable. There is no visible pancreatic duct dilation. There is no evidence of active peripancreatic inflammation.

Free Abdomen

There is no visible free peritoneal effusion noted in these images.

There is no apparent pathologic lymphadenopathy noted in these images.

ULTRASONOGRAPHIC FINDINGS

- Mild gallbladder debris - Cholecystic debris is of unknown clinical significance. It can be seen with biliary stasis from fasting or illness. Cholecystic debris is not necessarily related to hepatobiliary disease. Echogenic bile is most commonly an incidental finding in dogs and should be interpreted in combination with clinical signs such as nausea, inappetence, cranial abdominal discomfort and/or laboratory changes such as increased ALP and/or increased Tbili.

INTERPRETATION OF THE FINDINGS & FURTHER RECOMMENDATIONS

There is no definitive ultrasonographically visible intraabdominal evidence of kidney disease or other contributions to the progressive proteinuria. Recommendations include continued evaluation for and treatment of infectious diseases and beginning/continuing medical management as indicated for protein losing nephropathy.



PATIENT

Ruby Patterson

SPECIES

Canine

BREED

Smooth Fox Terrier

SEX

Spayed Female

AGE

9.4 Years

WEIGHT

16 lbs

INTERPRETED BY

Beth Johnson, DVM
DACVIM

IMAGING PERFORMED BY

Dr. Kristen Carpenter

HOSPITAL NAME

Pennridge Animal
Hospital

REFERRING VET

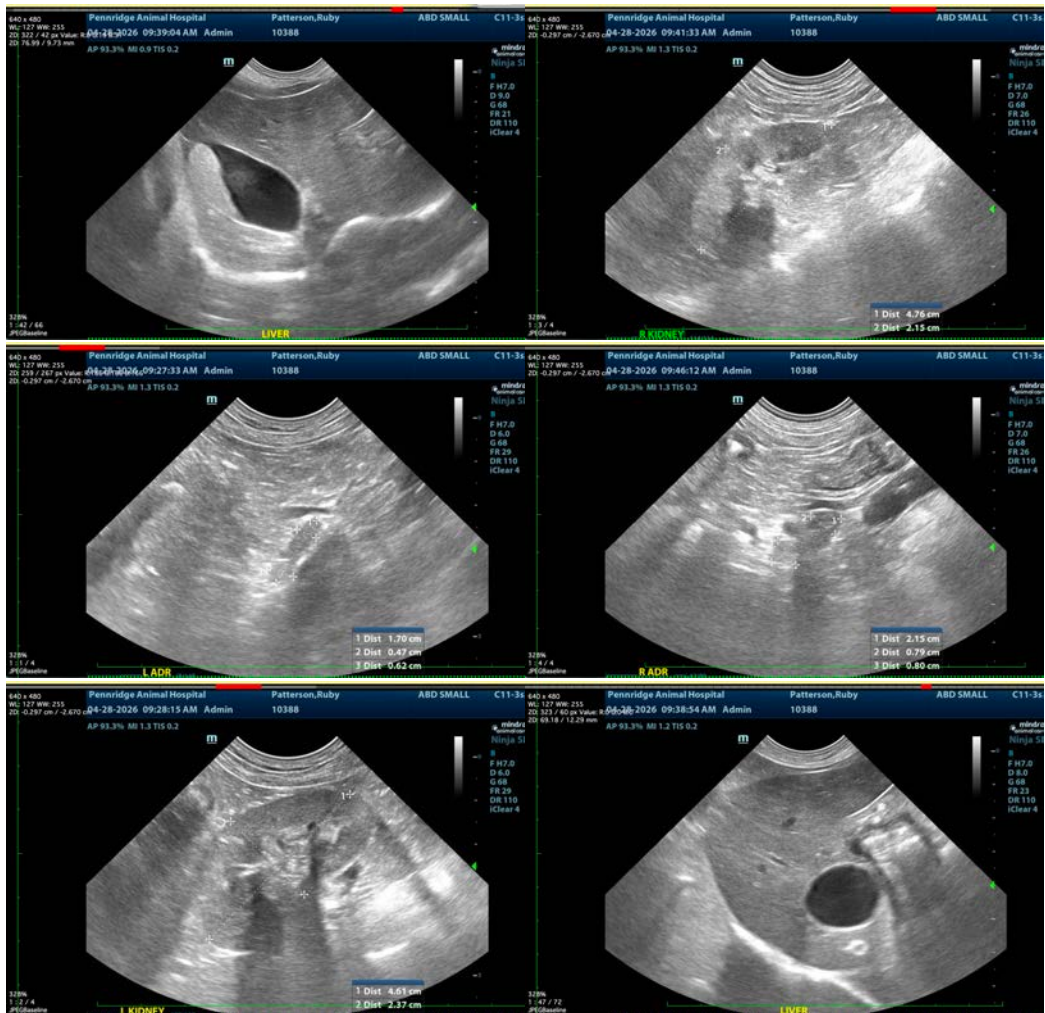
Dr. Jen Makem

INVOICE

74771

DATE

4/28/26



The information and recommendations provided are based on the images presented by the referring veterinarian/sonographer. No evaluation can be communicated regarding pathology that was not visible in the image/video clips provided.

Thank you for this referral. If the clinical or image interpretation does not parallel your findings or if I can be of any further assistance please contact me.

Beth Johnson, DVM, DACVIM
info@sonopath.com