



## PATIENT

Winnie Fifarek

## SPECIES

Canine

## BREED

Lab

## SEX

Spayed Female

## AGE

10 Years

## WEIGHT

57 Pounds

## INTERPRETED BY

Beth Johnson, DVM,  
DACVIM (SAIM)

## IMAGING PERFORMED BY

Julia Bakker, DVM

## HOSPITAL NAME

Orange Blossom VI

## REFERRING VET

John Fifarek, DVM

## INVOICE

36847

## DATE

4/27/26

## PRESENTING CLINICAL SIGNS

History: Senior wellness screening.

## ULTRASONOGRAPHIC EXAMINATION OF THE ABDOMEN

### *Urinary System*

Urinary bladder is adequately distended with anechoic contents. No masses, inflammatory changes, echogenic sediment or cystoliths are observed. The urinary bladder, trigone and visible pelvic urethra are normal in thickness with a smooth mucosal surface, except for a very subtle change in the dorsal trigone area where the wall is mildly thick, measuring 0.3 cm thick, with a smooth echogenic appearance consistent with a prominent ureteral papilla versus other. Infiltrative pathology can't be ruled out but is considered less likely. This finding should be interpreted in combination with clinical history, urinalysis results, etc.

Left kidney is normal in size (5.87 cm), shape and echogenicity. It has smooth peripheral margination. There is a normal 1:3 cortex to medulla ratio with appropriate corticomedullary distinction. There is no evidence of pyelectasia, mineral or infarcts observed.

Right kidney is normal in size (5.65 cm), shape and echogenicity. It has smooth peripheral margination. There is a normal 1:3 cortex to medulla ratio with appropriate corticomedullary distinction. There is no evidence of pyelectasia, mineral or infarcts observed.

### *Adrenal Glands*

Adrenal glands are plump/swollen in size. Normal shape and contour are maintained without evidence of capsular invasion. Corticomedullary structure is unremarkable. Visible surrounding vasculature appears normal. The left adrenal gland measures 0.94 cm at the cranial pole and 0.94 cm at the caudal pole. The right adrenal gland measures 1.9 cm at the cranial pole and 0.95 cm at the caudal pole. Hyperechoic nodules are noted in the cranial and caudal poles of the left adrenal gland. Nodules do not disrupt normal shape and/or architecture.

### *Spleen*

Spleen is subjectively normal in size with a normal smooth capsular contour. Parenchyma is appropriately finely textured and homogenous with normal echogenicity relative to surrounding tissue (hyperechoic to liver). No focal nodules or masses are observed. Splenic vasculature appears normal.

### *Liver*

Liver is subjectively enlarged with mildly irregular margins. Parenchyma is mildly heterogenous characterized by multiple poorly defined hypoechoic nodules within otherwise hyperechoic liver parenchyma. Visible vasculature and biliary tree appear normal without distension or congestion.

Gallbladder is moderately distended with anechoic bile as well as suspended and gravity dependent echogenic debris. The wall is smooth without visible thickening. There is no evidence of cystic or CBD dilation. There is no evidence of effusion or inflammation.

### *Gastrointestinal*



## PATIENT

Winnie Fifarek

The visible stomach wall is normal in thickness and layering. The lumen of the stomach is empty with no evidence of obstruction, foreign material or infiltrative disease. Pyloric outflow tract appears patent.

## SPECIES

Canine

The visible small intestines are normal in wall thickness and layering. Small intestinal motility appears adequate (1-3 contractions per min). The lumen of the small intestine is empty with no evidence of obstruction, foreign material or infiltrative disease.

## BREED

Lab

The visible colon is normal in wall thickness (< 0.2 cm) and layering. Contents are consistent with normal formed feces and gas.

## SEX

Spayed Female

The pancreas that is observed appears appropriately isoechoic to surrounding omental fat. Visible capsule is smooth and normal in contour. Visible pancreatic parenchyma is homogenous and unremarkable. There is no visible pancreatic duct dilation. There is no evidence of active peripancreatic inflammation.

## AGE

10 Years

### *Pancreas*

## WEIGHT

57 Pounds

There is no visible free peritoneal effusion noted in these images.

There is no apparent pathologic lymphadenopathy noted in these images.

## ULTRASONOGRAPHIC FINDINGS

### INTERPRETED BY

Beth Johnson, DVM,  
DACVIM (SAIM)

- Mildly heterogenous liver – These changes are most consistent with benign processes such as nodular hyperplasia, steroid (vacuolar) hepatopathy, extramedullary hematopoiesis or possibly chronic inflammatory disease and less commonly infiltrative round cell or metastatic neoplasia.

### IMAGING PERFORMED BY

Julia Bakker, DVM

- Mild gallbladder debris - Cholecystic debris is of unknown clinical significance. It can be seen with biliary stasis from fasting or illness. Cholecystic debris is not necessarily related to hepatobiliary disease. Echogenic bile is most commonly an incidental finding in dogs and should be interpreted in combination with clinical signs such as nausea, inappetence, cranial abdominal discomfort and/or laboratory changes such as increased ALP and/or increased Tbili.

### HOSPITAL NAME

Orange Blossom VI

- Bilateral adrenomegaly– In a patient diagnosed with hyperadrenocorticism, this finding is most consistent with adrenal hyperplasia secondary to pituitary dependent hyperadrenocorticism. This finding can also be seen with stress and/or normal patient variant. Interpret in combination with clinical signs of hyperadrenocorticism and/or other adrenal disease.

### REFERRING VET

John Fifarek, DVM

## INVOICE

36847

## DATE

4/27/26

- Hyperechoic adrenal nodules in the cranial and caudal poles of the left adrenal gland – Differentials include primary adrenal cortical adenomas or adenocarcinomas, pheochromocytomas, myelolipomas, adrenal hyperplasia secondary to pituitary disease or metastatic disease. Ultrasound alone cannot differentiate between functional and non-functional nodules and/or between benign and malignant disease. Small nodules without other evidence of abdominal disease (to suggest metastatic disease) and/or clinical signs (to suggest adrenal disease) are most often incidental and should be monitored.

- A subjectively prominent ureteral papilla as described above.



## PATIENT

Winnie Fifarek

## SPECIES

Canine

## BREED

Lab

## SEX

Spayed Female

## AGE

10 Years

## WEIGHT

57 Pounds

## INTERPRETED BY

Beth Johnson, DVM,  
DACVIM (SAIM)

## IMAGING PERFORMED BY

Julia Bakker, DVM

## HOSPITAL NAME

Orange Blossom VI

## REFERRING VET

John Fifarek, DVM

## INVOICE

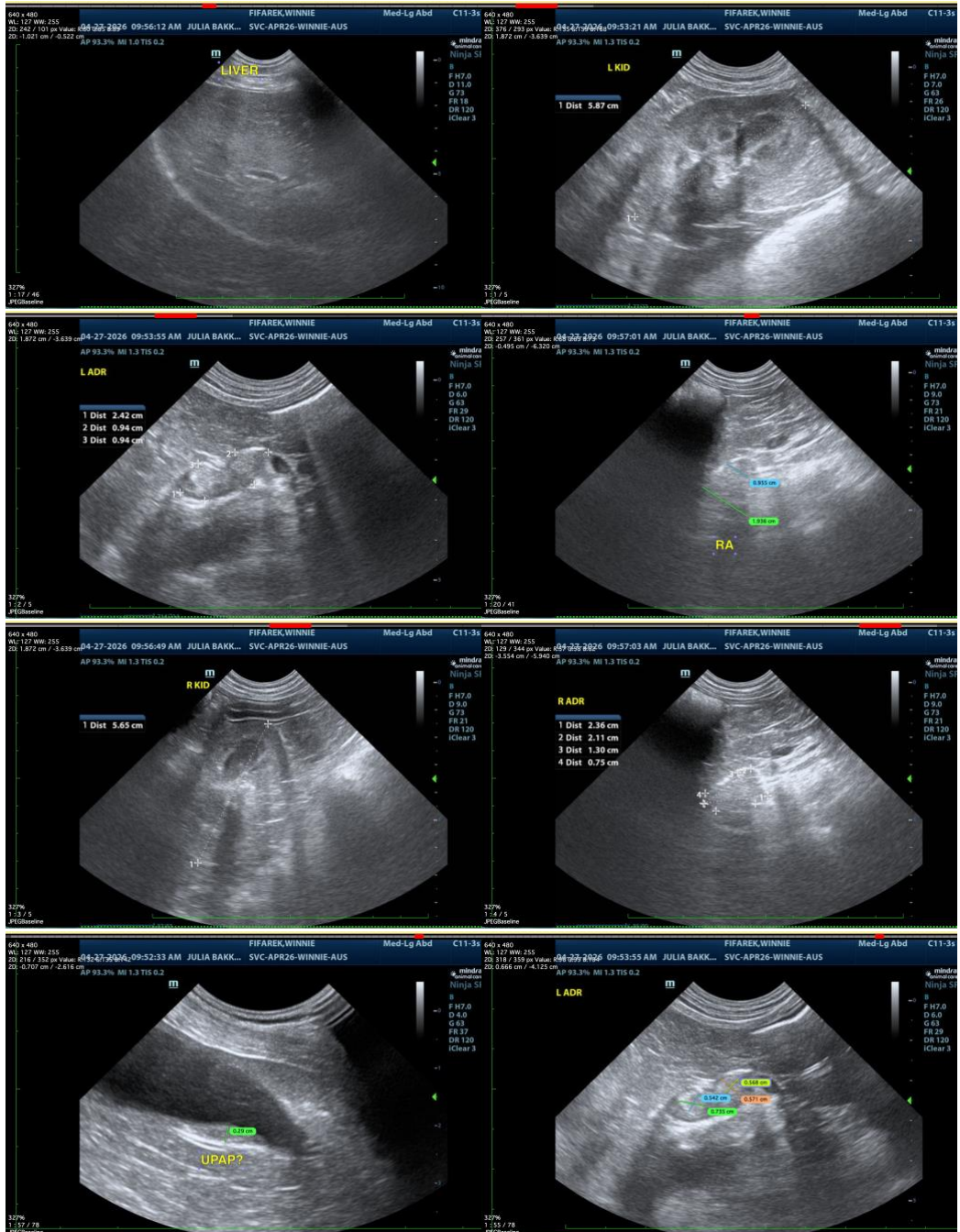
36847

## DATE

4/27/26

## INTERPRETATION OF THE FINDINGS & FURTHER RECOMMENDATIONS

Further recommendations given the mild ultrasound changes described above are largely dependent on patient's clinical history, especially regarding the adrenal gland changes, which could be normal patient variant/age-related changes in the face of a normal clinical history. A blood pressure is recommended if not recently evaluated. Otherwise, continued wellness screening including CBC, chemistry panel, electrolytes, urinalysis and three view thoracic radiographs could be considered.





## PATIENT

Winnie Fifarek

## SPECIES

Canine

## BREED

Lab

## SEX

Spayed Female

## AGE

10 Years

## WEIGHT

57 Pounds

## INTERPRETED BY

Beth Johnson, DVM,  
DACVIM (SAIM)

## IMAGING PERFORMED BY

Julia Bakker, DVM

## HOSPITAL NAME

Orange Blossom VI

## REFERRING VET

John Fifarek, DVM

## INVOICE

36847

## DATE

4/27/26

The information and recommendations provided are based on the images presented by the referring veterinarian/sonographer. No evaluation can be communicated regarding pathology that was not visible in the image/video clips provided.

Thank you for this referral. If the clinical or image interpretation does not parallel your findings or if I can be of any further assistance please contact me.

**Beth Johnson, DVM DACVIM**

info@sonopath.com