



PATIENT

Diesel Graziano

SPECIES

Feline

BREED

DSH

SEX

Male

AGE

16 Years

WEIGHT

9.4

INTERPRETED BY

Beth Johnson, DVM,
DACVIM (SAIM)

IMAGING PERFORMED BY

Dr. Brian Hougentogler

HOSPITAL NAME

K-Vet Animal Care

REFERRING VET

Dr. Vanessa Bouch

INVOICE

36846

DATE

4/27/26

PRESENTING CLINICAL SIGNS

History: Patient has been losing weight despite a good appetite and acting normal otherwise_ grade II/VI systolic heart murmur.

Abnormal PE/Chem/CBC/UA Results: Urine SG - 1.016; UPC - 0.4; BUN - 39; fPL - 8.5_

ULTRASONOGRAPHIC EXAMINATION OF THE ABDOMEN

Urinary System

Urinary bladder is adequately distended with anechoic contents. No masses, inflammatory changes, echogenic sediment or cystoliths are observed. The urinary bladder, trigone and visible pelvic urethra are normal in thickness with a smooth mucosal surface.

Kidneys are bilaterally irregular and diffusely echogenic with decreased corticomedullary distinction and poor visualization of internal architecture. There is no pyelectasia noted and no mineral is observed. The left kidney is small/normal, measuring 3.64 cm. The right kidney is normal in size, measuring 3.96 cm.

Adrenal Glands

Left adrenal gland is normal in size (0.45 cm), shape and overall architecture, echogenicity and echotexture. Visible surrounding vasculature appears normal.

Right adrenal gland is normal in size (0.56 cm), shape and overall architecture, echogenicity and echotexture. Visible surrounding vasculature appears normal.

Spleen

Spleen is subjectively normal in size with a normal smooth capsular contour. Parenchyma is appropriately finely textured and homogenous with normal echogenicity relative to surrounding tissue (hyperechoic to liver). No focal nodules or masses are observed. Splenic vasculature appears normal.

Liver

Liver is subjectively normal in size with normal smooth curvilinear peripheral contour. Parenchyma is appropriately hypoechoic to the spleen in echogenicity and appropriately mildly coarse and homogenous in echotexture. No focal lesions are observed. Visible vasculature and biliary tree appear normal without distension or congestion.

Gallbladder is non-distended in size. The wall is smooth without visible thickening. Luminal contents are primarily anechoic. There is no evidence of cystic or common bile duct dilation.

Gastrointestinal

The visible stomach wall is normal in thickness and layering. The lumen of the stomach is empty with no evidence of obstruction, foreign material or infiltrative disease. Pyloric outflow tract appears patent.

The visible small intestine demonstrates areas of moderate to severely thick muscularis layer relative to mucosa (disruption of the normal 1:3 muscularis:mucosa ratio). Small intestinal submucosa is slightly



PATIENT

Diesel Graziano

SPECIES

Feline

BREED

DSH

SEX

Male

AGE

16 Years

WEIGHT

9.4

INTERPRETED BY

Beth Johnson, DVM,
DACVIM (SAIM)

IMAGING PERFORMED BY

Dr. Brian Hougentogler

HOSPITAL NAME

K-Vet Animal Care

REFERRING VET

Dr. Vanessa Bouch

INVOICE

36846

DATE

4/27/26

irregular, thick and hyperechoic, without evident loss of layering appreciated. The lumen of the small intestine is empty with no evidence of obstruction or foreign material.

The visible colon is normal in wall thickness (< 0.2 cm) and layering. Contents are consistent with normal formed feces and gas.

Pancreas

Pancreas is prominent in size, hypoechoic to surrounding tissue and has a mildly irregular undulating contour. Parenchyma is coarse with mixed echogenic remodeling noted. No pancreatic duct dilation is noted.

Free Abdomen

There is no visible free peritoneal effusion noted in these images.

There is no apparent pathologic lymphadenopathy noted in these images.

ULTRASONOGRAPHIC FINDINGS

- Moderate inflammatory bowel disease pattern – Thick muscularis has been reported with infiltrative bowel disease including both benign inflammatory disease as well as infiltrative neoplasia such as lymphoma. No loss of layering or distinct characteristics of malignancy are present. Therefore, differentials cannot be further ranked without tissue sampling.
- Concurrent chronic low brain smoldering pancreatitis can't be ruled out and should be suspected in the face of appropriate clinical signs.
- Mild to moderate bilateral chronic kidney disease changes

INTERPRETATION OF THE FINDINGS & FURTHER RECOMMENDATIONS

- Given the concern for possible emerging chronic kidney disease, if not recently evaluated, a blood pressure is recommended.
- A T4 +/- free t4 is recommended if not recently evaluated.
- A gastrointestinal malabsorption panel (including cobalamin, folate, TLI and PLI) to Texas A&M GI Laboratory is recommended for further evaluation of GI and pancreatic function.
- Ideally, biopsies of the GI tract, being sure to include ileum, if possible, are recommended to definitively diagnose and therefore manage the infiltrative bowel disease.
- If biopsies cannot be obtained, empirical therapies could include a probiotic (if diarrhea is present, such as visbiome or proviable), empirical deworming with a 5-day course of Panacur and, if tolerated, a transition in diet, based on trial-and-error response, beginning with a hydrolyzed protein diet. Some patients respond to one brand/version of a hydrolyzed protein diet better than another brand, so several trials may be required.
- Additional considerations could include cobalamin supplementation (unless cobalamin level is evaluated and supplementation is not warranted) and prednisolone (if not contraindicated based on patient contraindications, co-morbidities, etc.).



PATIENT

Diesel Graziano

SPECIES

Feline

BREED

DSH

SEX

Male

AGE

16 Years

WEIGHT

9.4

INTERPRETED BY

Beth Johnson, DVM,
DACVIM (SAIM)

IMAGING PERFORMED BY

Dr. Brian Hougentogler

HOSPITAL NAME

K-Vet Animal Care

REFERRING VET

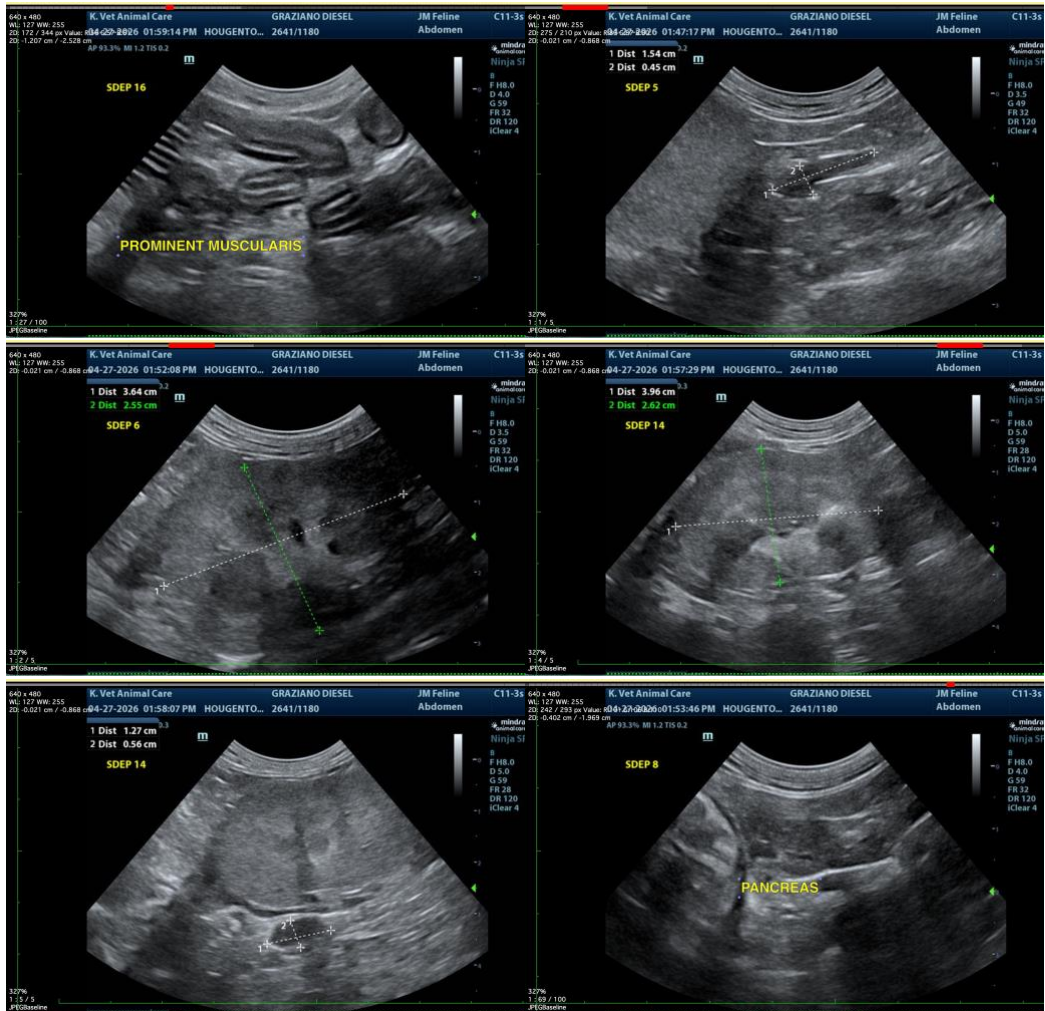
Dr. Vanessa Bouch

INVOICE

36846

DATE

4/27/26



The information and recommendations provided are based on the images presented by the referring veterinarian/sonographer. No evaluation can be communicated regarding pathology that was not visible in the image/video clips provided.

Thank you for this referral. If the clinical or image interpretation does not parallel your findings or if I can be of any further assistance please contact me.

Beth Johnson, DVM DACVIM

info@sonopath.com