



PATIENT

Oreo Emerald Ark
Rescue

SPECIES

Canine

BREED

Schipperke x

SEX

Spayed Female

AGE

9 Years

WEIGHT

19.6 lbs

INTERPRETED BY

Beth Johnson, DVM
DACVIM

IMAGING PERFORMED BY

Loetitia Saint-Jacques,
LVT

HOSPITAL NAME

MountainView Animal
Hospital

REFERRING VET

Dr. Ashlie Brown

INVOICE

74754

DATE

4/23/26

PRESENTING CLINICAL SIGNS

Patient was adopted 5.19.25. She was adopted with hind limb paresis. General blood work was performed at that time which showed an ALT of 680 and concurrent UTI. Mom is very holistic with her approach and antibiotics were used for the UTI, but limited improvement (concern for incomplete bladder emptying), and Mom elected to move forward with an herbal and supplements for her UTI. Liver supplements were started at the same time and the last liver value was 553 in January 2026. Mom runs a rescue so there has been lapse in treatment, but she has obtained the funds to have an US to check her liver, and bile acids test today.

ULTRASONOGRAPHIC EXAMINATION OF THE ABDOMEN

Urinary System

Urinary bladder is adequately distended with primarily anechoic contents and occasional echogenic non-shadowing debris. Apical urinary bladder wall is mildly thick (0.35 cm). Mucosa is hyperechoic and irregular. No masses or cystoliths are observed. The trigone and visible pelvic urethra are normal thickness with a smooth mucosal surface.

The right kidney is normal is size (4.7 cm), shape and echogenicity. It has smooth peripheral margination. There is a normal 1:3 cortex to medulla ratio with appropriate corticomedullary distinction. There is no evidence of pyelectasia, mineral or infarcts observed. A subtle hyperechoic band parallel to the corticomedullary border is present.

The left kidney is normal is size (4.4 cm), shape and echogenicity. It has smooth peripheral margination. There is a normal 1:3 cortex to medulla ratio with appropriate corticomedullary distinction. There is no evidence of pyelectasia, mineral or infarcts observed. A subtle hyperechoic band parallel to the corticomedullary border is present.

Adrenal Glands

The caudal pole of the right adrenal gland is normal in size (0.62 cm), shape and overall architecture, echogenicity and echotexture. Visible surrounding vasculature appears normal. The cranial pole is unable to be fully isolated/differentiated for measurement.

The left adrenal gland is normal in size (0.51 cm at cranial pole and 0.59 cm at caudal pole), shape and overall architecture, echogenicity and echotexture. Visible surrounding vasculature appears normal.

Spleen

The spleen is subjectively normal in size with a normal smooth capsular contour. Parenchyma is appropriately finely textured and homogenous with normal echogenicity relative to surrounding tissue (hyperechoic to liver). No focal nodules or masses are observed. Splenic vasculature appears normal.

Liver

Liver is subjectively enlarged (swollen contour) with a diffusely mildly coarse architecture and subtly increased portal markings. Mildly mixed echogenic changes are noted diffusely. No focal lesions are observed. Visible vasculature and biliary tree appear normal without distension or congestion.

The gallbladder is non-distended in size. The wall is smooth without visible thickening. Luminal contents are primarily anechoic. There is no evidence of cystic or common bile duct dilation.



PATIENT

Oreo Emerald Ark
Rescue

SPECIES

Canine

BREED

Schipperke x

SEX

Spayed Female

AGE

9 Years

WEIGHT

19.6 lbs

INTERPRETED BY

Beth Johnson, DVM
DACVIM

**IMAGING
PERFORMED BY**

Loetitia Saint-Jacques,
LVT

HOSPITAL NAME

MountainView Animal
Hospital

REFERRING VET

Dr. Ashlie Brown

INVOICE

74754

DATE

4/23/26

Gastrointestinal

The visible stomach wall is normal in thickness and layering. The lumen of the stomach is empty with no evidence of obstruction, foreign material or infiltrative disease. Pyloric outflow tract appears patent.

The visible small intestines are normal in wall thickness and layering. Small intestinal motility appears adequate (1-3 contractions per min). The lumen is mildly distended with echogenic non-shadowing luminal contents and gas consistent with normal ingesta/chyme. There is no evidence of obstruction, foreign material or infiltrative disease.

The visible colon is normal in wall thickness (< 0.2 cm) and layering. Contents are consistent with normal formed feces and gas.

Pancreas

The pancreas that is observed appears appropriately isoechoic to surrounding omental fat. Visible capsule is smooth and normal in contour. Visible pancreatic parenchyma is homogenous and unremarkable. There is no visible pancreatic duct dilation. There is no evidence of active peripancreatic inflammation.

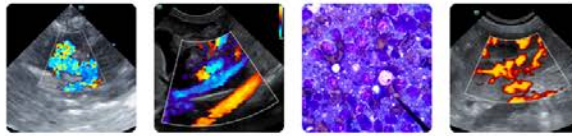
Free Abdomen

There is a trace amount of anechoic free fluid present.

Medial iliac lymph nodes are prominent in size with swollen capsular contour. Normal elongated shape (length to width ratio) is maintained. There is no loss of parenchymal detail.

ULTRASONOGRAPHIC FINDINGS

- An obvious cause for the subtle liver changes is not identified in these images. Microscopic disease such as Leptospirosis, bacterial cholangiohepatitis, chronic active hepatitis, copper-associated hepatotoxicity, other hepatotoxicity, other reactive hepatopathy, infiltrative neoplasia (considered unlikely), etc. cannot be definitively ruled out.
- Subtle bilateral medullary rim sign - This finding is of unknown clinical significance and can be a normal variant, often idiopathic. Medullary rim sign can be present with renal disease including lymphoma, hypercalcemic nephropathy, Leptospirosis, tubular disease, other and should be interpreted in combination with other more specific indications of kidney disease such as isosthenuria, proteinuria, azotemia, etc. This is a common incidental finding in patients with diabetes mellitus.
- Mild chronic cystitis - Urinary bladder wall changes are most consistent with chronic cystitis. Infiltrative neoplasia cannot be ruled out but is considered less likely give the location and diffuse nature of the changes.
- Mildly to moderately reactive medial iliac lymph nodes – infiltrative neoplastic disease cannot be ruled out but is considered less likely.
- Scant/trace free fluid.



PATIENT

Oreo Emerald Ark
Rescue

SPECIES

Canine

BREED

Schipperke x

SEX

Spayed Female

AGE

9 Years

WEIGHT

19.6 lbs

INTERPRETED BY

Beth Johnson, DVM
DACVIM

IMAGING PERFORMED BY

Loetitia Saint-Jacques,
LVT

HOSPITAL NAME

MountainView Animal
Hospital

REFERRING VET

Dr. Ashlie Brown

INVOICE

74754

DATE

4/23/26

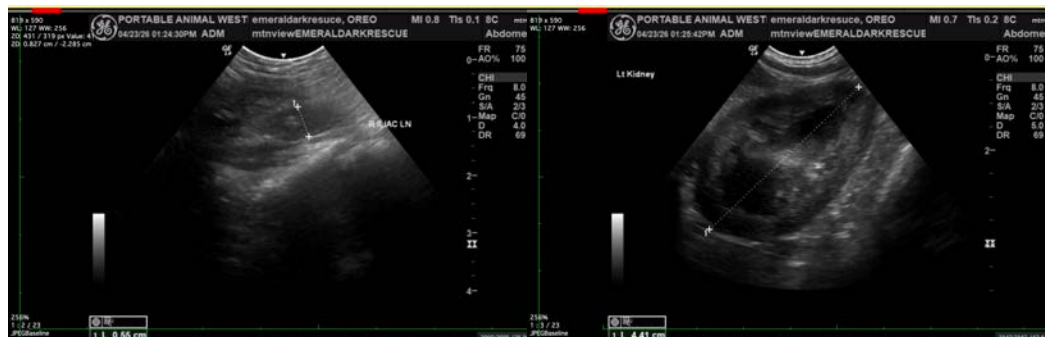
INTERPRETATION OF THE FINDINGS & FURTHER RECOMMENDATIONS

Differentials for a primary hepatocellular injury liver enzyme pattern (increased ALT) depend partially on the level of increase. Mild increases (less than 2 times normal) are often a “reactive hepatopathy” or the liver’s response to an insult elsewhere in the body including, but not limited to, pancreatitis, gastroenteritis, parasitic disease, dental disease, vacuolar or endocrine hepatopathy from diabetes mellitus or hyperadrenocorticism (steroid-induced), hypoadrenocorticism, certain drugs (e.g. phenobarbital, corticosteroids, azathioprine, etc.), and muscle ALT (more likely if AST and CK concurrently increased).

It is a good indicator of active liver damage (cell membrane disruption, cellular necrosis), however, if the value is increased by at least 3-4 times normal. Differentials include infectious disease, including Leptospirosis, inflammatory disease (ie. active hepatitis, copper, other), toxic insult as well as infiltrative neoplasia.

ALT levels vary in cases of vascular anomalies such as microvascular dysplasia and portosystemic shunts (PSS), but are often less significantly increased.

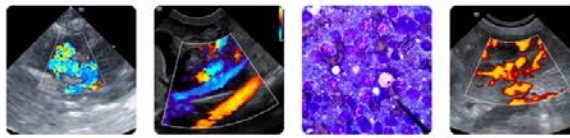
- Testing for Leptospirosis could be considered.
- Bile acids could be considered, if tbil is not increased.
- An empirical course of antibiotics and empirical hepatic nutraceuticals may be tried, with monitoring of ALT for improvement. If improvement is noted, antibiotics should be continued until liver enzymes either normalize or plateau (recheck every 2-3 weeks); however, if improvement is not noted and/or enzyme increase progresses, antibiotics should not be continued long term and liver tissue sampling is recommended.
- FNA of the liver can be performed to assess inflammatory cell type, rule in/out round cell neoplasia, etc. (if patient’s coagulation status is appropriate).
- If round cell neoplasia is not diagnosed, a liver biopsy (including copper level assessment) may be required to definitively diagnose the underlying hepatopathy.



Imaging performed by



pawsonography@gmail.com
530-786-8340



Clinical Sonography & Teletyology
Educational Teleconsultation Services™

SonoPath

FOSTERING THE ART OF VETERINARY MEDICINE™

SonoPath.com info@sonopath.com 1.800.838.4268

PATIENT

Oreo Emerald Ark
Rescue

SPECIES

Canine

BREED

Schipperke x

SEX

Spayed Female

AGE

9 Years

WEIGHT

19.6 lbs

INTERPRETED BY

Beth Johnson, DVM
DACVIM

IMAGING PERFORMED BY

Loetitia Saint-Jacques,
LVT

HOSPITAL NAME

MountainView Animal
Hospital

REFERRING VET

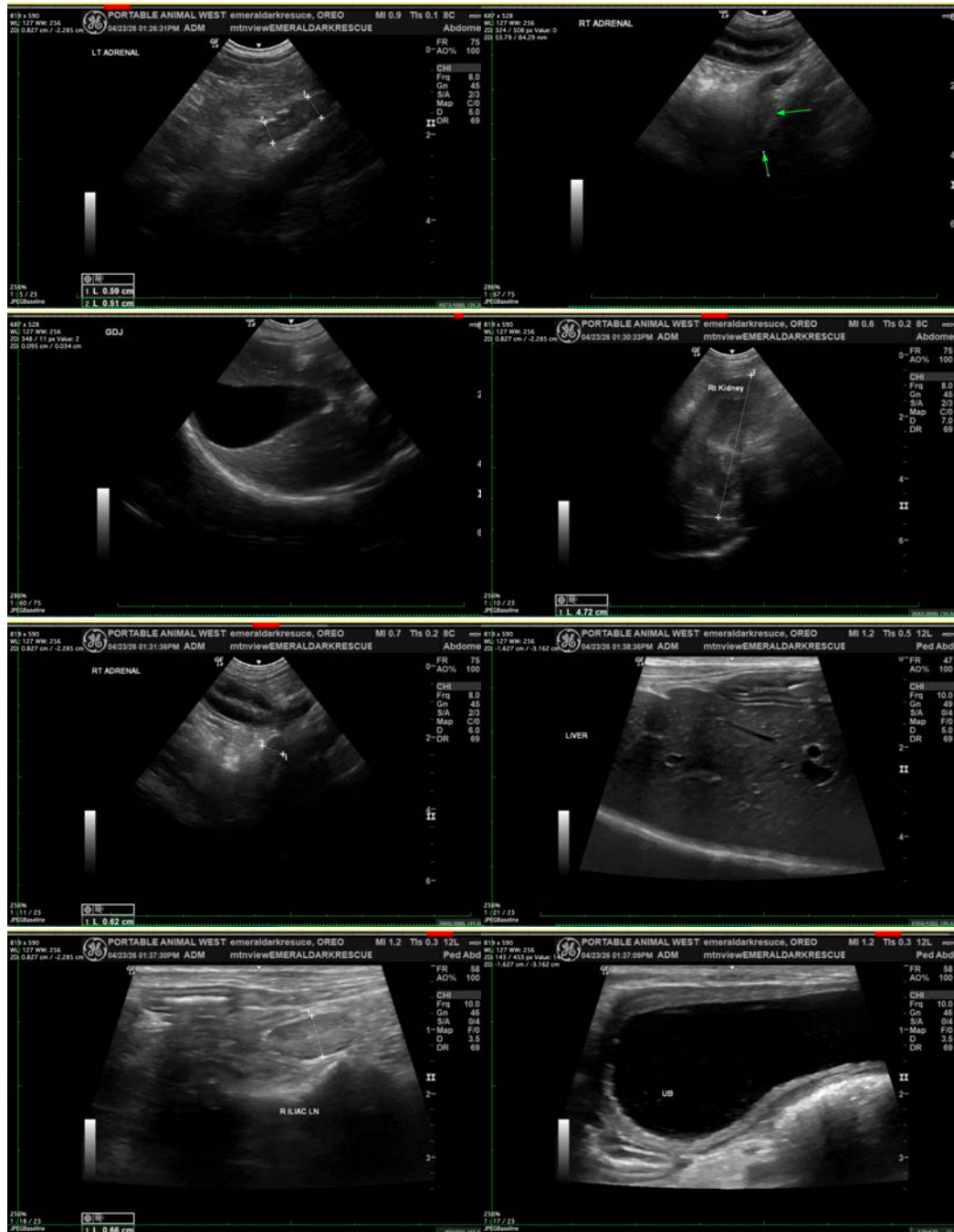
Dr. Ashlie Brown

INVOICE

74754

DATE

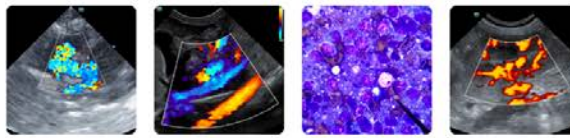
4/23/26



Imaging
performed by



Portland Animal Hospital Sonography, Inc.
pawsonography@gmail.com
530-786-8340



Clinical Sonography & Telectyology
Educational Teleconsultation Services™

SonoPath

FOSTERING THE ART OF VETERINARY MEDICINE™

SonoPath.com info@sonopath.com 1.800.838.4268

PATIENT

Oreo Emerald Ark
Rescue

SPECIES

Canine

BREED

Schipperke x

SEX

Spayed Female

AGE

9 Years

WEIGHT

19.6 lbs

INTERPRETED BY

Beth Johnson, DVM
DACVIM

IMAGING PERFORMED BY

Loetitia Saint-Jacques,
LVT

HOSPITAL NAME

MountainView Animal
Hospital

REFERRING VET

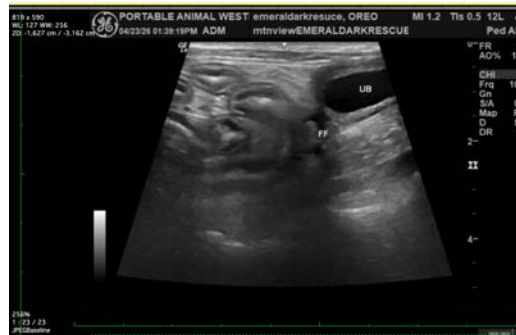Dr. Ashlie Brown

INVOICE

74754

DATE

4/23/26



The information and recommendations provided are based on the images presented by the referring veterinarian/sonographer. No evaluation can be communicated regarding pathology that was not visible in the image/video clips provided.

Thank you for this referral. If the clinical or image interpretation does not parallel your findings or if I can be of any further assistance please contact me.

Beth Johnson, DVM, DACVIM
info@sonopath.com