

**PATIENT**

Bodhi Gibson

SPECIES

Canine

BREED

Boxer

SEX

Neutered Male

AGE

8 Years

WEIGHT

77 lbs

INTERPRETED BYBeth Johnson, DVM
DACVIM**IMAGING
PERFORMED BY**

Julia Bakker, DVM

HOSPITAL NAMEOrange Blossom
Veterinary Imaging**REFERRING VET**Michael Humphrey,
DVM**INVOICE**

74753

DATE

4/23/26

PRESENTING CLINICAL SIGNS

Pet recently had left inguinal lymph node enlarged and FNA consistent with lymphoma. No other peripheral lymphadenopathy is present and thoracic radiographs are clear. AUS to look for metastasis.

ULTRASONOGRAPHIC EXAMINATION OF THE ABDOMEN**Urinary System**

The urinary bladder is adequately distended with anechoic contents. No masses, inflammatory changes, echogenic sediment or cystoliths are observed. The urinary bladder, trigone and visible pelvic urethra are normal in thickness with a smooth mucosal surface.

The prostate is unable to be well visualized in these images.

The right kidney is normal in size (5.38 cm), shape and echogenicity. It has smooth peripheral margination. There is a normal 1:3 cortex to medulla ratio with appropriate corticomedullary distinction. There is no evidence of pyelectasia, mineral or infarcts observed.

The left kidney is normal in size (5.77 cm), shape and echogenicity. It has smooth peripheral margination. There is a normal 1:3 cortex to medulla ratio with appropriate corticomedullary distinction. There is no evidence of pyelectasia, mineral or infarcts observed.

Adrenal Glands

The right adrenal gland is normal in size (0.86 cm at cranial pole and 0.54 cm at caudal pole), shape and overall architecture, echogenicity and echotexture. Visible surrounding vasculature appears normal.

The left adrenal gland is normal in size (0.75 cm at cranial pole and 0.67 cm at caudal pole), shape and overall architecture, echogenicity and echotexture. Visible surrounding vasculature appears normal.

Spleen

The spleen is subjectively normal in size with a normal smooth capsular contour. Parenchyma is appropriately finely textured and homogenous with normal echogenicity relative to surrounding tissue (hyperechoic to liver). No focal nodules or masses are observed. Splenic vasculature appears normal.

Liver

The liver is subjectively normal in size with normal smooth curvilinear peripheral contour. Parenchyma is appropriately hypoechoic to the spleen in echogenicity and appropriately mildly coarse and homogenous in echotexture. No focal lesions are observed. Visible vasculature and biliary tree appear normal without distension or congestion.

The gallbladder is non-distended in size. The wall is smooth without visible thickening. Luminal contents are primarily anechoic. There is no evidence of cystic or common bile duct dilation.

Gastrointestinal

The visible stomach wall is normal in thickness and layering. The lumen of the stomach is mildly distended with very echogenic reverberation artifact from intraluminal gas. There is no evidence of obstruction, foreign material, or infiltrative disease; however, visualization is partially inhibited by gas.



PATIENT

Bodhi Gibson

SPECIES

Canine

BREED

Boxer

SEX

Neutered Male

AGE

8 Years

WEIGHT

77 lbs

INTERPRETED BY

Beth Johnson, DVM
DACVIM

IMAGING PERFORMED BY

Julia Bakker, DVM

HOSPITAL NAME

Orange Blossom
Veterinary Imaging

REFERRING VET

Michael Humphrey,
DVM

INVOICE

74753

DATE

4/23/26

The visible small intestines are normal in wall thickness and layering. Small intestinal motility appears adequate (1-3 contractions per min). The lumen of the small intestine is empty with no evidence of obstruction, foreign material or infiltrative disease.

The visible colon is normal in wall thickness (< 0.2 cm) and layering. Contents are consistent with normal formed feces and gas.

Pancreas

The pancreas that is observed appears appropriately isoechoic to surrounding omental fat. Visible capsule is smooth and normal in contour. Visible pancreatic parenchyma is homogenous and unremarkable. There is no visible pancreatic duct dilation. There is no evidence of active peripancreatic inflammation.

Free Abdomen

There is no visible free peritoneal effusion noted in these images.

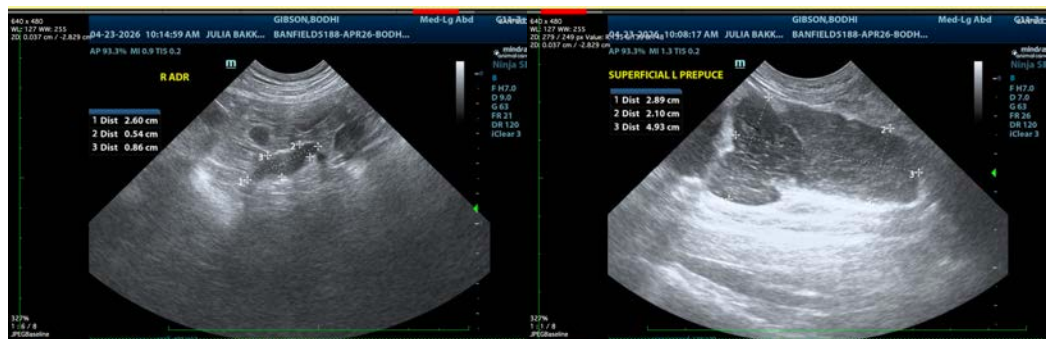
Diffusely from the sublumbar area to the cranial abdominal/portal lymph nodes, lymph nodes are enlarged with swollen irregular capsular contour and loss of normal length to width ratio (rounded in shape). Nodes are hypoechoic with loss of normal parenchymal detail.

ULTRASONOGRAPHIC FINDINGS

- Diffusely aggressive lymph nodes – concerning for infiltrative round cell or metastatic neoplasia. A benign aggressive inflammatory response cannot be ruled out without tissue sampling +/- culture.

INTERPRETATION OF THE FINDINGS & FURTHER RECOMMENDATIONS

This diffuse lymphadenopathy is consistent with patient's reportedly recent diagnosis of lymphoma, and consultation with a veterinary oncologist is recommended.





PATIENT

Bodhi Gibson

SPECIES

Canine

BREED

Boxer

SEX

Neutered Male

AGE

8 Years

WEIGHT

77 lbs

INTERPRETED BY

Beth Johnson, DVM
DACVIM

IMAGING PERFORMED BY

Julia Bakker, DVM

HOSPITAL NAME

Orange Blossom
Veterinary Imaging

REFERRING VET

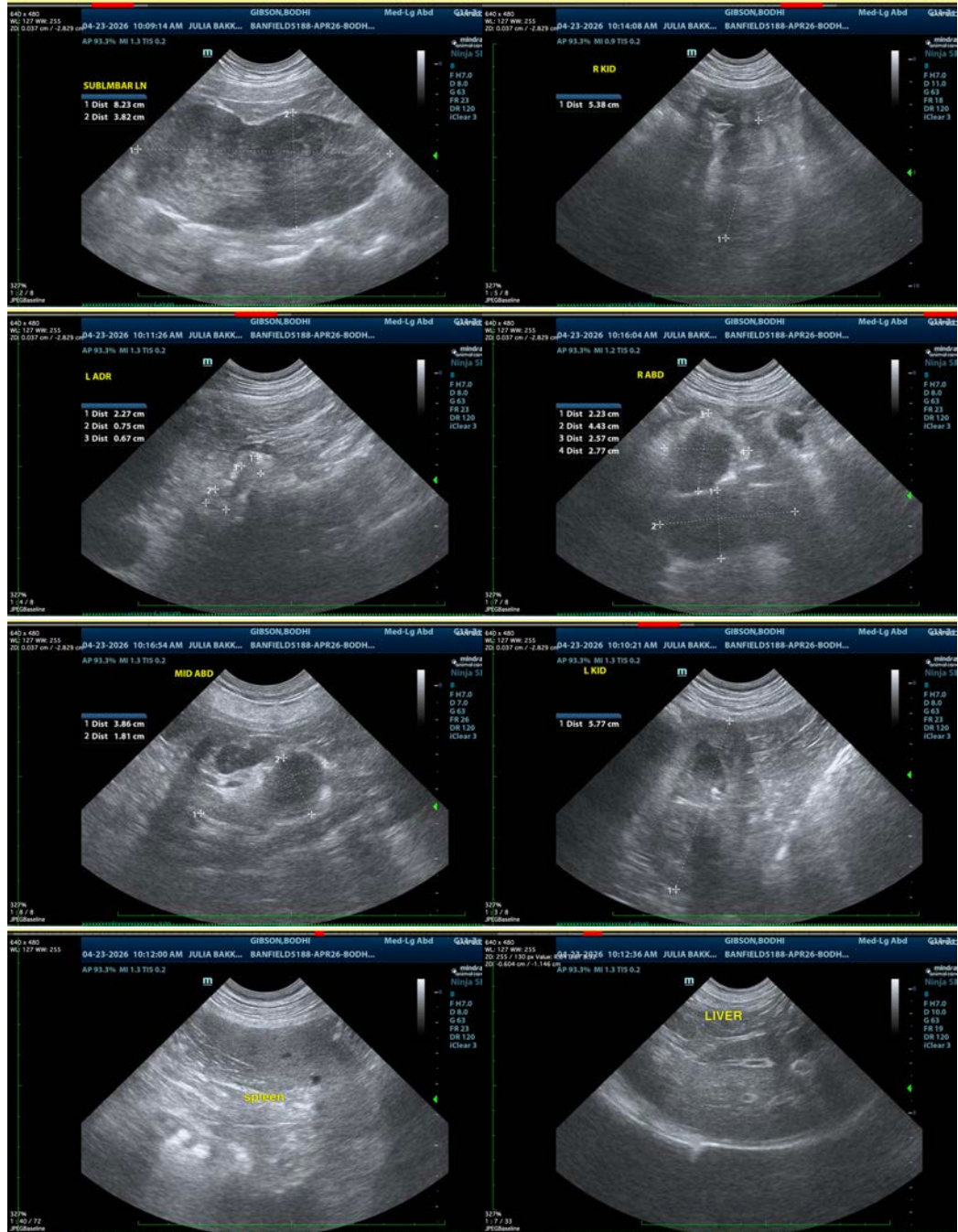
Michael Humphrey,
DVM

INVOICE

74753

DATE

4/23/26





PATIENT

Bodhi Gibson

SPECIES

Canine

BREED

Boxer

SEX

Neutered Male

AGE

8 Years

WEIGHT

77 lbs

INTERPRETED BY

Beth Johnson, DVM
DACVIM

IMAGING PERFORMED BY

Julia Bakker, DVM

HOSPITAL NAME

Orange Blossom
Veterinary Imaging

REFERRING VET

Michael Humphrey,
DVM

INVOICE

74753

DATE

4/23/26

The information and recommendations provided are based on the images presented by the referring veterinarian/sonographer. No evaluation can be communicated regarding pathology that was not visible in the image/video clips provided.

Thank you for this referral. If the clinical or image interpretation does not parallel your findings or if I can be of any further assistance please contact me.

Beth Johnson, DVM, DACVIM
info@sonopath.com