



**PATIENT**

Dutch Caulkett

**SPECIES**

Canine

**BREED**

Labrador Retriever

**SEX**

Male

**AGE**

10 Weeks

**WEIGHT**

5.1 kg

**INTERPRETED BY**

Beth Johnson, DVM  
DACVIM

**IMAGING PERFORMED BY**

Dr. Callihan

**HOSPITAL NAME**

Animal Emergency  
Care

**REFERRING VET**

Dr. Loeffler

**INVOICE**

46877

**DATE**

4/23/23

**PRESENTING CLINICAL SIGNS**

Presented yesterday for vomiting tree bark in the morning and being inappetant. There had been some foil in the stools and pup had been chewing on sticks/bark preceding days. He had a GI-centric ultrasound exam yesterday afternoon and was on IV fluids for few hours then discharged to home with instructions to feed slurry only, and to fast after 10pm last night to facilitate recheck this morning. No vomiting overnight but he did have one episode of "violent hiccups" last night.

Abnormal PE/Chem/CBC/UA Results: BAR on PE, happily eating recovery food from a Kong during the brief recheck exam. His PE in general is unremarkable-normal vitals, fully ambulatory and in no distress.

**LIMITED ULTRASONOGRAPHIC EXAMINATION**

**Gastrointestinal**

Pre overnight fasting, the stomach is visualized with a normal wall, but it is moderately distended with echogenic fluid and non-shadowing luminal contents and gas, consistent with normal ingesta and chyme, although foreign debris can't be definitively ruled out. There is no evidence of obstruction, foreign material or infiltrative disease, and the pyloric outflow tract appears patent.

The visible small intestines are normal in wall thickness and layering (canine duodenum < 0.5 cm and feline duodenum < 0.4 cm; other < 0.3 cm). Small intestinal motility appears adequate (1-3 contractions per min). The lumen of the small intestine is empty with no evidence of obstruction, foreign material or infiltrative disease.

In the images labeled post overnight fasting:

The stomach wall is normal in thickness (canine < 0.5 cm and feline < 0.4 cm) and layering. The lumen of the stomach is empty with no evidence of obstruction, foreign material or infiltrative disease. Pyloric outflow tract appears patent.

The visible small intestines are normal in wall thickness and layering (canine duodenum < 0.5 cm and feline duodenum < 0.4 cm; other < 0.3 cm). Small intestinal motility appears adequate (1-3 contractions per min). The lumen of the small intestine is empty with no evidence of obstruction, foreign material or infiltrative disease.

**Free Abdomen**

The mesenteric lymph nodes are prominent in size with swollen capsular contour. Normal elongated shape (length to width ratio) is maintained. There is no loss of parenchymal detail.

A very scant amount of anechoic free fluid is present.

**ULTRASONOGRAPHIC FINDINGS**

- Initially, a fluid and chyme distended stomach is appreciated without evident underlying cause. However, following overnight fasting, the stomach and bowel appear empty.
- Reactive mesenteric lymph nodes** – most likely normal patient variant for a puppy.
- Very scant amount of anechoic free fluid – also likely normal patient age variant.



**PATIENT**

Dutch Caulkett

**SPECIES**

Canine

**BREED**

Labrador Retriever

**SEX**

Male

**AGE**

10 Weeks

**WEIGHT**

5.1 kg

**INTERPRETED BY**

Beth Johnson, DVM  
DACVIM

**IMAGING PERFORMED BY**

Dr. Callihan

**HOSPITAL NAME**

Animal Emergency  
Care

**REFERRING VET**

Dr. Loeffler

**INVOICE**

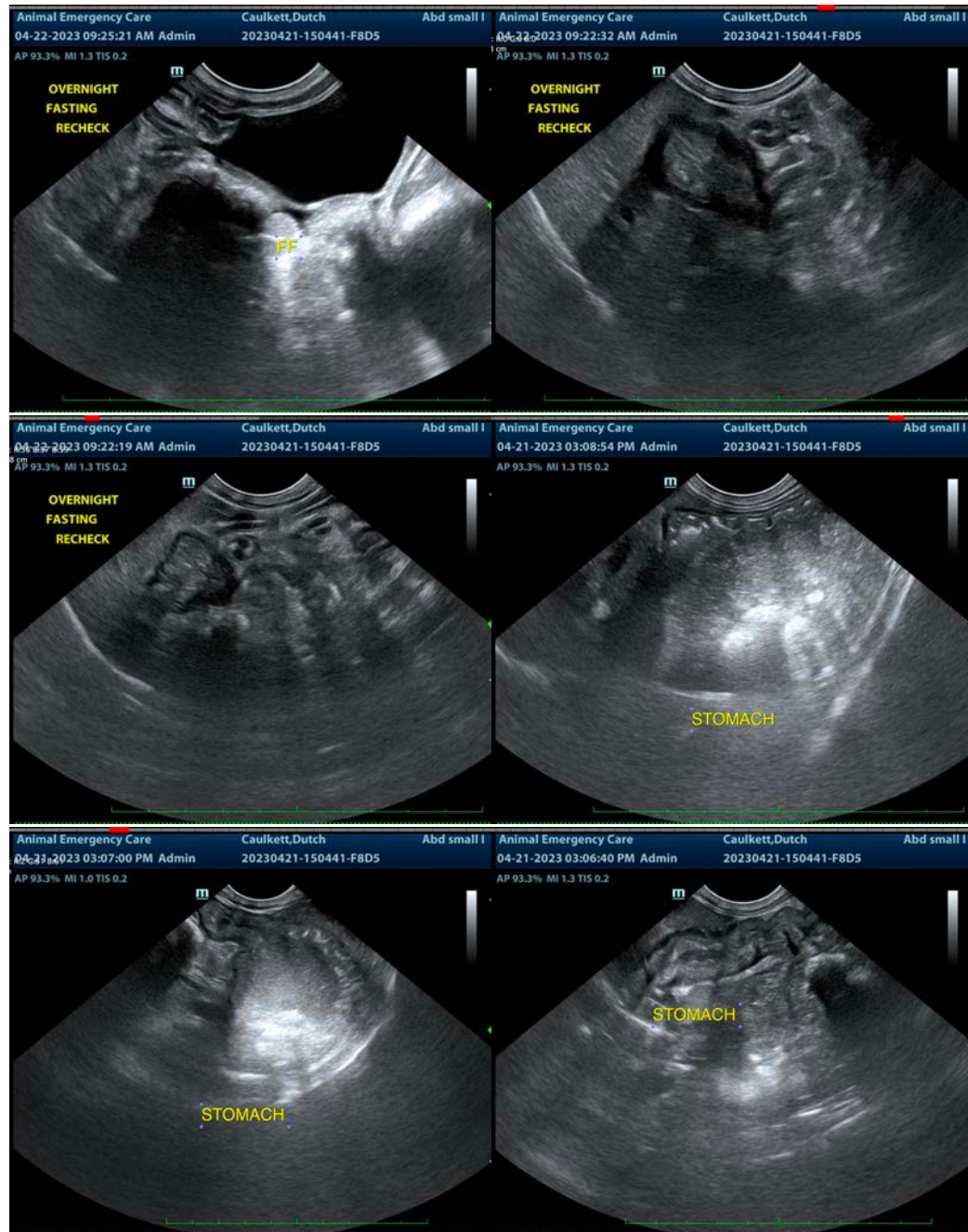
46877

**DATE**

4/23/23

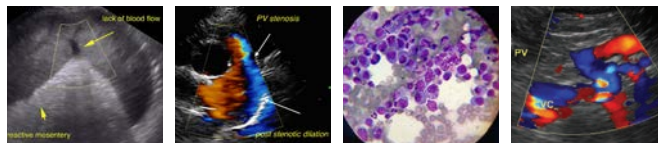
**INTERPRETATION OF THE FINDINGS & FURTHER RECOMMENDATIONS**

There is no visible evidence of foreign material and/or an obstructive pattern. Therefore, continued supportive/symptomatic medical management of acute gastroenteritis/dietary indiscretion, etc. is recommended. If clinical signs re-develop, however, recheck imaging should be considered at that time.



The information and recommendations provided are based on the images presented by the referring veterinarian/sonographer. No evaluation can be communicated regarding pathology that was not visible in the image/video clips provided.

Thank you for this referral. If the clinical or image interpretation does not parallel your findings or if I



**PATIENT**

can be of any further assistance please contact me.

Dutch Caulkett

**Beth Johnson, DVM, DACVIM**  
Beth.Johnson@sonopath.com

**SPECIES**

Canine

**BREED**

Labrador Retriever

**SEX**

Male

**AGE**

10 Weeks

**WEIGHT**

5.1 kg

**INTERPRETED BY**

Beth Johnson, DVM  
DACVIM

**IMAGING  
PERFORMED BY**

Dr. Callihan

**HOSPITAL NAME**

Animal Emergency  
Care

**REFERRING VET**

Dr. Loeffler

**INVOICE**

46877

**DATE**

4/23/23