



**PATIENT**

Stella Losacco

**SPECIES**

Canine

**BREED**

Chi x Terrier

**SEX**

Spayed Female

**AGE**

13 Years

**WEIGHT**

1.9 kg

**INTERPRETED BY**

Beth Johnson, DVM  
 DACVIM

**IMAGING PERFORMED BY**

Crystal Hill

**HOSPITAL NAME**

East Plains Animal  
 Hospital

**REFERRING VET**

Dr. Hindle

**INVOICE**

74683

**DATE**

4/22/26

**PRESENTING CLINICAL SIGNS**

Chronic weight loss over the last few months, picky eater, hair loss noted. No polyuria or polydipsia. More frequent urine and BM accidents in the house lately. PE - some alopecia on neck, chest, abdomen, muscle loss along dorsum, poor skin and coat health. Patient developed marked subcutaneous/skin bruising after venipuncture last week which extended from neck all the way down the chest. No meds.

Abnormal PE/Chem/CBC/UA Results: Please see attached lab results - marked hepatic enzymopathy, low TT4, mild hypocalcemia.

**ULTRASONOGRAPHIC EXAMINATION OF THE ABDOMEN**

**Urinary System**

The urinary bladder is not fully distended, resulting in a subjectively diffusely mildly thick, echogenic, irregular appearing wall. Visible contents are anechoic. While full assessment of the wall is difficult without further distention, near the end of the study after the urinary bladder is slightly more distended, there does appear to be a slightly thicker focal area along the mid dorsal wall measuring 0.30 cm x 0.40 cm in size. No mineral is observed.

Kidneys are bilaterally small, irregular and diffusely echogenic with decreased corticomedullary distinction and poor visualization of internal architecture. There is no pyelectasia noted and no mineral is observed. Left kidney is small-normal at 3.12 cm. Right kidney is small at 2.9 cm.

**Adrenal Glands**

The right adrenal gland is enlarged primarily at the cranial pole, which measures 1.1 cm x 0.90 cm in size with a normal size caudal pole measuring 0.35 cm in size. Normal shape and contour are maintained without evidence of capsular invasion. Corticomedullary structure is unremarkable. Visible surrounding vasculature appears normal.

The left adrenal gland is normal in size (0.38 cm at cranial pole and 0.26 cm at caudal pole), shape and overall architecture, echogenicity and echotexture. Visible surrounding vasculature appears normal.

**Spleen**

Spleen is subjectively normal in size with a normal smooth capsular contour. Parenchyma is appropriately finely textured and homogenous with normal echogenicity relative to surrounding tissue (hyperechoic to liver). Multifocal well-demarcated hyperechoic homogenous nodules are noted. Splenic vasculature appears normal.

**Liver**

Liver is subjectively enlarged with mildly irregular margins. Parenchyma is mildly heterogenous characterized by multiple poorly defined hypoechoic nodules within otherwise hyperechoic liver parenchyma. Visible vasculature and biliary tree appear normal without distension or congestion

Gallbladder is moderately distended with anechoic bile as well as suspended and gravity dependent echogenic debris. Specifically there is an approximately 0.40 cm x 0.60 cm non-shadowing, non-visibly obstructive echogenic density that could represent a non-shadowing cholecystolith versus mucus or debris. The wall is smooth without visible thickening. There is no evidence of cystic or CBD dilation. There is no evidence of effusion or inflammation.



**PATIENT**

Stella Losacco

**SPECIES**

Canine

**BREED**

Chi x Terrier

**SEX**

Spayed Female

**AGE**

13 Years

**WEIGHT**

1.9 kg

**INTERPRETED BY**

Beth Johnson, DVM  
DACVIM

**IMAGING PERFORMED BY**

Crystal Hill

**HOSPITAL NAME**

East Plains Animal  
Hospital

**REFERRING VET**

Dr. Hindle

**INVOICE**

74683

**DATE**

4/22/26

***Gastrointestinal***

The visible stomach wall is normal in thickness and layering. The lumen of the stomach is empty with no evidence of obstruction, foreign material or infiltrative disease. Pyloric outflow tract appears patent.

The visible small intestines are normal in wall thickness and layering. Hyperechoic mucosal fogging or speckling is noted. Small intestinal motility appears adequate (1-3 contractions per min). The lumen of the small intestine is empty with no evidence of obstruction or foreign material.

The visible colon is normal in wall thickness (< 0.2 cm) and layering. Contents are consistent with normal formed feces and gas.

***Pancreas***

The pancreas that is observed appears appropriately isoechoic to surrounding omental fat. Visible capsule is smooth and normal in contour. Visible pancreatic parenchyma is homogenous and unremarkable. There is no visible pancreatic duct dilation. There is no evidence of active peripancreatic inflammation.

***Free Abdomen***

There is no visible free peritoneal effusion noted in these images.

There is no apparent pathologic lymphadenopathy noted in these images.

There appears to be a very subjective ill-defined non-discrete hyperechoic appearance to the mesentery and omentum diffusely.

**PRIMARY FINDINGS**

- Subtle/mild mucosal speckling – Mucosal speckling is often present with inflammatory bowel disease (IBD). It is not specific for type or severity of disease. Mild speckling change can occur as a normal patient variant in the post-prandial state. \*This finding combined with the very subtle diffuse hyperechoic mesentery and omentum could suggest some mild or emerging diffuse bowel disease, although concurrent chronic low-grade smoldering pancreatitis or other cause of bright omentum and mesenteric fat can't be ruled out.
- Mildly heterogenous liver – These changes are most consistent with benign processes such as nodular hyperplasia, steroid (vacuolar) hepatopathy, extramedullary hematopoiesis or possibly chronic inflammatory disease and less commonly infiltrative round cell or metastatic neoplasia.
- Moderate gallbladder debris - Cholecystic debris is of unknown clinical significance. It can be seen with biliary stasis from fasting or illness. Cholecystic debris is not necessarily related to hepatobiliary disease. Echogenic bile is most commonly an incidental finding in dogs and should be interpreted in combination with clinical signs such as nausea, inappetence, cranial abdominal discomfort and/or laboratory changes such as increased ALP and/or increased Tbili. \*A non-visibly obstructive, non-shadowing cholelith can't be ruled out.
- Right adrenomegaly with normal size left adrenal gland – This finding can be a normal or incidental patient variant, especially given the lack of a contralateral small/flat gland. Other differentials to consider include adenoma (vs adenocarcinoma), pheochromocytoma and/or adrenal hyperplasia secondary to pituitary dependent hyperadrenocorticism. Interpret in



**PATIENT**

combination with clinical signs of hyperadrenocorticism or other adrenal disease.

Stella Losacco

- Mild bilateral chronic kidney disease changes.

**SPECIES**

Canine

- Mildly focally thick urinary bladder wall – This could be the result of a non-fully distended urinary bladder and warrants further evaluation if possible when fully distended, although a focal infiltrative process including both benign and neoplastic changes are possible.

**BREED**

Chi x Terrier

- Hyperechoic splenic nodules – most consistent with benign myelolipomas. Other differentials such as fibrosis or calcification caused by old hematomas or infarcts, chronic inflammation, granulomatous disease or metastatic disease cannot be ruled out, but are considered less likely.

**SEX**

Spayed Female

**SECONDARY FINDINGS**

**INTERPRETATION OF THE FINDINGS & FURTHER RECOMMENDATIONS**

**AGE**

Given patient’s reported history of bruising, full assessment of coagulation status is recommended if not recently evaluated.

13 Years

A blood pressure is recommended.

**WEIGHT**

1.9 kg

Given the right adrenomegaly, emerging adrenal disease/hyperadrenocorticism could be contributing to patient’s reported liver enzyme changes, even some of the skin changes, etc. However, hyperadrenocorticism does not typically result in decreased appetite and/or weight loss, except in the occasional/rare event of a pituitary macroadenoma. Therefore, given the other changes, concurrent or further workup of the weight loss and decreased appetite is recommended as a priority.

**INTERPRETED BY**

Beth Johnson, DVM  
 DACVIM

A routine fecal/giardia exam is recommended if not recently evaluated.

**IMAGING PERFORMED BY**

Crystal Hill

A gastrointestinal malabsorption panel (including cobalamin, folate, TLI and PLI) to Texas A&M GI Laboratory is recommended for further evaluation of GI and pancreatic function.

Additionally, further investigation of a concurrent hepatopathy could be considered, beginning with bile acids if patient’s total bilirubin is not increased.

**HOSPITAL NAME**

East Plains Animal  
 Hospital

This is a complex history with a variety of abnormalities that don’t easily fit into one overlying disease or recommendation. Therefore, a full internal medicine consult and/or referral could also be considered.

**REFERRING VET**

Dr. Hindle

For an additional charge an internal medicine consult can be utilized through [Sonopath.com](http://sonopath.com). You can select the internal medicine drop down at <http://spa.sonopath.com/>.

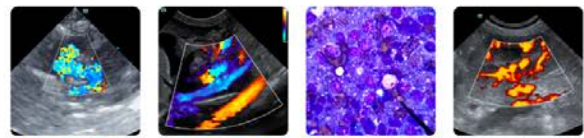
**INVOICE**

74683

One of the world’s top internists & SonoPath associate Dr. Remo Lobetti BVSc, MMedVet, PhD, DECVIM can evaluate your case through SonoPath. <https://sonopath.com/resources/sonopath-services/internal-medicine-teleconsultation-services>

**DATE**

4/22/26



**PATIENT**

Stella Losacco

**SPECIES**

Canine

**BREED**

Chi x Terrier

**SEX**

Spayed Female

**AGE**

13 Years

**WEIGHT**

1.9 kg

**INTERPRETED BY**

Beth Johnson, DVM  
 DACVIM

**IMAGING PERFORMED BY**

Crystal Hill

**HOSPITAL NAME**

East Plains Animal  
 Hospital

**REFERRING VET**

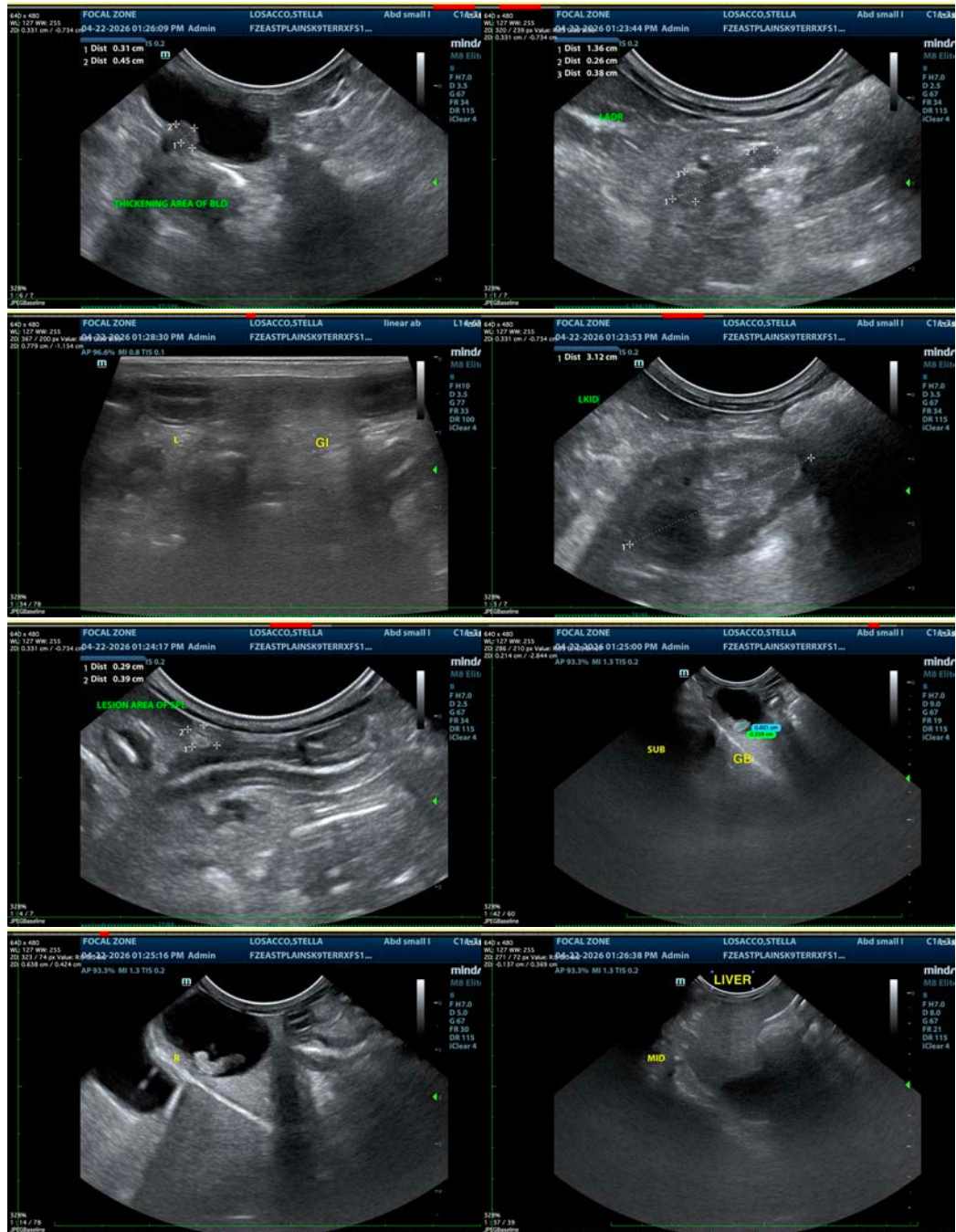
Dr. Hindle

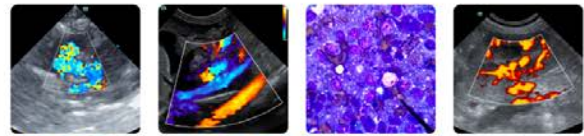
**INVOICE**

74683

**DATE**

4/22/26





**PATIENT**

Stella Losacco

**SPECIES**

Canine

**BREED**

Chi x Terrier

**SEX**

Spayed Female

**AGE**

13 Years

**WEIGHT**

1.9 kg

**INTERPRETED BY**

Beth Johnson, DVM  
 DACVIM

**IMAGING PERFORMED BY**

Crystal Hill

**HOSPITAL NAME**

East Plains Animal  
 Hospital

**REFERRING VET**

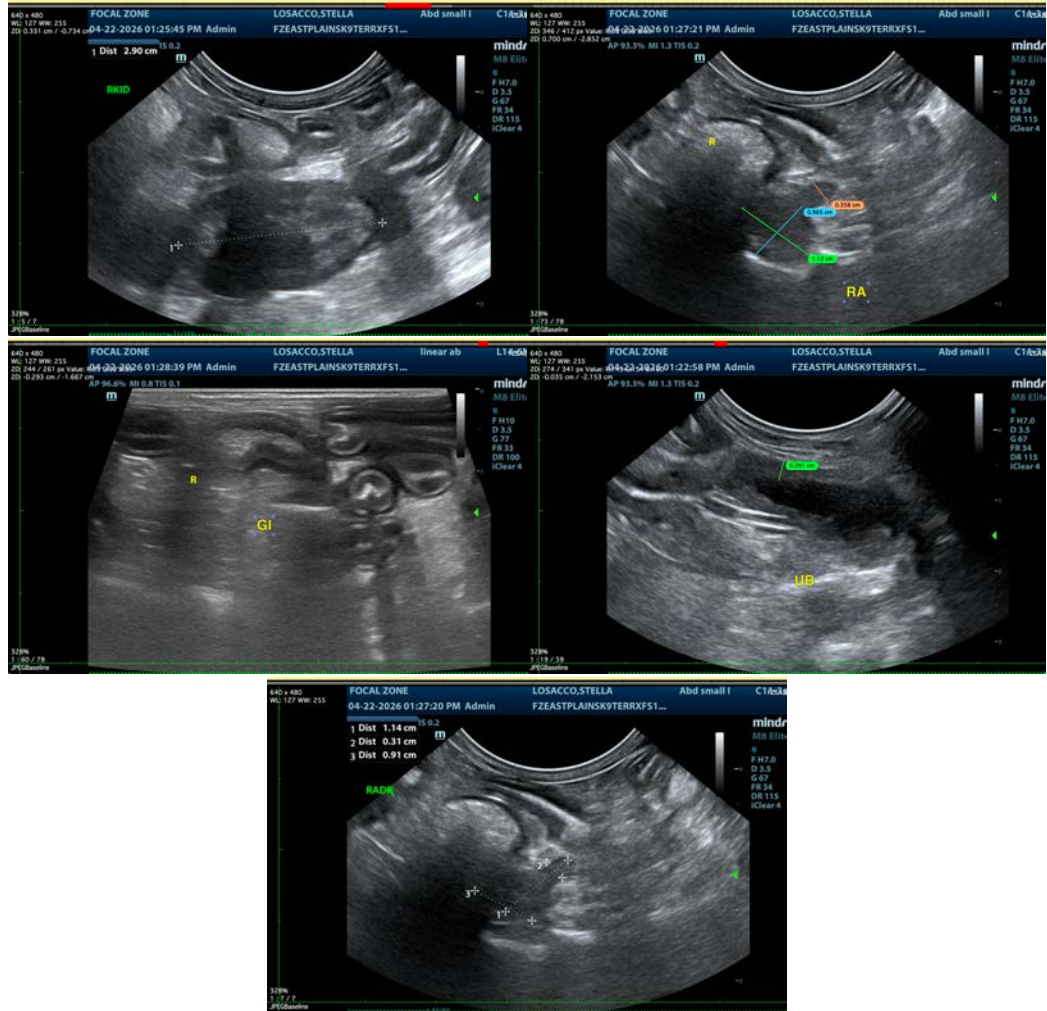
Dr. Hindle

**INVOICE**

74683

**DATE**

4/22/26



The information and recommendations provided are based on the images presented by the referring veterinarian/sonographer. No evaluation can be communicated regarding pathology that was not visible in the image/video clips provided.

Thank you for this referral. If the clinical or image interpretation does not parallel your findings or if I can be of any further assistance please contact me.

**Beth Johnson, DVM, DACVIM**  
 info@sonopath.com