

## PATIENT

Sigyn Gutshall-  
Seidman

## SPECIES

Canine

## BREED

Bernadoodle

## SEX

Spayed Female

## AGE

5

## WEIGHT

75

## INTERPRETED BY

Beth Johnson, DVM  
DACVIM

## IMAGING PERFORMED BY

Jenn

## HOSPITAL NAME

Rockaway Animal  
Hospital

## REFERRING VET

Dr. Maniar

## INVOICE

15318

## DATE

04/22/26

## PRESENTING CLINICAL SIGNS

Anorexia, diarrhea for 4 days tried to eat but threw up

## ULTRASONOGRAPHIC EXAMINATION OF THE ABDOMEN

### *Urinary System*

Urinary bladder is adequately distended with anechoic contents. No masses, inflammatory changes, echogenic sediment or cystoliths are observed. The urinary bladder, trigone and visible pelvic urethra are normal in thickness with a smooth mucosal surface.

Left kidney is normal in size (5.83 cm), shape and echogenicity. It has smooth peripheral margination. There is a normal 1:3 cortex to medulla ratio with appropriate corticomedullary distinction. There is no evidence of pyelectasia, mineral or infarcts observed.

Right kidney is normal in size (6.01 cm), shape and echogenicity. It has smooth peripheral margination. There is a normal 1:3 cortex to medulla ratio with appropriate corticomedullary distinction. There is no evidence of pyelectasia, mineral or infarcts observed.

### *Adrenal Glands*

Left adrenal gland is normal in size (0.64 cm at cranial pole and 0.52 cm at caudal pole), shape and overall architecture, echogenicity and echotexture. Visible surrounding vasculature appears normal.

Right adrenal gland is normal in size (1.0 cm at cranial pole and 0.57 cm at caudal pole), shape and overall architecture, echogenicity and echotexture. Visible surrounding vasculature appears normal.

### *Spleen*

Spleen is subjectively normal in size with a normal smooth capsular contour. Parenchyma is appropriately finely textured and homogenous with normal echogenicity relative to surrounding tissue (hyperechoic to liver). No focal nodules or masses are observed. Splenic vasculature appears normal.

### *Liver*

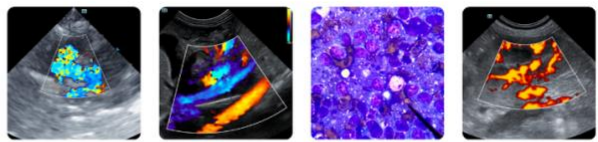
Liver is subjectively normal in size with normal smooth curvilinear peripheral contour. Parenchyma is appropriately hypoechoic to the spleen in echogenicity and appropriately mildly coarse and homogenous in echotexture. No focal lesions are observed. Visible vasculature and biliary tree appear normal without distension or congestion.

Gallbladder is non-distended in size. The wall is smooth without visible thickening. Luminal contents are primarily anechoic. There is no evidence of cystic or common bile duct dilation.

### *Gastrointestinal*

The visible stomach wall is normal in thickness and layering. The lumen of the stomach is empty with no evidence of obstruction, foreign material or infiltrative disease. Pyloric outflow tract appears patent.

The part of the small bowel that are visible in these images demonstrates normal wall thickness and layering. Small intestinal motility appears adequate (1-3 contractions per min). The lumen of the small intestine is empty with no evidence of obstruction, foreign material or infiltrative disease.



**PATIENT**

Sigyn Gutshall-Seidman

**SPECIES**

Canine

**BREED**

Bernadoodle

**SEX**

Spayed Female

**AGE**

5

**WEIGHT**

75

**INTERPRETED BY**

Beth Johnson, DVM  
DACVIM

**IMAGING PERFORMED BY**

Jenn

**HOSPITAL NAME**

Rockaway Animal Hospital

**REFERRING VET**

Dr. Maniar

**INVOICE**

15318

**DATE**

04/22/26

The visible colon is normal in wall thickness (< 0.2 cm) and layering. Contents are consistent with normal formed feces and gas.

**Pancreas**

The pancreas that is observed appears appropriately isoechoic to surrounding omental fat. Visible capsule is smooth and normal in contour. Visible pancreatic parenchyma is homogenous and unremarkable. There is no visible pancreatic duct dilation. There is no evidence of active peripancreatic inflammation.

**Free Abdomen**

There is no visible free peritoneal effusion noted in these images.

There is no apparent pathologic lymphadenopathy noted in these images.

**ULTRASONOGRAPHIC FINDINGS**

- This is a largely unremarkable/normal structural abdomen without a definitive ultrasonographically visible intraabdominal explanation for patient's reported gastrointestinal signs present in these images at this time.

**INTERPRETATION OF THE FINDINGS & FURTHER RECOMMENDATIONS**

If not recently evaluated, a general metabolic health screen (CBC, chemistry panel with electrolytes and urinalysis) is recommended.

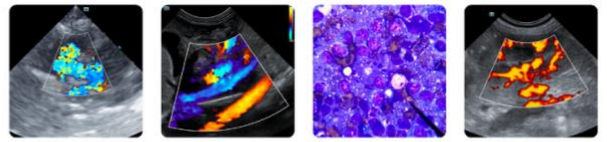
A routine fecal/Giardia exam is recommended if not recently evaluated.

A baseline cortisol is recommended. If baseline cortisol is less than 2, a full ACTH stimulation test is recommended to rule out hypoadrenocorticism.

A gastrointestinal malabsorption panel (including cobalamin, folate, TLI and PLI) to Texas A&M GI Laboratory is recommended for further evaluation of GI and pancreatic function.

A fecal enteropathogen PCR panel to Texas A&M GI Laboratory could be considered for further evaluation of possible infectious disease. Contact lab for recommendations on how long to discontinue antibiotics (if indicated) prior to obtaining a stool sample for submission.

- In the meantime, supportive/symptomatic medical management of clinical signs is recommended, including anti-emetics, gastroprotectants (+/- sucralfate, especially with any history of hematemesis), an appetite stimulant and fluid therapy if indicated, etc.
- Additionally, empirical deworming with a 5-day course of Panacur is recommended.
- A full course of empirical Helicobacter triple therapy could be considered.
- A probiotic, such a visbiome or proviable, may be helpful.
- Finally, if tolerated, a transition in diet could be considered, based on trial-and-error response with some options to consider including a gastrointestinal biome diet vs a hydrolyzed protein diet (sometimes several trials with different brands are necessary) vs an easy to digest, bland or low-fat diet vs other.



#### PATIENT

Signyn Gutshall-Seidman

#### SPECIES

Canine

#### BREED

Bernadoodle

#### SEX

Spayed Female

#### AGE

5

#### WEIGHT

75

#### INTERPRETED BY

Beth Johnson, DVM  
DACVIM

#### IMAGING PERFORMED BY

Jenn

#### HOSPITAL NAME

Rockaway Animal  
Hospital

#### REFERRING VET

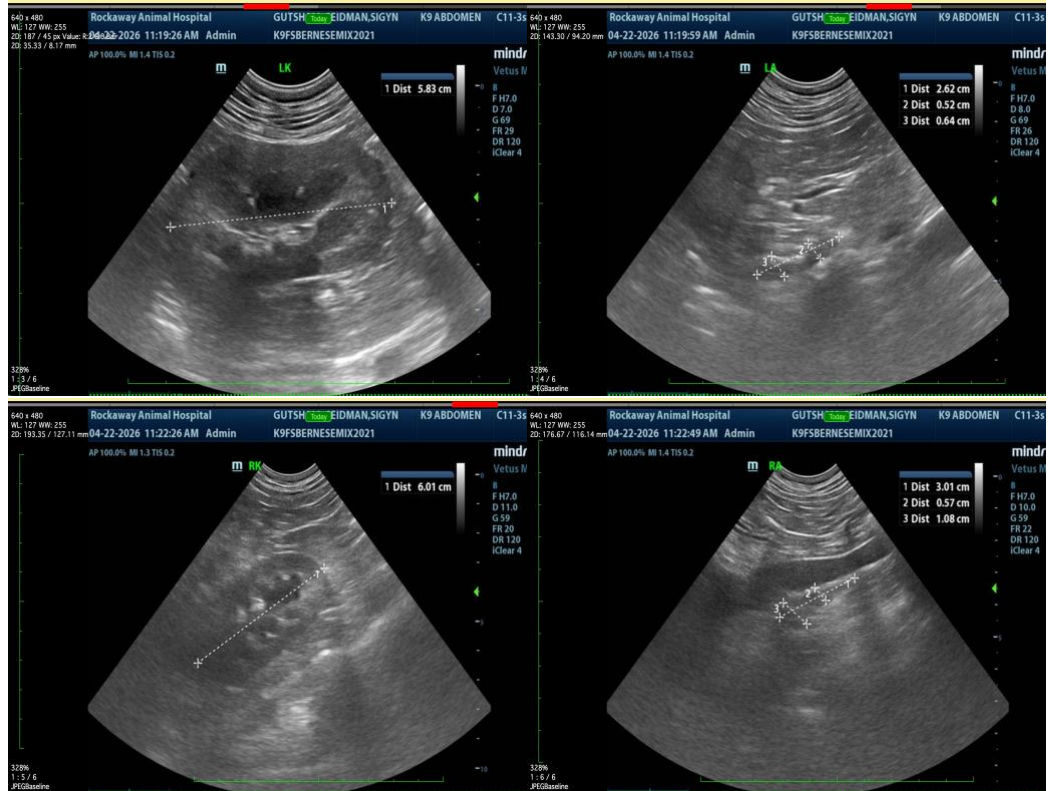
Dr. Maniar

#### INVOICE

15318

#### DATE

04/22/26



The information and recommendations provided are based on the images presented by the referring veterinarian/sonographer. No evaluation can be communicated regarding pathology that was not visible in the image/video clips provided.

Thank you for this referral. If the clinical or image interpretation does not parallel your findings or if I can be of any further assistance, please contact me.

**Beth Johnson, DVM DACVIM**

[info@sonopath.com](mailto:info@sonopath.com)