



PATIENT

Mekka Popovich

SPECIES

Canine

BREED

Siberian Husky

SEX

Spayed Female

AGE

13 Years

WEIGHT

74 lbs

INTERPRETED BY

Beth Johnson, DVM
DACVIM

IMAGING PERFORMED BY

Dr. Wasserman

HOSPITAL NAME

Highlands Animal
Hospital

REFERRING VET

Dr. Frankenberger

INVOICE

74692

DATE

4/22/26

PRESENTING CLINICAL SIGNS

Ultrasound to due to elevated ALP. Purpose of sonogram, evaluate progression of hepatic mass and for metastatic criteria within the abdomen. History of orthopedic pain/osteoarthritis reported by referring veterinarian. Doing well at home per owner. Eating/drinking normal. Large mass on left thorax reportedly a soft tissue sarcoma with plans for surgical resection. Previous sonogram revealed primary hepatic mass measured to be 3.5cm x 2.28cm in the left lobe- See Attached previous report. Sedated with butorphanol IV for sonogram. Abdomen tense and patient panting for sonogram.

Abnormal PE/Chem/CBC/UA Results: Panel elevated ALP 731 (5-160), TP 7.8 (5.5-7.8) and Globulin 4.7 (2.5-4.0). UA supportive of uti. Doing well at home per owner.

ULTRASONOGRAPHIC EXAMINATION OF THE ABDOMEN

Urinary System

The urinary bladder is adequately distended with anechoic contents. No masses, inflammatory changes, echogenic sediment or cystoliths are observed. The urinary bladder, trigone and visible pelvic urethra are normal in thickness with a smooth mucosal surface.

Kidneys are overall normal in size and shape with smooth peripheral margination. A normal 1:3 cortex to medulla ratio is maintained. The medulla and cortices are uniform in texture with some mild increased cortical echogenicity and mild loss of corticomedullary distinction, expected in this age patient. There is no evidence of mineral or infarcts observed. Left kidney measured 6.68 cm. Right kidney measures 6.83 cm. Small cortical cysts are present bilaterally. Mild pyelectasia is noted bilaterally.

Adrenal Glands

The right adrenal gland is normal in size (0.62 cm at cranial pole and 0.83 cm at caudal pole), shape and overall architecture, echogenicity and echotexture. Visible surrounding vasculature appears normal.

The left adrenal gland is normal in size (0.51 cm at cranial pole and 0.67 cm at caudal pole), shape and overall architecture, echogenicity and echotexture. Visible surrounding vasculature appears normal.

Spleen

The spleen is subjectively normal in size with a normal smooth capsular contour. Parenchyma is appropriately finely textured and homogenous with normal echogenicity relative to surrounding tissue (hyperechoic to liver). No focal nodules or masses are observed. Splenic vasculature appears normal.

Liver

The liver is subjectively normal in size with normal smooth curvilinear peripheral contour. Parenchyma is appropriately hypoechoic to the spleen in echogenicity and appropriately mildly coarse and homogenous in echotexture. In the left mid to cranial liver adjacent to the gallbladder is a discrete homogeneous, hypoechoic mass that measures approximately 4.8 cm x 6.3 cm. In alternative views and images there is a similar appearing area that measures approximately 3.3 cm x 4.0 cm that appears made up of several small, hypoechoic nodules that measure between 1.0-1.5 cm each. It is difficult to definitively determine whether this is one mass or two separate lesions adjacent to each other. Visible vasculature and biliary tree appear normal without distension or congestion.



PATIENT

Mekka Popovich

SPECIES

Canine

BREED

Siberian Husky

SEX

Spayed Female

AGE

13 Years

WEIGHT

74 lbs

INTERPRETED BY

Beth Johnson, DVM
DACVIM

IMAGING PERFORMED BY

Dr. Wasserman

HOSPITAL NAME

Highlands Animal
Hospital

REFERRING VET

Dr. Frankenberger

INVOICE

74692

DATE

4/22/26

Gallbladder is moderately distended with anechoic bile as well as suspended and gravity dependent echogenic debris. The wall of the gallbladder appears as a thin hyperechoic/calcified rim casting a distinct distal acoustic shadow. There is no evidence of cystic or CBD dilation. There is no evidence of effusion or inflammation.

Gastrointestinal

The visible stomach wall is normal in thickness and layering. The lumen of the stomach is mildly distended with a small to moderate amount of echogenic non-shadowing luminal contents and gas consistent with normal ingesta. There is no evidence of obstruction, foreign material or infiltrative disease. Pyloric outflow tract appears patent.

The visible small intestines are normal in wall thickness and layering. Small intestinal motility appears adequate (1-3 contractions per min). The lumen is mildly distended with echogenic non-shadowing luminal contents and gas consistent with normal ingesta/chyme. There is no evidence of obstruction, foreign material or infiltrative disease.

The visible colon is normal in wall thickness (< 0.2 cm) and layering. Contents are consistent with normal formed feces and gas.

Pancreas

The pancreas that is observed appears appropriately isoechoic to surrounding omental fat. Visible capsule is smooth and normal in contour. Visible pancreatic parenchyma is homogenous and unremarkable. There is no visible pancreatic duct dilation. There is no evidence of active peripancreatic inflammation.

Free Abdomen

There is no visible free peritoneal effusion noted in these images.

There is no apparent pathologic lymphadenopathy noted in these images.

PRIMARY FINDINGS

- At least one, if not two liver masses, which could represent infiltrative neoplasia including primary hepatocellular carcinoma or neoplasia, or metastatic neoplasia, given patient's other reported history. A benign process, however, including nodular hyperplasia, hepatoma, etc. can't be ruled out without tissue sampling. The mass is subjectively progressive in size from the previously reported measurements.
- Mild gallbladder debris - Cholecystic debris is of unknown clinical significance. It can be seen with biliary stasis from fasting or illness. Cholecystic debris is not necessarily related to hepatobiliary disease. Echogenic bile is most commonly an incidental finding in dogs and should be interpreted in combination with clinical signs such as nausea, inappetence, cranial abdominal discomfort and/or laboratory changes such as increased ALP and/or increased Tbili.
- Porcelain gallbladder - Porcelain (calcified) gallbladder is an uncommon finding in companion animals and has been observed as both an incidental finding and associated with biliary neoplasia. In humans, porcelain gallbladder can be a manifestation of chronic gallbladder disease, chronic cholecystitis, intramural hemorrhage with subsequent calcification, imbalances in calcium metabolism, and even giardiasis. This finding should be interpreted in



PATIENT

Mekka Popovich

SPECIES

Canine

BREED

Siberian Husky

SEX

Spayed Female

AGE

13 Years

WEIGHT

74 lbs

INTERPRETED BY

Beth Johnson, DVM
DACVIM

IMAGING PERFORMED BY

Dr. Wasserman

HOSPITAL NAME

Highlands Animal
Hospital

REFERRING VET

Dr. Frankenberger

INVOICE

74692

DATE

4/22/26

combination with any clinical signs and/or laboratory changes suggestive of biliary disease and/or calcium dysregulation, etc.

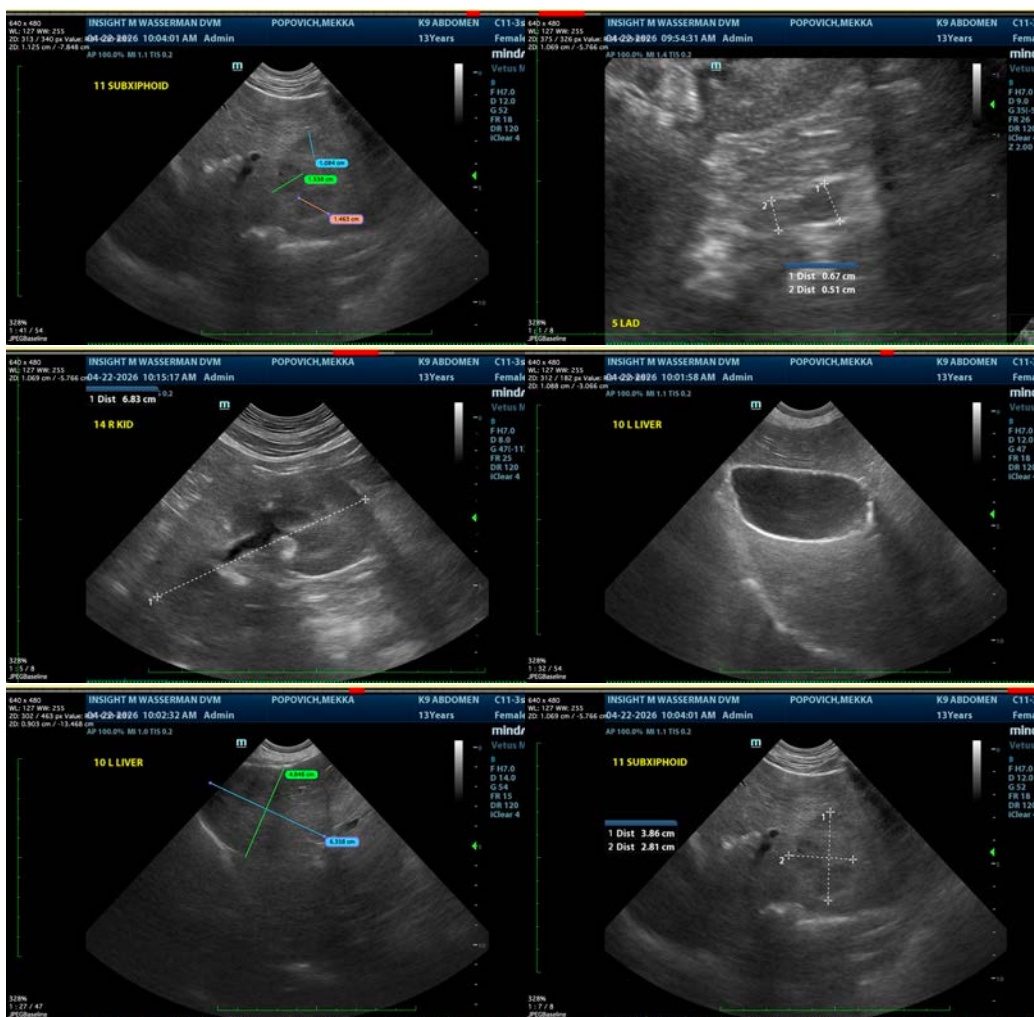
SECONDARY FINDINGS

- Mild to moderate age related kidney changes with bilateral cortical cysts and mild bilateral pyelectasia.

INTERPRETATION OF THE FINDINGS & FURTHER RECOMMENDATIONS

Three view thoracic radiographs are recommended for further assessment of cardio-pulmonary status as well as to further evaluate for any evidence of metastatic disease, if not recently evaluated.

Fine needle aspirates of the liver mass(es) are recommended if patient's coagulation status is appropriate. Ultimately, if surgical excisional biopsy or liver lobectomy is elected, a pre-surgical planning abdominal CT scan could be considered, especially given the difficulty determining whether there is one or multiple lesions.





PATIENT

Mekka Popovich

SPECIES

Canine

BREED

Siberian Husky

SEX

Spayed Female

AGE

13 Years

WEIGHT

74 lbs

INTERPRETED BY

Beth Johnson, DVM
DACVIM

IMAGING PERFORMED BY

Dr. Wasserman

HOSPITAL NAME

Highlands Animal
Hospital

REFERRING VET

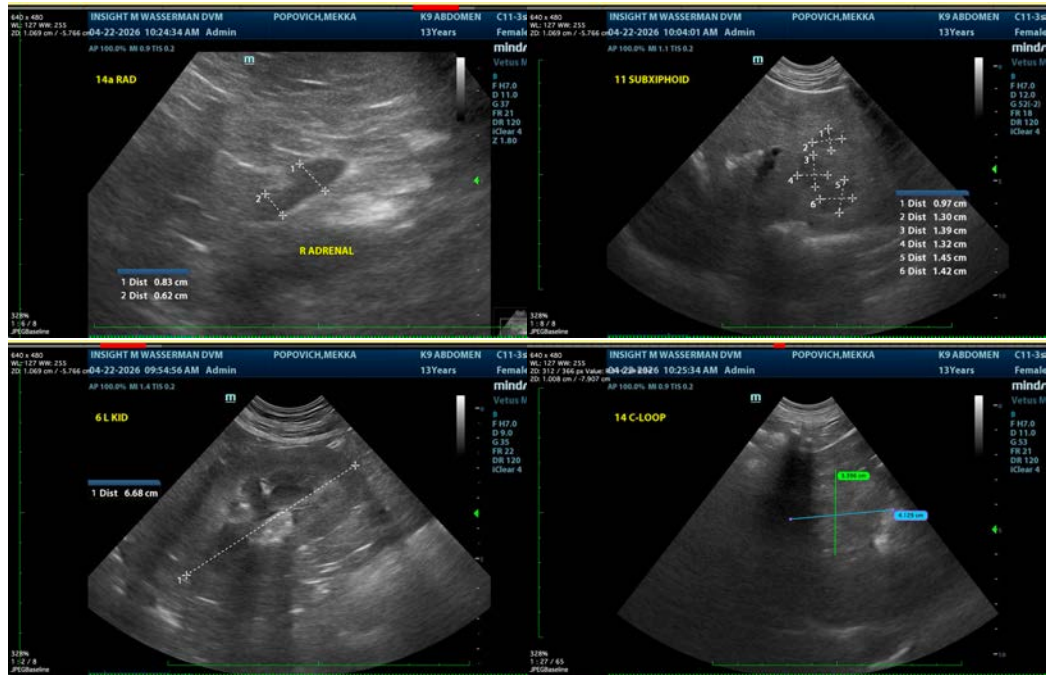
Dr. Frankenberger

INVOICE

74692

DATE

4/22/26



The information and recommendations provided are based on the images presented by the referring veterinarian/sonographer. No evaluation can be communicated regarding pathology that was not visible in the image/video clips provided.

Thank you for this referral. If the clinical or image interpretation does not parallel your findings or if I can be of any further assistance please contact me.

Beth Johnson, DVM, DACVIM
info@sonopath.com