

**PATIENT**

Bindi Bray

SPECIES

Canine

BREED

Australian Shepherd

SEX

Spayed Female

AGE

9.5 Years

WEIGHT

32 lbs

INTERPRETED BYBeth Johnson, DVM
DACVIM**IMAGING
PERFORMED BY**

Jack Reese

HOSPITAL NAMEWillw Run Veterinary
Clinic**REFERRING VET**

Anna leppien, DVM

INVOICE

74702

DATE

4/22/26

PRESENTING CLINICAL SIGNS

Several month history of decreased appetite and sporadic vomiting (1-2x monthly). O reports that P eating, but does not finished offered food, which has not been typical in past. 3 lb weight loss over last year.

Abnormal PE/Chem/CBC/UA Results: Fecal screen negative CBC WNL Full in-house chemistry WNL (no TT4)

ULTRASONOGRAPHIC EXAMINATION OF THE ABDOMEN**Urinary System**

The urinary bladder is adequately distended with anechoic contents. No masses, inflammatory changes, echogenic sediment or cystoliths are observed. The urinary bladder, trigone and visible pelvic urethra are normal in thickness with a smooth mucosal surface.

The right kidney is normal is size (5.32 cm), shape and echogenicity. It has smooth peripheral margination. There is a normal 1:3 cortex to medulla ratio with appropriate corticomedullary distinction. There is no evidence of pyelectasia or infarcts observed. Punctate non-obstructive mineral densities are noted.

The left kidney is normal is size (5.69 cm), shape and echogenicity. It has smooth peripheral margination. There is a normal 1:3 cortex to medulla ratio with appropriate corticomedullary distinction. There is no evidence of pyelectasia or infarcts observed. Punctate non-obstructive mineral densities are noted.

Adrenal Glands

The right adrenal gland is normal in size (1.0 cm at cranial pole and 0.49 cm at caudal pole), shape and overall architecture, echogenicity and echotexture. Visible surrounding vasculature appears normal.

The left adrenal gland is normal in size (0.50 cm at cranial pole and 0.60 cm at caudal pole), shape and overall architecture, echogenicity and echotexture. Visible surrounding vasculature appears normal.

Spleen

The spleen is subjectively normal in size with a normal smooth capsular contour. Parenchyma is appropriately finely textured and homogenous with normal echogenicity relative to surrounding tissue (hyperechoic to liver). No focal nodules or masses are observed. Splenic vasculature appears normal.

Liver

The liver is subjectively normal in size with normal smooth curvilinear peripheral contour. Parenchyma is appropriately hypoechoic to the spleen in echogenicity and appropriately mildly coarse and homogenous in echotexture. No focal lesions are observed. Visible vasculature and biliary tree appear normal without distension or congestion.

The gallbladder is non-distended in size. The wall is smooth without visible thickening. Luminal contents are primarily anechoic. There is no evidence of cystic or common bile duct dilation.

Gastrointestinal

The visible stomach wall is normal in thickness and layering. The lumen of the stomach is empty with no evidence of obstruction, foreign material or infiltrative disease. Pyloric outflow tract appears patent.



PATIENT

Bindi Bray

SPECIES

Canine

BREED

Australian Shepherd

SEX

Spayed Female

AGE

9.5 Years

WEIGHT

32 lbs

INTERPRETED BY

Beth Johnson, DVM
DACVIM

IMAGING PERFORMED BY

Jack Reese

HOSPITAL NAME

Willw Run Veterinary
Clinic

REFERRING VET

Anna leppien, DVM

INVOICE

74702

DATE

4/22/26

The visible small intestine demonstrates areas of mildly thick muscularis layer relative to mucosa (disruption of the normal 1:3 muscularis:mucosa ratio). Small intestinal submucosa is slightly irregular, thick and hyperechoic, without evident loss of layering appreciated. The lumen of the small intestine is empty with no evidence of obstruction or foreign material.

The visible colon is normal in wall thickness (< 0.2 cm) and layering. Contents are consistent with normal formed feces and gas.

Pancreas

The pancreas that is observed appears appropriately isoechoic to surrounding omental fat. Visible capsule is smooth and normal in contour. Visible pancreatic parenchyma is homogenous and unremarkable. There is no visible pancreatic duct dilation. There is no evidence of active peripancreatic inflammation.

Free Abdomen

There is no visible free peritoneal effusion noted in these images.

There is no apparent pathologic lymphadenopathy noted in these images.

PRIMARY FINDINGS

- Mild/emerging inflammatory bowel disease (IBD) pattern – Thick muscularis has been reported with infiltrative bowel disease including both benign inflammatory disease as well as infiltrative neoplasia such as lymphoma. No loss of layering or distinct characteristics of malignancy are present. Therefore, differentials cannot be further ranked without tissue sampling.

SECONDARY FINDINGS

- Punctate non-obstructive nephroliths bilaterally.

INTERPRETATION OF THE FINDINGS & FURTHER RECOMMENDATIONS

If not recently evaluated, to complete a full general metabolic health screen, a urinalysis and, if indicated based on urinalysis results, urine culture is recommended. If protein is present in an otherwise quiet sediment, protein quantification with a urine protein to creatinine ratio is recommended.

A baseline cortisol is recommended. If baseline cortisol is less than 2, a full ACTH stimulation test is recommended to rule out hypoadrenocorticism.

A gastrointestinal malabsorption panel (including cobalamin, folate, TLI and PLI) to Texas A&M GI Laboratory is recommended for further evaluation of GI and pancreatic function.

In the meantime, supportive/symptomatic medical management of clinical signs is recommended, including anti-emetics, gastroprotectants (+/- sucralfate, especially with any history of hematemesis), an appetite stimulant and fluid therapy if indicated, etc.

Additionally, empirical deworming with a 5-day course of Panacur is recommended as is a full course of empirical Helicobacter triple therapy.

Finally, if tolerated, a transition in diet could be considered, based on trial-and-error response with some options to consider including a gastrointestinal biome diet vs a hydrolyzed protein diet



PATIENT

Bindi Bray

SPECIES

Canine

BREED

Australian Shepherd

SEX

Spayed Female

AGE

9.5 Years

WEIGHT

32 lbs

INTERPRETED BY

Beth Johnson, DVM
DACVIM

IMAGING PERFORMED BY

Jack Reese

HOSPITAL NAME

Willw Run Veterinary
Clinic

REFERRING VET

Anna leppien, DVM

INVOICE

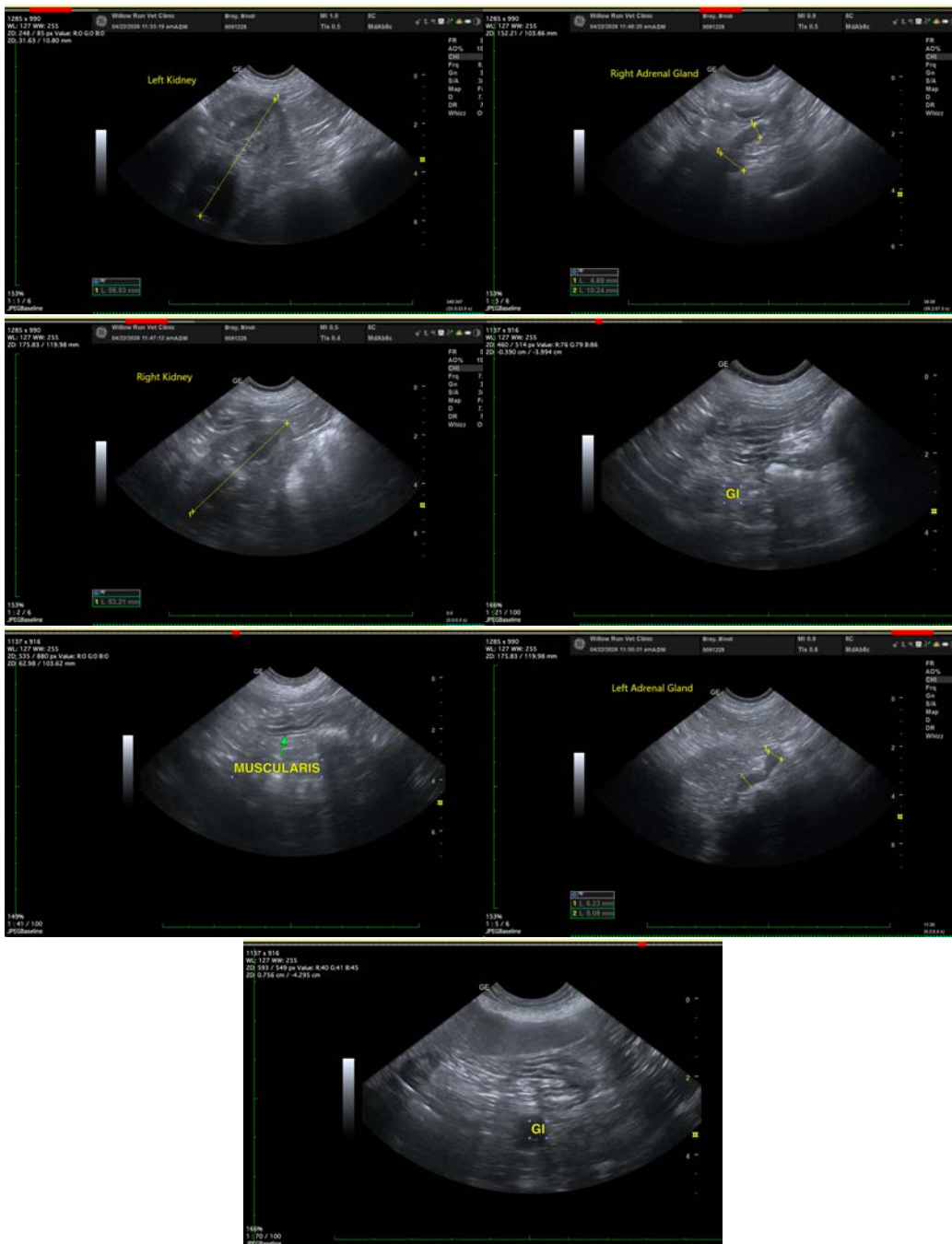
74702

DATE

4/22/26

(sometimes several trials with different brands are necessary) vs an easy to digest, bland or low-fat diet vs other.

If clinical signs persist and a diagnosis is not obtained, additionally further evaluation for possible pain (dental, orthopedic, other), upper respiratory disease or oropharyngeal disease, cardiac disease and/or neurologic disease vs other as possible causes for decreased appetite and/or unintentional weight loss is also recommended.





PATIENT

Bindi Bray

SPECIES

Canine

BREED

Australian Shepherd

SEX

Spayed Female

AGE

9.5 Years

WEIGHT

32 lbs

INTERPRETED BY

Beth Johnson, DVM
DACVIM

IMAGING PERFORMED BY

Jack Reese

HOSPITAL NAME

Willw Run Veterinary
Clinic

REFERRING VET

Anna leppien, DVM

INVOICE

74702

DATE

4/22/26

The information and recommendations provided are based on the images presented by the referring veterinarian/sonographer. No evaluation can be communicated regarding pathology that was not visible in the image/video clips provided.

Thank you for this referral. If the clinical or image interpretation does not parallel your findings or if I can be of any further assistance please contact me.

Beth Johnson, DVM, DACVIM
info@sonopath.com