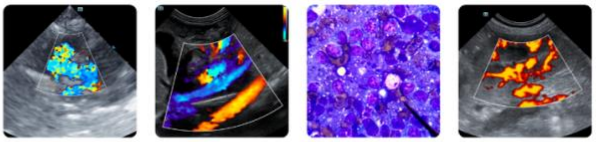

PATIENT
Athena Bain

SPECIES
Feline

BREED
DLH

SEX
Spayed Female

AGE
15

WEIGHT
8

INTERPRETED BY
Beth Johnson, DVM DACVIM

IMAGING PERFORMED BY
Jenn

HOSPITAL NAME
Rockaway Animal Hospital

REFERRING VET
Dr. Maniar

INVOICE
15323

DATE
04/22/26

PRESENTING CLINICAL SIGNS

V/D lethargy Had an echo 3/6/26

Abnormal PE/Chem/CBC/UA Results: ALT 311

ULTRASONOGRAPHIC EXAMINATION OF THE ABDOMEN

Urinary System

Urinary bladder is adequately distended with anechoic contents. No masses, inflammatory changes, echogenic sediment or cystoliths are observed. The urinary bladder, trigone and visible pelvic urethra are normal in thickness with a smooth mucosal surface.

Kidneys are bilaterally small in size, irregular and diffusely echogenic with decreased corticomedullary distinction and poor visualization of internal architecture. There is mild pyelectasia present bilaterally. The left kidney measured 3.49 cm in length. The right kidney measured 3.01 cm in length.

Adrenal Glands

The area of the left adrenal gland is examined without evident adrenal gland pathology.

Right adrenal gland is normal in size (0.49 cm at cranial pole and 0.35 cm at caudal pole), shape and overall architecture, echogenicity and echotexture. Visible surrounding vasculature appears normal.

Spleen

Spleen is subjectively normal in size with a normal smooth capsular contour. Parenchyma is appropriately finely textured and homogenous with normal echogenicity relative to surrounding tissue (hyperechoic to liver). No focal nodules or masses are observed. Splenic vasculature appears normal.

Liver

Liver is subjectively enlarged (swollen contour) without disruption of architecture. It has a normal homogenous echotexture. Parenchyma is diffusely hyperechoic characterized by less prominent than normal portal vein walls and increased echogenicity relative to the spleen and falciform fat. Visible vasculature and biliary tree appear normal without distension or congestion. Additionally, multifocal mixed largely hyperechoic and largely cystic nodules are noted throughout the parenchyma. All measuring approximately 1.5 cm x 2.0 cm in size.

Gallbladder is non-distended in size. The wall is smooth without visible thickening. Luminal contents are primarily anechoic. There is no evidence of cystic or common bile duct dilation.

Gastrointestinal

The visible stomach wall is normal in thickness and layering. The lumen of the stomach is empty with no evidence of obstruction, foreign material or infiltrative disease. Pyloric outflow tract appears patent.

The visible small intestine demonstrates areas of moderate to severely thick muscularis layer relative to mucosa (disruption of the normal 1:3 muscularis:mucosa ratio). Small intestinal submucosa is slightly irregular, thick and hyperechoic, without evident loss of layering appreciated. The lumen of the small intestine is empty with no evidence of obstruction or foreign material.

PATIENT
Athena Bain

SPECIES
Feline

BREED
DLH

SEX
Spayed Female

AGE
15

WEIGHT
8

INTERPRETED BY
Beth Johnson, DVM DACVIM

IMAGING PERFORMED BY
Jenn

HOSPITAL NAME
Rockaway Animal Hospital

REFERRING VET
Dr. Maniar

INVOICE
15323

DATE
04/22/26

The visible colon is normal in wall thickness (< 0.2 cm) and layering. Contents are consistent with normal formed feces and gas.

Pancreas

The pancreas that is observed appears appropriately isoechoic to surrounding omental fat. Visible capsule is smooth and normal in contour. Visible pancreatic parenchyma is homogenous and unremarkable. There is no visible pancreatic duct dilation. There is no evidence of active peripancreatic inflammation.

Free Abdomen

There is no visible free peritoneal effusion noted in these images.

There is no apparent pathologic lymphadenopathy noted in these images.

ULTRASONOGRAPHIC FINDINGS

- Moderate inflammatory bowel disease pattern- Thick muscularis has been reported with infiltrative bowel disease including both benign inflammatory disease as well as infiltrative neoplasia such as lymphoma. No loss of layering or distinct characteristics of malignancy are present. Therefore, differentials cannot be further ranked without tissue sampling.
- Diffusely hyperechoic hepatomegaly- This appearance is most consistent with benign hepatic lipidosis or endocrine/DM hepatopathy. Infiltrative disease such as amyloidosis or round cell neoplasia, such as mast cell tumor or less likely, lymphoma, is also possible. In a senior cat, this liver lesion is most consistent with a/multiple benign biliary cystadenoma(s). Malignancy cannot be ruled out but is considered less likely give lack of clinical signs and/or laboratory changes.
- Moderate bilateral chronic kidney disease changes with mild bilateral pyelectasia.

INTERPRETATION OF THE FINDINGS & FURTHER RECOMMENDATIONS

If not recently evaluated, a T4 +/- free T4 is recommended.

A gastrointestinal malabsorption panel (including cobalamin, folate, TLI and PLI) to Texas A&M GI Laboratory is recommended for further evaluation of GI and pancreatic function.

Three view thoracic radiographs are recommended for further assessment of cardio-pulmonary status as well as to further evaluate for any evidence of metastatic disease, if not recently evaluated.

Fine needle aspirates of the liver could be considered if patient's coagulation status is appropriate.

Pending results of above, ultimately, biopsies of the GI tract being sure to include ileum if possible may be necessary for a definitive diagnosis and therefore to further guide medical management if patient's clinical signs are determined not to be secondary to something other than infiltrative bowel disease.

SonoPath
FOSTERING THE ART OF VETERINARY MEDICINE™

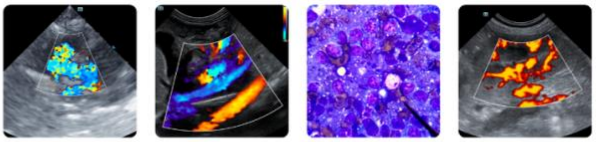

Clinical Sonography & Telecytology
Educational Teleconsultation Services™

SonoPath.com info@sonopath.com 1.800.838.4268

PATIENT

Athena Bain

SPECIES

Feline

BREED

DLH

SEX

Spayed Female

AGE

15

WEIGHT

8

INTERPRETED BY

Beth Johnson, DVM DACVIM

IMAGING PERFORMED BY

Jenn

HOSPITAL NAME

Rockaway Animal Hospital

REFERRING VET

Dr. Maniar

INVOICE

15323

DATE

04/22/26

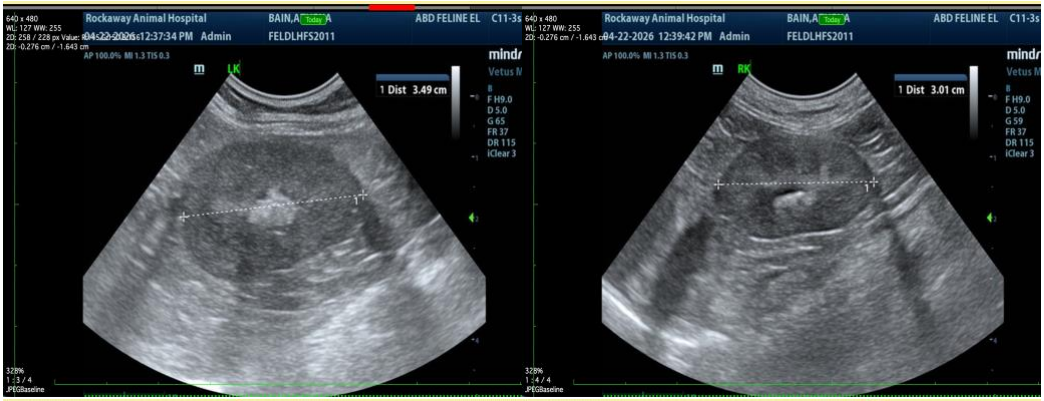

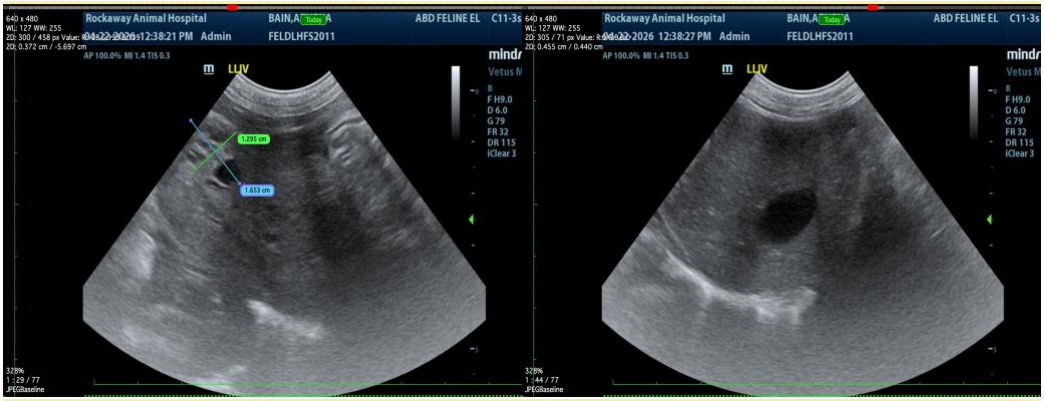

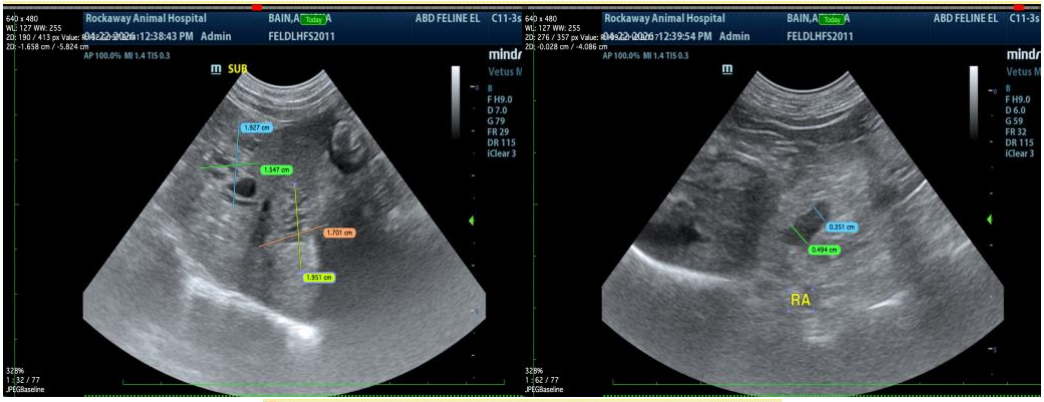

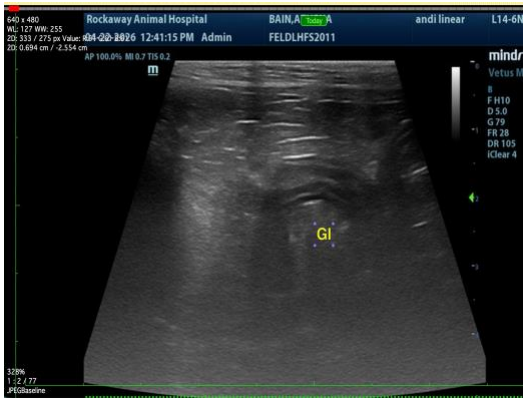

SonoPath
FOSTERING THE ART OF VETERINARY MEDICINE™

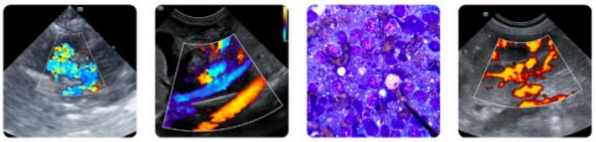

Clinical Sonography & Telecytology
Educational Teleconsultation Services™

SonoPath.com info@sonopath.com 1.800.838.4268

PATIENT

Athena Bain

SPECIES

Feline

BREED

DLH

SEX

Spayed Female

AGE

15

WEIGHT

8

INTERPRETED BY

Beth Johnson, DVM DACVIM

IMAGING PERFORMED BY

Jenn

HOSPITAL NAME

Rockaway Animal Hospital

REFERRING VET

Dr. Maniar

INVOICE

15323

DATE

04/22/26

The information and recommendations provided are based on the images presented by the referring veterinarian/sonographer. No evaluation can be communicated regarding pathology that was not visible in the image/video clips provided.

Thank you for this referral. If the clinical or image interpretation does not parallel your findings or if I can be of any further assistance, please contact me.

Beth Johnson, DVM DACVIM

info@sonopath.com